

ASSESSMENT OF EARLY AND LATE FEATURES OF DRY AGE-RELATED MACULAR DEGENERATION WITH SPECTRAL-DOMAIN OPTICAL COHERENCE TOMOGRAPHY AND FUNDUS AUTOFLUORESCENCE

Archana Singh¹, Mohini Agrawal², Harikrishnan Vannadil³, Sunandan Bhatta⁴

¹Department of Ophthalmology, INHS Asvini, Mumbai, India

²Department of Ophthalmology, Military Hospital, Jalandhar, India

³Department of Ophthalmology, Eyeris Eye Care Hospital, Hyderabad, India

⁴Department of Ophthalmology, Military Hospital, Agra, India

Abstract

Introduction: To assess early and late features of dry age-related macular degeneration (ARMD) using spectral-domain optical coherence tomography (SDOCT) and fundus autofluorescence (FAF).

Method: Observational cross-sectional study conducted from January-2022 to December-2022 in a tertiary eye care center, India. Patients >55 years and clinically diagnosed dry ARMD underwent SDOCT and FAF. OCT and FAF were assessed and correlated with best-corrected visual acuity (BCVA).

Results: 106 eyes of 60 cases were included. Mean age was 65.24±4.80 years. Mean BCVA was 0.4±0.24 LogMAR. Among clinically evident drusen, hard drusen (>63µm) was 88.6% (n=94 eyes), confluent soft-drusen 9% (n=10 eyes) and pigmentary changes at macula in 2 eyes only. In the OCT, 65% (n=69) eyes showed RPE irregularity, which was there in all the cases with soft drusen, whereas it varied in cases with hard drusen. In the FAF, hypo/hyper was observed in 81 eyes (76%). When correlated with BCVA, RPE irregularity was not seen in cases with BCVA>6/12. An abnormality in macular autofluorescence was evident in 62% (n= 31) in cases with vision >6/12; whereas in cases with vision<6/18, it was seen in 80% (n=49) cases. A strong correlation was found between the OCT findings and abnormal FAF (kappa=0.60), suggesting comparable results by both the modalities in cases of early and late dry ARMD.

Conclusion: OCT and FAF show good correlation in assessing early and late dry ARMD, thereby explaining the correlation between anatomical and biochemical changes. Thus, these can be used as a progression predictor, when used together.

Keywords: Dry, Age-related macular degeneration, Spectral Domain, Optical Coherence Tomography, Fundus Autofluorescence, Retinal pigment epithelium

Cite This Article: SINGH, Archana et al. Assessment of early and late dry age-related macular degeneration with spectral-domain optical coherence tomography and fundus autofluorescence. International Journal of Retina, [S.I.], v. 7, n. 1, p. 8, feb. 2024. ISSN 2614-8536. Available at: <<https://www.ijretina.com/index.php/ijretina/article/view/264>>. Date accessed: 26 feb. 2024. doi: <https://doi.org/10.35479/ijretina.2024.vol007.iss001.264>..

Correspondence to:

Mohini Agrawal,
Department of Ophthalmology,
Military Hospital,
Jalandhar, India,
mohiniafmc.15@gmail.com

INTRODUCTION

Age related macular degeneration (ARMD) accounts for 8.7% of all blindness in developed countries and increases with ageing eyes.¹⁻² In the early stages, lipid material accumulates and deposits beneath the retinal pigment epithelium (RPE) and within the Bruch's membrane, referred to as 'Drusen'.² With advanced disease, RPE undergoes morphological changes and develops geographic atrophy/ or exudative disease leading to irreversible vision loss.³

The diagnosis of ARMD is usually by clinical examination using a high-definition fundus lens for stereo-biomicroscopy.⁴ Several imaging modalities have been found useful in studying the disease, in particular, fundus autofluorescence (FAF) and spectral-domain optical coherence tomography (SD-OCT). These modalities show specific changes which can be used as prognostic indicators for the disease.^{5,6} FAF along with SD-OCT has made it easier to diagnose ARMD, as these imaging modalities can reveal abnormal areas that may not be clinically visible on biomicroscopy.⁶⁻⁹ SD-OCT is widely used for the diagnosing early or late ARMD. It has great role in revealing structural abnormalities up to a resolution of 5-to-10 microns.¹⁰ OCT used with FAF is the current standard diagnostic and monitoring modality to detect dry ARMD and follow-up on its progression.

Both of these modalities are complementary in diagnosing ARMD and their correlation can be of diagnostic importance. Also, the correlation between the biochemical changes and structural changes in

the RPE layer may be of immense prognostic value. RPE over drusen in histological examination can be stretched and thin, thus drusen might be associated with alterations in the distribution of lipofuscin in the overlying RPE.

The purpose of this study was to assess features of early and late dry ARMD on SDOCT and FAF, to correlate between the two modalities for prognostication and to correlate with BCVA levels as well.

METHODS

This was an observational cross-sectional study carried out over a period of one year from January 2022 to December 2022. It was approved by Institutional Ethics Committee and conducted in accordance with the 'Declaration of Helsinki'. A written informed consent was taken from all the study subjects.

Patients attending the outpatient clinic of the department of ophthalmology at a tertiary care centre, Western Maharashtra, India were taken. All the clinically diagnosed cases of early to late dry ARMD of >55 years age was identified, based on the presence of drusen (>63µm) with or without pigmentary changes at the macula were included in the study. It was done by biomicroscopy with slit-lamp and dilated fundus examination using slit lamp and indirect ophthalmoscope. The diagnosis was confirmed by a vitreoretinal specialist.

Based on AREDS classification, early dry ARMD was defined as patients with <20 medium-size drusen (63-124µm) or with pigmentary changes. Intermediate dry ARMD was defined as patients with geographic atrophy (GA) that did not extend to macula or those with large drusen (125 µm), or at least 20 medium-size, or at least 65 medium-size defined drusen.

Late ARMD included geographic atrophy involving the foveal centre (dry ARMD) or choroidal neovascularisation (wet ARMD) or evidence of neovascular maculopathy (subretinal haemorrhage, serous retinal or RPE detachment).¹¹

Patients with wet ARMD, hereditary retinal disease, laser photocoagulation, pathological myopia, glaucoma, inflammatory choroidopathies, retinal detachment, ocular trauma, media opacity and cases who had undergone vitreoretinal surgeries were excluded from the study.

All selected cases underwent visual acuity testing by Snellen's chart, anterior and posterior segment examination by slit lamp biomicroscope and on confirming the diagnosis as dry ARMD, were taken up for FAF by using a fundus camera (Carl Zeiss FF 450 plus) with an excitatory filter of 488nm and SD-OCT (Carl Zeiss Cirrus 4000).

Authors stratified visual acuity into three groups- $\geq 6/12$, $<6/18$ - $6/36$ and $<6/36$.

Spectral-domain OCT is a commercially available device with a scan speed of 27,000 axial scans/second and an axial resolution of 5 μ m. Macular scan was acquired using macular cube 200x200 scan and 5-line raster protocol. IS-OS junction disruption or bumps in the RPE layers were considered suggestive of anatomical changes at the RPE level caused by dry ARMD.

OCT test was considered positive, if RPE irregularities were present in the macular area and was negative in absence of the same. FAF was considered positive in cases with hypo/ hyper autofluorescence in the macular area, while a normal fluorescence was considered negative.

The results of the two tests were recorded by two independent observers to eliminate observer's bias and finally the results were correlated with each other and with BCVA levels.

Sample size calculation

Kappa value of 0.73 was taken as reference from previous studies.¹²

The definition of κ is:

$$K = \frac{P_0 - P_e}{1 - P_e} = 1 - \frac{1 - P_0}{1 - P_e}$$

Where P_0 is the relative observed agreement among Raters, and P_e is the hypothetical probability of chance agreement. If the Raters are in complete agreement, then $K = 1$. If there is no agreement among the Raters other than what would be expected by chance (as given by P_e), $K < 0$. If we assume that the two Raters agree more than 50% of the times (kappa coefficient 0.73) with 20 % relative error and confidence interval of 95% the minimum sample size required is 100.

Statistical analysis

Data was analyzed using SPSS for Windows (version 20.0). Qualitative data variables were expressed as frequency and percentage while quantitative data variables expressed as Mean, SD and Median; t-test was applied to see the difference between different groups. A confidence level of 95% and $p < 0.05$ was considered significant.

RESULTS

One-hundred and six eyes of 60 cases were included in the study. Mean age at the presentation was 65.24 ± 4.80 years. Majority (53%) of the cases belonged to the age group between 60 to 70 years (table 1).

Table 1. Distribution Of Patients with Dry ARMD Stratified Based on Age

Age group	Number of patients	Percentage (%)
≤ 60 years	13	21.67
61 – 70 years	32	53.33
71 – 80 years	11	18.33
> 80 years	4	6.67
Total	60	100.00

showed RPE irregularity, which was there in all the cases with soft drusen, whereas it varied in cases with hard drusen.

In the FAF, be it hypo or hyper, macular abnormal FAF was observed in 81 eyes (76%) (table 2).

Table 2. Distribution Of Eyes Based on ARMD Patterns in Optical Coherence Tomography and Corresponding Fundus Autofluorescence and Correlation.

Pattern on SD-OCT	FAF		Total	Kappa-value
	Abnormal (Hypo Hyper)	& Normal		
Active (irregular)	66	3	69	0.60
Smooth	15	22	37	
Total	81	25	106	

There were 33 (55%) males and 27 (45%) females. Mean visual acuity was 0.4±0.24 LogMAR. Among clinically evident drusen, hard drusen (>63µm) was 88.6% (n=94 eyes), confluent soft drusen was evident in 9% (n=10 eyes) and pigmentary changes at macula in 2 eyes only. In the OCT, 66 eyes (65%)

Figure 1 to 3 depicts various types of clinically evident drusen and corresponding OCT and FAF images.

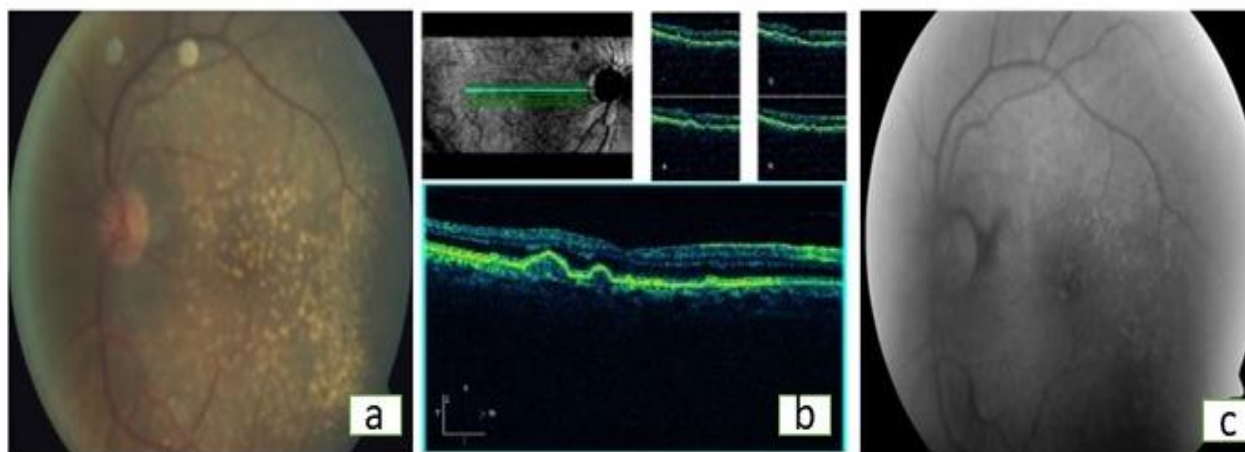


Figure 1: Image depicting (a) Colour fundus photo, (b) spectral-domain optical coherence tomography image and (c) fundus autofluorescence in a case of confluent soft drusen

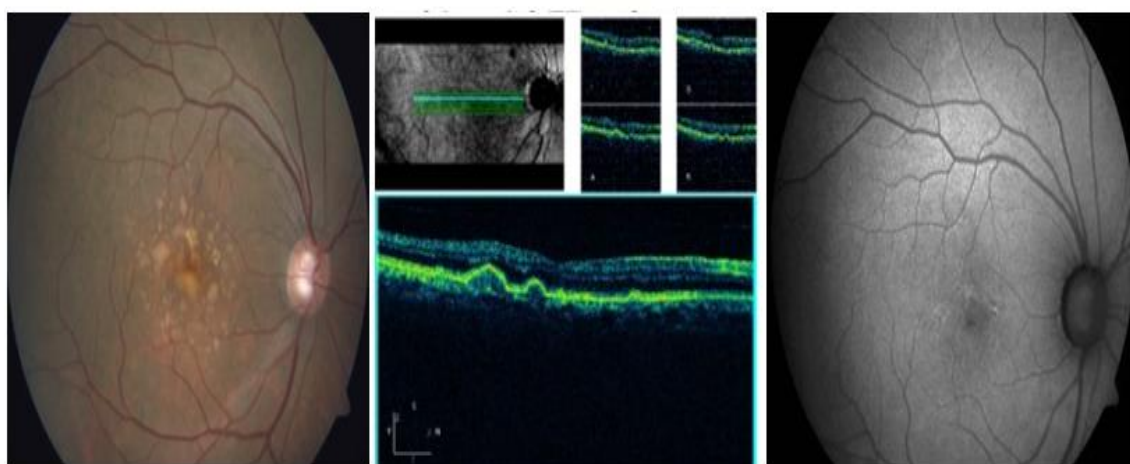


Figure 2: Image depicting (a) Colour fundus photo, (b) spectral-domain optical coherence topography image and (c) fundus autofluorescence in a case of intermediate hard drusen

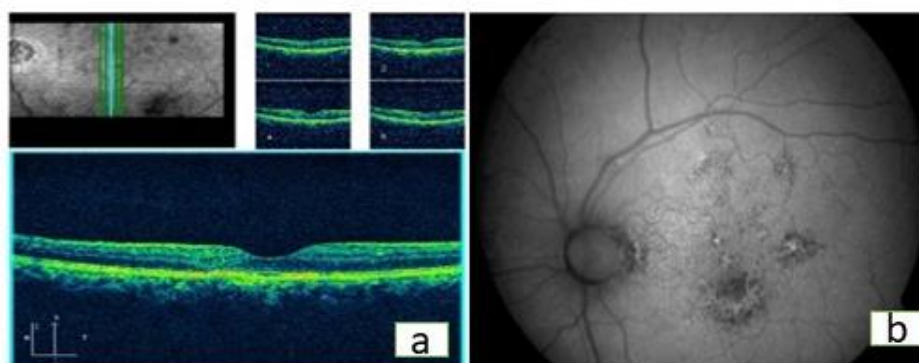


Figure 3: Image depicting (a) spectral-domain optical coherence topography image and (b) fundus autofluorescence in a case of pigment change at macula

When correlated with BCVA, RPE irregularities were more prevalent in the cases with BCVA between 6/18-6/36. An abnormality in macular autofluorescence was evident in 62% (n= 31) in cases with vision >6/12, whereas in cases with vision <6/18- 6/36, it was seen in 80% (n= 41) cases (table 3).

Table 3. Correlation Between ARMD Patterns on Optical Coherence Tomography and Corresponding Fundus Autofluorescence When Stratified Based on Best-Corrected Visual Acuity.

Best-corrected visual acuity	Pattern on SD-OCT	FAF		Total	kappa value
		Abnormal	Normal		
≥6/12	Active	26	0	26	0.80
	Smooth	05	19	24	
<6/18-6/36	Active	27	3	30	0.07
	Smooth	14	2	16	
<6/36	Active	8	0	8	1.0
	Smooth	0	2	2	

Fundus autofluorescence findings showed a slight deviation from the clinically evident changes in cases of ARMD. Cases with evident discrete hard drusen did not show obvious FAF findings, while a few patients with subtle pigmentary changes at the macula showed abnormal FAF. However, when compared to OCT, FAF was more sensitive in the group with good BCVA >6/12. A strong correlation was found between the positive OCT findings of RPE irregularity and abnormal FAF ($\kappa=0.60$) (table 2), suggesting comparable results by both the modalities in cases of early and late dry ARMD.

DISCUSSION

ARMD is a multifactorial disease affecting the macula resulting in progressive and irreversible blindness.¹³ Dry ARMD presents with very slowly progressive loss of vision which is irreversible due to damage of photoreceptors and progressive accumulation of debris and metabolic by-products between the RPE and Bruch's membrane.¹⁴ Various treatment modalities like anti-vascular endothelial growth factor and laser therapy, have been shown to result in improvement in wet ARMD¹⁵; whereas treatment of dry ARMD still remains at a nascent stage with prescription of multivitamins and anti-oxidant supplements to prevent the progression.¹⁶ Dry ARMD is also known to progress to wet ARMD, however features predisposing for the progression are not clearly identified.¹⁷ This study was an attempt to find factors suggestive of poor prognosis of the disease and also factors leading to early progression of dry ARMD to wet ARMD.

The results in our study on the prevalence and the morphology of drusen in dry ARMD were in accordance with previous studies.¹⁸⁻¹⁹ Studies suggested that RPE disruption is less commonly seen over intermediate hard drusen whereas confluent soft drusen are associated with more RPE irregularities¹⁸ as seen in figure 1. Our study also showed a similar pattern. When compared within the

visual acuity groups, RPE irregularities were noted more in the group with vision between 6/18-6/36. This constructs a fact that anatomical disruption at the level of RPE and Bruch's layer is associated with photoreceptors damage and responsible for the vision loss.

Abnormal autofluorescence, found in 81 eyes, was in the form of hyperfluorescence in clinically evident drusen at the macula and hypofluorescence in late stages with RPE atrophy. FAF showed various patterns in early ARMD which were observed in this study as well.⁹

It was strikingly observed that a few cases with clinically evident hard drusen did not show obvious FAF abnormality, while a few patients with subtle pigment changes at macula showed abnormal FAF. This is in accordance with the earlier studies which suggested that FAF was not merely dependent upon the size and number of drusen, but also on the composition of the drusen and the status of the RPE above and adjacent to the drusen.¹⁹

In this study, RPE irregularities on SDOCT and abnormal FAF strongly correlated ($\kappa=0.60$) in cases of dry ARMD. Hence, both the investigation modalities gave comparable results in dry ARMD cases. An interesting observation was made that a few cases with clinically evident drusen did not show significant OCT or FAF changes as depicted in figure 2, whereas cases with subtle pigment changes at the macula showed equivocal changes in both the investigation modalities as shown in figure 3.

A previous study Brar et al also showed a significant correlation between these two modalities with a comparable kappa value of 0.73.²⁰ Our study showed similar results but it differed in the inclusion criteria which included cases of both early and late dry ARMD. Our study included the whole spectrum of the disease with a sufficient sample size.

When this observation was correlated with BCVA of the respective cases, it exposed that the group with good BCVA was not showing changes on either OCT or FAF, even in the presence of clinically evident drusen.

This study was limited by its single-center, cross-sectional design with a small sample size. In the clinical practice, finding drusen at the macula is an important diagnostic criterion to label a case as dry ARMD. However, this finding hardly has any prognostic value. A serial observation of the patient and starting him/her on antioxidant therapy is not always considered to be useful. This study suggests us clues regarding the progressive pathogenesis of the disease and the importance of using FAF and OCT as diagnostic tools for dry ARMD patterns. A clinically diagnosed case, if has a negative FAF and negative OCT findings along with good BCVA, it can be kept under observation and can be followed-up on a yearly basis; whereas, any case with characteristic FAF and OCT findings along with low BCVA, should be kept under scrutiny and should be followed-up with investigations like Amsler's grid testing and fundus fluorescence angiography to rule out signs of progression.

CONCLUSION

To summarize, diagnosis of Dry ARMD is clinical, based upon the presence of drusen or pigment changes at the macula. However, these have no prognostic implications with respect to visual deterioration and conversion to wet ARMD. Currently there is no gold standard predictor for vision loss in cases of dry ARMD, but large studies using fundus autofluorescence have shown that progression rates in eyes with increased fundus autofluorescence were significantly higher compared to eyes without fundus autofluorescence abnormalities.

This study correlates the findings of SD-OCT and fundus autofluorescence in cases of clinically

diagnosed cases of dry ARMD. The study also suggests that, there is a strong association between changes seen in these two investigative modalities and can be used as a progression predictor when used together. However, the study doesn't show any significant difference between the two modalities and does not prove which modality is better. Further longitudinal studies may be required to understand the progression of the disease and specific changes which can predict the prognosis of the disease.

REFERENCES

1. Meleth AD, Rajji VR, Krishnadev N, Chew EY. Therapy of nonexudative age-related macular degeneration. In *Age-Related Macular Degeneration Diagnosis and Treatment* 2011 Jul 1 (pp. 65-78). New York, NY: Springer New York.
2. Bressler SB, Maguire MG, Bressler NM, Fine SL. Relationship of drusen and abnormalities of the retinal pigment epithelium to the prognosis of neovascular macular degeneration. *Archives of Ophthalmology*. 1990;108(10):1442-7.
3. Chakravarthy U, Evans J, Rosenfeld PJ. Age related macular degeneration. *Bmj*. 2010;26;340.
4. Ikram MK, Mitchell P, Klein R, Sharrett AR, Couper DJ, Wong TY. Age-related macular degeneration and long-term risk of stroke subtypes. *Stroke*. 2012;43(6):1681-3.
5. Venkatesh P, Sagar P, Chawla R, Gogia V, Vohra R, Sharma YR. Evaluation of fundus autofluorescence patterns in age-related macular degeneration. *International Journal of Ophthalmology*. 2016;9(12):1779.
6. Metrangolo C, Donati S, Mazzola M, Fontanel L, Messina W, D'alterio G, Rubino M, Radice P, Premi E, Azzolini C. OCT biomarkers in neovascular age-related macular degeneration: a narrative review. *Journal of ophthalmology*. 2021 Jul 19;2021.

7. Ly, Angelica, Lisa Nivison-Smith, Nagi Assaad, and Michael Kalloniatis. "Fundus autofluorescence in age-related macular degeneration." *Optometry and Vision Science* 94, no. 2 (2017): 246.
8. Sparrow JR, Duncker T. Fundus autofluorescence and RPE lipofuscin in age-related macular degeneration. *Journal of clinical medicine*. 2014 17;3(4):1302-21.
9. Bindewald A, Bird AC, Dandekar SS, Dolar-Szczasny J, Dreyhaupt J, Fitzke FW, Einbock W, Holz FG, Jorzik JJ, Keilhauer C, Lois N. Classification of fundus autofluorescence patterns in early age-related macular disease. *Investigative ophthalmology & visual science*. 2005;46(9):3309-14.
10. Țălu SD, Țălu Ș. Use of OCT imaging in the diagnosis and monitoring of age related macular degeneration. *Intech Open*; 2012.
11. Chandra S, McKibbin M, Mahmood S, Downey L, Barnes B, Sivaprasad S. The Royal College of Ophthalmologists Commissioning guidelines on age macular degeneration: executive summary. *Eye*. 2022 Nov;36(11):2078-83.
12. Brar M, Kozak I, Cheng L, Bartsch DG, Yuson R, Oster SF, et al. NIH Public Access. 2010;148(3):439-44.
13. Suetsugu T, Kato A, Yoshida M, Yasukawa T, Nishiwaki A, Hasegawa N, Usui H, Ogura Y. Evaluation of peripheral fundus autofluorescence in eyes with wet age-related macular degeneration. *Clinical Ophthalmology*. 2016;14:2497-503.
14. Lim LS, Mitchell P, Seddon JM, Holz FG, Wong TY. Age-related macular degeneration. *The Lancet*. 2012;379(9827):1728-38.
15. Ni Z, Hui P. Emerging pharmacologic therapies for wet age-related macular degeneration. *Ophthalmologica*. 2009;223(6):401-10.
16. Bandello, Francesco, Riccardo Sacconi, Lea Querques, Eleonora Corbelli, Maria Vittoria Cicinelli, and Giuseppe Querques. "Recent advances in the management of dry age-related macular degeneration: a review." *F1000Research* 6 (2017).
17. Kulkarni SR, Aghashe SR, Khandekar RB, Deshpande MD. Prevalence and determinants of age-related macular degeneration in the 50 years and older population: A hospital based study in Maharashtra, India. *Indian journal of ophthalmology*. 2013;61(5):196-201.
18. Rudolf M, Clark ME, Chimento MF, Li CM, Medeiros NE, Curcio CA. Prevalence and morphology of druse types in the macula and periphery of eyes with age-related maculopathy. *Investigative ophthalmology & visual science*. 2008 Mar 1;49(3):1200-9.
19. Hwang JC, Chan JW, Chang S, Smith RT. Predictive value of fundus autofluorescence for development of geographic atrophy in age-related macular degeneration. *Investigative ophthalmology & visual science*. 2006 Jun 1;47(6):2655-61.
20. Brar M, Yuson R, Kozak I, Mojana F, Cheng L, Bartsch DU, Oster SF, Freeman WR. Correlation between morphological features on spectral domain optical coherence tomography and angiographic leakage patterns in macular edema. *Retina (Philadelphia, Pa.)*. 2010 Mar;30(3):383.



This work licensed under Creative Commons Attribution