UNIVERSA MEDICINA

pISSN: 1907-3062 / eISSN: 2407-2230

Univ Med 2025;44:351-358

DOI: https://doi.org/10.18051/UnivMed.2025.v44.351-358

CASE REPORT

Cavernous sinus thrombosis: a case series analysis

Syntia Nusanti[1], Nadia Delima Andini[2], and Lourisa Ruth Eldinia[2]

[1]Neuro-ophthalmology Division, Ophthalmology Department, Faculty of Medicine, Universitas Indonesia - Dr. Cipto Mangunkusumo Hospital, Jakarta, Indonesia
[2]Residency Program in Ophthalmology, Faculty of Medicine, Universitas Indonesia – Dr. Cipto Mangunkusumo Hospital, Jakarta, Indonesia

*** Correspondence Author:**
syntia_nusanti@hotmail.com

Cite this article as: Nusanti S, Andini ND, Eldinia LR. Cavernous sinus thrombosis: a case series analysis. Univ Med 2025;44:351-358

Date of first submission, March 17, 2025
Date of acceptance, November 14, 2025
Date of publised, November 25, 2025

ABSTRACT

BACKGROUND
Although uncommon, cavernous sinus thrombosis (CST) is a serious and potentially life-threatening condition that often presents with nonspecific signs and symptoms. Cavernous sinus thrombosis is associated with high morbidity and mortality, estimated at approximately 15% and 11% respectively. The complex diagnostic and treatment processes pose a challenge for healthcare providers, considering its elevated mortality and morbidity. We present four cases with varying clinical presentations and outcomes to provide valuable insights into the manifestations and management of CST.

CASE DESCRIPTION
Our case series explored CST across age groups, including a case involving a pregnant woman. The clinical manifestations, laboratory data, imaging findings, pathogens, medications, surgical treatment, and clinical outcomes were analyzed. All cases were associated with one or more ophthalmic symptoms. All patients exhibited eye symptoms, with proptosis occurring unilaterally or bilaterally. Etiologies ranged from infections stemming from pimples and tooth cavities to an initially non-septic cause. Of the four cases presented, two proved fatal: one due to severe sepsis in a young man and the other initially aseptic but later progressing into sepsis in a geriatric man. The remaining two cases exhibited septic complications with complete recovery after prompt treatment.

CONCLUSION
Severity and clinical courses of CST varied, emphasizing the need for careful consideration and tailored management strategies in CST cases. The prognosis of CST has improved with the advancement in treatment, but complications are not infrequent. Raising awareness regarding the potential for severe complications, such as cavernous sinus thrombosis, initiated by a common infection, is strongly encouraged.

Keywords: Cavernous sinus thrombosis, proptosis, septic thrombosis, aseptic thrombosis, infection-related thrombosis

Copyright@Author(s) - https://univmed.org/ejurnal/index.php/medicina/article/view/1736

INTRODUCTION

Cavernous sinus thrombosis (CST) is a serious and life-threatening condition due to the formation of a blood clot in the cavernous sinus, a crucial venous structure located at the base of the brain.[1] This condition poses significant clinical challenges due to its rapid progression and a wide array of symptoms, stemming from both septic and aseptic causes. The pronounced ophthalmological manifestations of CST often demand immediate attention and are crucial indicators of the condition.[1–3]

From the cavernous sinus, infections can spread to other venous sinuses through communicating veins.[4] Although it was associated with high mortality and morbidity rates in the pre-antibiotic era, the incidence of CST has decreased drastically in the post antibiotic era. However, the mortality rate has remained as high as 20 - 30%.[5] Clinical presentations of CST are commonly fever and delirium, along with a range of ophthalmic symptoms that can involve cranial nerves III, IV, V (divisions V1 and V2), or VI, which all travel within the cavernous sinus and therefore are at risk of injury.[6]

In this case series featuring patients diagnosed with CST, we highlight the diverse etiologies, clinical presentations, and outcomes, emphasizing the variability of the condition.

The aim of this case series was to investigate the manifestations and management of CST.

CASE REPORTS

This case series will report 4 patients with CST at Dr Cipto Mangunkusumo Hospital, a national referral center in Indonesia.

Case 1

A 21-year-old male came to the emergency department with drowsiness (GCS E3V2M5) and swelling of both eyes. Seven days prior to admission, the patient was known to have a pimple on the superior left eyelid, causing progressive painful swelling and blurred vision of the left eye (LE). This symptom also involved the right eye (RE) within the following four days. There was no history of diabetes, hypertension, toothache, or any prior surgery. Both eyes showed movement restriction in all directions, ptosis, proptosis, lagophthalmos with corneal exposure, chemosis of inferior conjunctiva, and reduced light reflex. Visual acuity was difficult to evaluate due to decreased consciousness. Intraocular pressure was slightly elevated on the right eye (22 mmHg RE/12mmHg LE). Funduscopy was within normal limits. The suspicion of septic CST was supported by elevated septic markers accompanied by thrombocytopenia (C-reactive protein (CRP) 223, procalcitonin (PCT) 9.18, platelets (Plt) 148000) and coagulation markers [prolonged activated partial thromboplastin time (aPTT) 1.5x, fibrinogen 622.8, D-dimer >35200]. Diagnosis was confirmed by computed tomography (CT) angiography that revealed a contrast filling defect in the bilateral cavernous sinus (Figure 1). Patient was treated with intravenous (IV) ampicillin sulbactam 4x1.5g, continued with meropenem 3x1g. Anticoagulant therapy was given as a heparin drip at 10,000 units/24 hours, with a target of aPTT 1.5 – 2.5 times normal. Lid taping was also done to protect the exposed cornea. The progression of the severity was dreadful. In a one-day follow-up, the patient was intubated, and then died on the fourth day of admission.

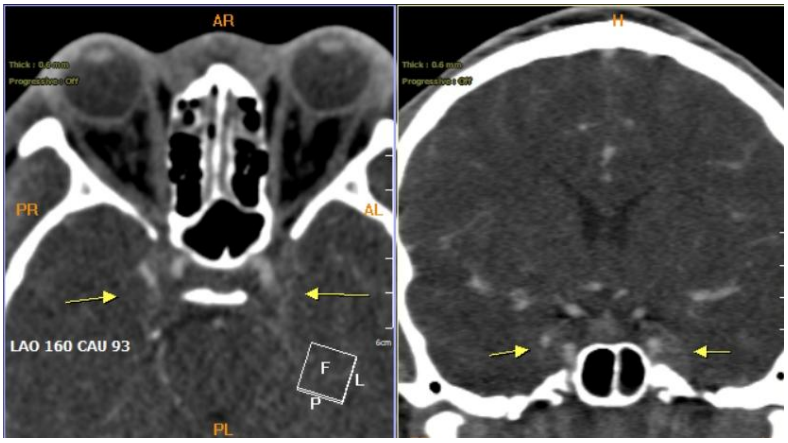

Figure 1. Filling defect in the bilateral cavernous sinus (arrows) in case 1

Case 2

A G1P0 23-year-old woman complained of a worsening swollen LE and left cheek for two weeks. The patient was 28 weeks pregnant and had no serious medical history. The patient had a toothache of the upper left tooth and fever since one week prior to her complaint. The patient had been treated with 2 days of IV antibiotics and eye medication for 5 days before admission. However, the symptoms worsened, causing her to be unable to close her LE and to have difficulty chewing and opening her mouth. Movement of LE was restricted in all directions with reduced VA (3/60) and increased intraocular pressure (IOP) to 23 mmHg. Non-axial proptosis with lagophthalmos of 12 mm and 1 mm of corneal exposure, redness and tenderness of palpebrae, chemotic inferior conjunctiva, and relative afferent pupillary defect (RAPD) were found only in the LE. Funduscopy of both eyes showed a normal appearance. There was a 6x6cm painful red hard mass on the left buccal region. Orbital CT-scan was in line with clinical findings that revealed thickening of the left cavernous sinus and dilation of the left superior ophthalmic vein, along with thickening of the left superior and inferior palpebrae. Patient was found to be anemic, leukocytosis, increased septic markers (PCT 0.24, CRP 139.3), and coagulation markers (D-dimer 3340, fibrinogen 754.1). All the findings supported the diagnosis of septic CST. Patient underwent incision and drainage of left maxillary abscess with IV and topical antibiotic (metronidazole 3x500mg, levofloxacin ED 6x1 LE, chloramphenicol EO 3x1 LE), heparin drip 20.000 IU/24 hours, and IV steroid (methylprednisolone 1x125mg). After treatment, the swellings were resolved completely.

Case 3

A 71-year-old man was referred to our ER for worsening blurry eyes and painful eyes radiating to the temple for two months. Ten days before admission, the LE started to swell, followed by the RE. VA at presentation was 1/300 for RE and No light perception (NLP) for the LE. Both eyes showed proptosis, conjunctival chemosis, and lagophthalmos with 2 mm corneal exposure for the RE. Ophthalmoplegia was present in both eyes. Left eye showed corkscrew vessels on the conjunctiva. Fluorescence test (+) for both eyes. Funduscopy of LE showed atrophy of the optic nerve head. Light reflex was decreased on the RE and negative on the LE. RAPD was positive on the LE. There was a lesion on the right trigeminal nerve branches V1 and V2. Dental examination showed pulp necrosis on 26,27, gangrenous radix 18, periodontitis 17,27, gingivitis, and pulp hyperemia 15,16. Blood glucose levels and coagulation markers were found to be elevated. CT angiography showed a heterogeneous filling defect in the bilateral cavernous sinus (Figure 2). Orbital CT showed bilateral CST with bilateral ocular rectus muscle thickening and retro-orbital fat stranding (Figure 3). The patient received IV ampicillin-sulbactam 4x1.5g, heparin 12,500IU/24 hours, IV analgesic, a NovoRapid (insulin aspart) pre-meal sliding scale when blood glucose>200mg/dL, and lid taping for both eyes. During hospitalization, the patient acquired a COVID-19 infection, and his condition deteriorated into sepsis. The patient died due to septic shock on the 35th day of hospitalization.

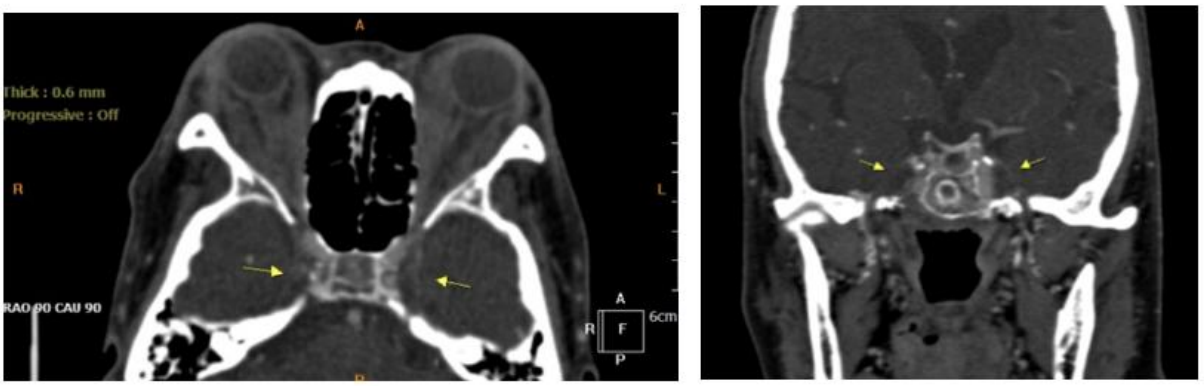

Figure 2. Filling defect in the bilateral cavernous sinus (arrows) in case 3

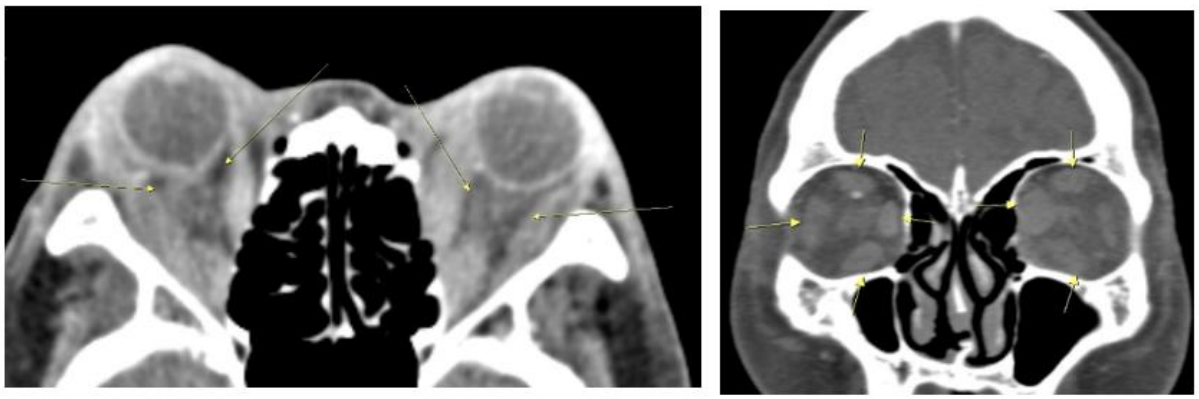

Figure 3. Bilateral ocular rectus muscle thickening and retro-orbital fat stranding (arrows) in case 3

Figure 4. Dilation of the left cavernous sinus with a filling defect (arrows) in case 4

Case 4

A 46-year old woman came with a chief complaint of painful progressive swelling of the LE for ten days. The patient had two cavities on the right upper tooth. LE movement was restricted to all directions. Ptosis, proptosis, lagophthalmos without corneal exposure, ciliary injection, and mid-dilated pupil were found on the LE. Visual acuity of his LE was light perception with projection (LPWP), which became NLP on the fifth day of admission, and his RE was 6/9. Funduscopy showed a normal appearance of both eyes. Paresis of cranial nerves III, IV, and VI on the left side was found. The laboratory result showed elevated infection markers (leukocytosis 14.000, CRP 12.6) and elevated coagulation markers (aPTT 61.7 and D-dimer 1000). The CT scan image showed sphenoidal sinusitis and a lesion on the cavernous sinus suggestive of CST with involvement of the left orbital fissure and optic nerve, accompanied by edema of the medial and inferior rectus muscle (figure 3). Patient was treated with IV ampicillin-sulbactam 4x1.5g, chloramphenicol eye drop 3x1, and heparin 20.000 IU/24 hours. The pain on LE had recovered within two weeks of treatment. Three months of follow-up at the outpatient clinic showed normal eye movement, no swelling on LE, and normal neurological status. However, the VA of LE remained NLP. Informed consent was obtained from the study subjects, and this case series was conducted in accordance with the Declaration of Helsinki.

DISCUSSION

Cavernous sinus thrombosis presents with a range of signs and symptoms. It can be categorized as either septic or aseptic, depending on its underlying cause.[1,2] The septic form is the more prevalent variant and is typically associated with infectious processes involving the paranasal sinuses, face, and ears. Conversely, the aseptic form is linked to factors such as trauma, thromboembolic events (including elevated factor VIII, reduced factor V Leiden, and deficiencies in proteins C and S), dehydration, and anemia, among others.[3]

In this series of cases, not surprisingly, infections arose from anatomical sites known to drain to the cavernous sinuses. The cavernous sinus (CS) is clinically important because it is close to many structures of the central nervous system and sense organs, and to some of the most important vessels in the head. Physiologically, it has many inflows because of connections with the

surrounding venous network, including the ophthalmic veins, spheno-parietal sinus, superficial middle cerebral vein (Sylvian vein), and pterygoid plexus located in the infratemporal fossa.[1,2] The cavernous sinuses and their connections are devoid of valves, consequently, infection and thrombi from the primary source spread from the vein to the CS and become trapped by the numerous trabeculations within the cavernous sinus.[7,8] This condition of valveless venous drainage in CS helps us understand the importance of "the danger triangle" of the facial region. The danger triangle on the human face encompasses a triangular region defined by the corners of the mouth and the bridge of the nose. The central point of the triangle lies at the base of the nose near the upper lip, which is also a critical area due to its vascular connections.[9] Infections occurring within the danger triangle can lead to CST. Cases presented by Van der Poel et al.,[10] Ooi et al.,[11] Li et al.,[12] Aloua et al.,[13] Wang et al.,[6] Absoud et al.,[14] and Weerasinghe and Lueck[15] showed that the most common primary foci of infection were the paranasal sinuses, usually manifesting as sinusitis, followed by odontogenic and midfacial infections.

Impaired inflow at the thrombosed cavernous sinuses causes venous congestion and pressure on the surrounding structures.[1,2] Compression of cranial nerves III, VI, and IV leads to ophthalmoplegia, which in turn causes the patient to experience diplopia. The loss of sympathetic nerves from the short ciliary nerve and parasympathetic nerves from cranial nerve III also causes the pupil to be non-reactive.[16]

Table 1. Comparison of the present case series with published studies on cavernous sinus thrombosis

Reported by	Type (n subjects)	Age (years)	Main etiology	Outcome
This report	Case series (n=4)	21 - 71	Infected pimple, odontogenic infection, sinusitis, aseptic → septic progression	2 deaths (sepsis, geriatric aseptic → septic), 2 recoveries (1 with permanent blindness)
Ooi et al.[11]	Case report (n=1)	18	Rhinosinusitis and cellulitis	Good recovery
Van der Poel et al.[10]	Case series (n=12)	2 - 79	Predominantly sphenoid sinusitis, also otitis media, pharyngeal abscess, fungal rhinosinusitis, and varicella	11 survived, 9 complete recovery
Li et al.[12]	Case report (n=1)	70	Septic CST from sinus infection, complicated with subarachnoid hemorrhage	Fatal (deterioration, coma, death)
Aloua et al.[13]	Case report (n=1)	61	Orbital cellulitis (maxillary sinusitis)	Partial recovery; blindness permanent, survival achieved
Wang et al.[6]	Review (n=8)	12 - 62	Sphenoid sinusitis	All survived, sequelae in 3 cases (Lemierre syndrome, photophobia, upward eye gaze limitation, cranial nerve palsy)
Absoud et al. [14]	Case report (n=1)	6	Sinusitis	Complete recovery
Weerasinghe and Lueck[15]	Review (n=88)	16 - 79	Paranasal sinusitis 57%, midfacial infections 12 cases and dental infections 11 cases	53 full recoveries, 16 deaths, 15 survived with a blind eye, palsy, or paresis, 4 unknown [NA]
Valentine et al.[16]	Case report (n=1)	Middle-aged	Odontogenic infection	Survived, left eye blind
Geng et al.[4]	Case series (n=14)	0.6 - 81	9 sinusitis, 3 orbital cellulitis, 1 pharyngeal phlegmon, 1 infected hardware from spine fusion surgery	9 full recoveries, 1 death, 1 complete vision loss, and 3 residual visual deficits

The vast majority of cases of septic CST have an acute presentation associated with prominent features of sepsis.[10] In this particular case series, all the patients displayed chemosis, with three of them additionally reporting instances of blurred vision, while one case with severe sepsis presented with mental deterioration. We observed positive RAPD and paresis of cranial nerves III, IV, V, and VI in two of our patients.

Magnetic resonance imaging (MRI) and CT scan are the primary radiological modalities used to confirm the diagnosis that should be suspected on clinical grounds. The cavernous sinus, a venous space with septations and flowing blood, typically exhibits minimal signal intensity on standard MRI sequences. In post-contrast images on MRI, normal cavernous sinuses display strong enhancement due to the slower flow of venous blood. Among the various venous connections associated with the cavernous sinus, the superior and inferior ophthalmic veins are important tributaries that drain into it. The dilation of the superior ophthalmic vein, therefore, serves as an indirect sign of cavernous sinus thrombosis.[7] In our cases, we utilized CT and CT angiography as diagnostic tools, confirming cavernous sinus thrombosis through the identification of thickening in the cavernous sinus, dilation of the ophthalmic vein, and muscle edema. Laboratory results in our patients indicated an elevation in infection and septic markers.

The choice of antibiotics was dependent on the (expected) causative microorganism. Our patients were treated using IV antibiotics ranging from ampicillin, sulbactam, and metronidazole. Additional topical antibiotics might be beneficial to treat local infection. As seen in this study, we used levofloxacin eye drops. Our patients received anticoagulant treatment due to elevated coagulation markers, with heparin being the most frequently administered anticoagulant. Anticoagulants improve blood flow to the cavernous sinus by eliminating clotting and thus may enhance the prognosis. A study conducted by Akarapas et al.(17) found a significantly lower mortality in the group that received anticoagulant therapy. However, it was emphasized that this should only be taken into consideration after conducting a CT scan to rule out cortical venous infarction and associated cerebral hemorrhage.[7] The use of corticosteroids in our patient was aimed at reducing inflammation in the surrounding muscle, aligning with findings from another study suggesting that corticosteroids may play a role in alleviating cranial nerve dysfunction and orbital congestion.[15]

Patients 2 and 4 showed positive outcomes following treatment. Patient 2 had fully recovered. Patient 4 made a good recovery with normal eye movement, no swelling in the LE, and a stable neurological status, although her VA in the LE remained NLP. Unfortunately, two of the four patients in this series did not survive. Patient 1 passed away within four days of admission due to severe sepsis, while patient 3, who was initially recognized as aseptic CST, died after three weeks of treatment due to septic shock caused by other comorbidities.

CONCLUSION

Cavernous sinus thrombosis may exhibit unspecified signs and symptoms. The ophthalmological symptoms associated with CST contribute to the early recognition of symptoms and enhance the overall treatment of patients. Severity and clinical courses were varied, emphasizing the need for careful consideration and tailored management strategies in CST cases.

Conflict of interest

All the authors declare that there are no conflicts of interest.

Acknowledgments

We would like to thank all the doctors and colleagues at Dr Cipto Mangukusumo Hospital, Jakarta, for their contribution.

Author Contributions

SN was the ophthalmologist who diagnosed and was responsible for the management of these patients. NDA and LRE : writing review and editing. SN supervised the case report and final manuscript. All authors contributed equally to the presentation of the case report and the manuscript. All authors have read and approved the final manuscript.

Funding

There are no financial conflicts or interests to disclose.

Data Availability Statement

The data supporting the findings of this study are available within the article. Additional data or case details may be provided upon reasonable request to the corresponding author, subject to patient confidentiality and ethical considerations.

Declaration of Use of AI in Scientific Writing

Nothing to declare.

REFERENCES

1. Balcerzak A, Tubbs RS, Zielinska N, Olewnik Ł. Clinical analysis of cavernous sinus anatomy, pathologies, diagnostics, surgical management

and complications – comprehensive review. Ann Anat 2023;245:152004. doi:10.1016/j.aanat.2022.152004.
2. Tanoue S, Hirohata M, Takeuchi Y, Orito K, Kajiwara S, Abe T. Venous anatomy of the cavernous sinus and relevant veins. J Neuroendovasc Ther 2020;14:547-57. doi:10.5797/jnet.ra.2020-0086.
3. Mira F, Costa B, Paiva C, Andrês R, Loureiro A. Cavernous sinus thrombosis. Rev Bras Oftalmol 2017;73:182-4. doi:10.5935/0034-7280.20140040.
4. Geng B, Wu X, Malhotra A. Septic cavernous sinus thrombosis—case series and review of the literature. Clin Neurol Neurosurg 2020;197:106092. doi: 10.1016/j.clineuro.2020.106092.
5. Caranfa JT, Yoon MK. Septic cavernous sinus thrombosis: a review. Surv Ophthalmol 2021;66:1021–30. doi: 10.1016/j.survophthal.2021.03.009.
6. Wang YH, Chen PY, Ting PJ, Huang FL. A review of eight cases of cavernous sinus thrombosis secondary to sphenoid sinusitis, including a12-year-old girl at the present department. Infect Dis (Lond) 2017;49:641–6. doi: 10.1080/23744235.2017.1331465.
7. Bhatia H, Kaur R, Bedi R. MR imaging of cavernous sinus thrombosis. Eur J Radiol Open 2020;7:100226. doi: 10.1016/j.ejro.2020.100226.
8. Bali R, Sharma P, Gaba S, Kaur A, Ghanghas P. A review of complications of odontogenic infections. Natl J Maxillofac Surg 2015;6:136. doi: 10.4103/0975-5950.183867.
9. Pannu AK, Saroch A, Sharma N. Danger triangle of face and septic cavernous sinus thrombosis. J Emerg Med 2017;53:137–8. doi: 10.1016/j.jemermed.2017.03.016.
10. Van Der Poel NA, Mourits MP, De Win MML, Coutinho JM, Dikkers FG. Prognosis of septic cavernous sinus thrombosis remarkably improved: a case series of 12 patients and literature review. Eur Arch Otorhinolaryngol 2018;275:2387–95. doi:10.1007/s00405-018-5062-9.
11. Ooi SY, Tan TS, Teo HE. Bilateral septic cavernous sinus thromboses: an uncommon complication of paranasal and orbital infection. Br J Hosp Med 2024;85:1–2. doi: 10.12968/hmed.2023.0274.
12. Li CR, Chen PH, Chen SY, et al. A rare intersection of septic cavernous sinus thrombosis and subarachnoid hemorrhage: insights from the case of a 70-year-old patient. Medicina 2024;60:253. doi: 10.3390/medicina60020253.
13. Aloua R, Kerdoud O, Slimani F. Cavernous sinus thrombosis related to orbital cellulitis serious complication to prevent: a case report and literature review. Ann Med Surg (Lond) 2021;62:179–81. doi:10.1016/j.amsu.2021.01.036.
14. Absoud M, Hikmet F, Dey P, Joffe M, Thambapillai E. Bilateral cavernous sinus thrombosis complicating sinusitis. J R Soc Med 2006;99:474–6. doi: 10.1177/014107680609900921.
15. Weerasinghe D, Lueck CJ. Septic cavernous sinus thrombosis: case report and review of the literature. Neuroophthalmology 2016;40:263–76. doi:10.1080/01658107.2016.1230138.
16. Valentine PP, Adrianto Y, Setyowatie S. Septic cavernous sinus thrombosis (CST) with blindness caused by odontogenic infection – a case report. Magna Neurologica 2023;1:1–4. doi: 10.20961/magnaneurologica.v1i1.477.
17. Akarapas C, Wiwatkunupakarn N, Sithirungson S, Chaiyasate S. Anticoagulation for cavernous sinus thrombosis: a systematic review and individual patient data meta-analysis. Eur Arch Otorhinolaryngol 2025;282:1127–34. doi: 10.1007/s00405-024-08992-4.

This work is licensed under a Creative Commons Attribution-NonCommercial-ShareAlike 4.0 International License