

SUCCESSFUL INTERNAL RIB FIXATION USING SHAPP PLATE IN ADULT WOMEN WITH RIB FRACTURE AND CHRONIC PAIN: A CASE REPORT

Ida Bagus Yudharma Indraharsana¹, Ketut Putu Yasa²

¹Balimed Hospital Denpasar

² Department of Cardiothoracic & Vascular Surgery, Prof. Dr. I.G.N.G Ngoerah General Hospital

²Faculty of Medicine, Udayana University

Article Info

Article History:

Received: 15 December 2025

Accepted: 30 December 2025

Published: 31 December 2025

Keyword: Rib fracture; Chronic pain; Internal rib fixation; SHAPP plate

Corresponding Author:

Ida Bagus Yudharma Indraharsana
Email:yudharmaindrharsana@gmail.com

Abstract

Rib fractures are common injuries occur 10% of all traumatically injured patients. Initial management involves adequate analgesia, thoracostomy drainage if indicated, and respiratory care. Surgical rib stabilization become increasingly important but still no international clear consensus on indication is available regarding indications and patient selection. No method and/or technique was found to be superior compared to others. The aim of this study is to describe outcome of internal rib fixation using SHAPP plate. We report a 52-year-old woman, came to emergency room (ER) after motorbike accident, right chest hit handlebar. Presented with bad right chest pain and pain when inhale, VAS 7. Chest radiograph revealed fracture right posterior rib 8,9,10 medial. Chest CT showed linier fracture non displaced of right posterior rib 7. Initial treatment consists of pain management. Patient discharged after three days. Follow up at two weeks, patient still felt right chest pain when inhale and during activities with VAS 6. Second CT revealed not found fracture of right posterior rib 6-7. Patient planned to undergo internal rib fixation. Indication of surgery is prolonged and worsened pain. Internal rib fixation used SHAPP plate. Patient clinical condition significantly improved post operative with length of stay 4 days. Follow up at one month after surgery, confirmed a full return to daily activities without pain. This study reported that rib fracture treated through internal rib fixation, allows rapid recovery as well as eradicating chronic pain causes by rib fracture its self.

Jurnal Mutiara Kesehatan Masyarakat

e-ISSN:2527-8185

Vol. 10 No. 2 Desember 2025 (Hal 157-164)

Homepage: <https://e-journal.sari-mutiara.ac.id/index.php/JMKM>

DOI: <https://doi.org/10.51544/jmkm.v10i2.6567>

How To Cite: Indraharsana, Ida Bagus Yudharma, and Ketut Putu Yasa 2025. "Successful Internal Rib Fixation Using SHAPP Plate In Adult Women With Rib Fracture And Chronic Pain: A Case Report" Jurnal Mutiara Kesehatan Masyarakat 10 (2): 157-164.

<https://doi.org/10.51544/jmkm.v10i2.6567>



Copyright © 2025 by the Authors, Published by Program Studi: Kesehatan Masyarakat Fakultas Farmasi dan Ilmu Kesehatan Universitas Sari Mutiara Indonesia. This is an open access article under the CC BY-SA Licence ([Creative Commons Attribution-ShareAlike 4.0 International License](https://creativecommons.org/licenses/by-sa/4.0/)).

1. Introduction

Rib fractures are the most common injuries following blunt chest trauma, occurring in approximately 10% of all traumatically injured patients and approximately 50% of blunt chest trauma population. Patients with eight or more rib fractures have a mortality rate of 34.4% with more than half of these patients requiring intensive-care unit (ICU) admission. The most common cause of blunt chest trauma is motor vehicle collisions (MVC) which account for up to 80% of injuries.

Rib fractures commonly present with pain localized to the chest wall and varying degrees of breathing difficulty. On physical examination, patients may exhibit localized tenderness, palpable crepitation, or reduced breath sounds. These clinical findings often contribute significantly to the development of complications that increase morbidity and mortality. The diagnosis of rib fractures can be established through clinical assessment or imaging studies, most often beginning with a standard chest radiograph. While some patients demonstrate markedly displaced rib fractures, others show no apparent displacement on initial computed tomography (CT) imaging despite the presence of fractures.

Current treatment objectives for multiple rib fractures focus on alleviating pain, improving respiratory function, and restoring the mechanical stability of the thoracic cage. Management strategies are generally classified into non-operative and operative approaches. For several decades, non-operative care has remained the primary treatment modality, emphasizing the prevention and management of complications related to pulmonary contusions and rib fractures, such as pain, atelectasis, and impaired pulmonary clearance. Patients presenting with fewer than three rib fractures and without associated injuries may be suitable for outpatient treatment using oral analgesic therapy; however, this decision should be individualized based on clinical assessment. Initial treatment typically includes adequate pain control, chest drainage when clinically indicated, and supportive respiratory interventions such as incentive spirometry. Effective and early analgesia is a cornerstone of management and is commonly achieved through a multimodal pain control strategy. In cases involving multiple or significantly displaced rib fractures, or when pain is unresponsive to systemic medications, regional anesthetic techniques may be utilized. These techniques include epidural catheter placement, paravertebral nerve blocks, and intercostal nerve block interventions.

Surgical stabilization of rib fractures is typically indicated for patients in whom sufficient pain control cannot be achieved due to the severity of the fractures, as well as for those at risk of developing respiratory failure. When indicated, this procedure is optimally performed within 48–72 hours following the injury. Over the past decade, surgical rib fixation has gained growing clinical relevance. In addition to re-establishing the alignment of fractured ribs and preserving the natural contour and mechanical function of the thoracic cage, rib stabilization surgery is intended to reduce underlying pathophysiological disturbances. Although rib fixation techniques were introduced many years ago, early applications were limited and relied on non-specialized devices such as wires, sutures, or standard reconstruction plates. Despite advances in surgical techniques and implant technology, there remains ongoing debate regarding patient selection and the criteria for determining who will benefit most from internal rib fixation.

In the absence of appropriate management, multiple fractures involving several ribs may result in loss of structural support of the chest wall. This condition can lead to paradoxical respiratory movement, characterized by inward collapse of the affected chest wall segment during inspiration and outward bulging during expiration, a phenomenon known as flail chest. Such instability may cause persistent chest wall

pain, impaired respiratory mechanics, respiratory distress, and long-term functional disability.

Although interest in surgical stabilization of rib fractures has increased, the existing literature has not yet established a universally accepted consensus regarding indications or patient selection criteria. It has been suggested that early surgical intervention may provide advantages for patients with multiple rib fractures. However, to date, no specific fixation method or surgical technique has demonstrated clear superiority over others.

The aim of this study is to describe the outcome of internal rib fixation using SHAPP plate in rib fractures patient with chronic pain.

2. Methods

This study is a case report describing the clinical outcome of internal rib fixation using a SHAPP plate in an adult patient with rib fracture and chronic pain. A 52-year-old woman who sustained blunt chest trauma from a motorcycle accident was evaluated through clinical assessment, physical examination, and radiological investigations including chest X-ray and computed tomography (CT) scan. Pain severity was assessed using the Visual Analog Scale (VAS). Initial conservative management was provided; however, due to persistent and worsening pain that limited daily activities, surgical intervention was performed. The patient underwent thoracotomy and internal fixation of the right posterior sixth and seventh ribs using a SHAPP plate. Postoperative outcomes were evaluated based on pain reduction, clinical improvement, length of hospital stay, radiological findings, and the patient's ability to return to normal daily activities during follow-up.

3. Results

A 52-year-old female came to emergency room (ER) with a chief complaint having bad right chest pain after she had traffic accident. She felt pain every start breathing. She denied shortness of breath. Mechanism of injury: She ride motorbike, suddenly she avoided another bike from opposite direction, and she fell down to right side, her chest hit her motorbike handlebars. Her motorbike speed around 50 km/hour. She denied head trauma, fainted, and history of unconscious.

Vital sign of the patient was: blood pressure 120/80 mmHg, heart rate 88 beats/min, respiratory rate 20 times/minute, body temperature 36.2°C, and oxygen saturation 98% room air, visual analog scale (VAS) 7. Chest physical examination was found no deformity, no lesion, tenderness on right chest, with normal lung sound, no rhonchi. ECG was performed revealed normal sinus rhythm, chest X-ray revealed fracture right posterior rib 8,9,10 medial side (Fig 1). Chest CT scan investigation revealed linier fracture non displaced of the right posterior rib 7, no visible pulmonary contusion, and no visible free fluid in pleural cavity (Fig 2).

The patient was diagnosed in the ER with Fracture Costae 6-7 Right Posterior. She treated immediately for pain management with paracetamol 1 gram intravenous, three times per day and hospitalize for observation purposed and prepare for surgical plan. After 24 hours observation in ward, clinically patient stable without dyspnea and minimal pain when move and when inhale or exhale, then we determined patient to delay surgical plan. After evaluation in the ward for three days, her pain reduces significantly with VAS 2. Patient was discharged. No operative procedure performed. She scheduled to have follow up on 14 days later in clinic.

In the 14 days later, she came to the clinic to follow up her condition. She still felt right chest pain every inhale and it also happened when she did her activities, in result limit her activities.

Vital sign of the patient was: blood pressure 110/80 mmHg, heart rate 90 beats/min, respiratory rate 20 times/minute, body temperature 36.2°C, and oxygen saturation 98% room air, visual analog scale (VAS) 6. Second chest CT scan evaluation revealed not found fracture of the right posterior rib 6-7, no visible pulmonary contusion, and no visible free fluid in pleural cavity (Fig 3).

The patient was diagnosed in clinic with Fracture Costae 6-7 Right Posterior with Chronic Pain based on anamnesis, physical examination, first radiology examination (first chest x-ray and first chest CT scan). She was planned to undergo thoracotomy with internal rib fixation (clipping costa) using SHAPP plate size 16 mm x 4.0 mm. This surgery performed with indication prolonged pain that comes and goes and worsened pain with VAS 6 (Moderate) during activity and deep breathing, that limited her movement and activities.

Figure 1 Initial chest X-ray showing fractures of the right posterior ribs 8–10

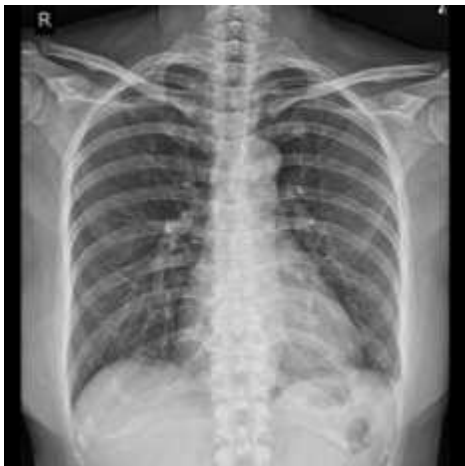

Figure 2. Initial chest computed tomography (CT) scan demonstrating a non-displaced fracture of the right posterior seventh rib

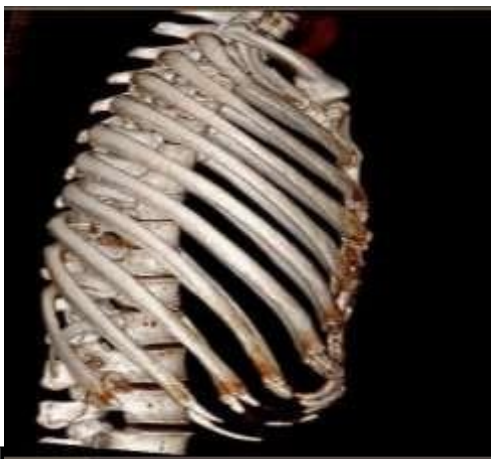
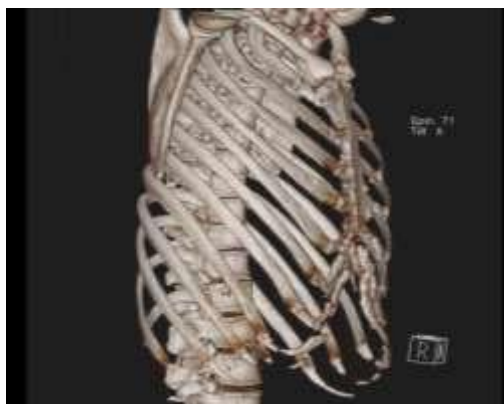
Figure 3. Initial chest computed tomography (CT) scan at two weeks showing no visible fracture line of the right posterior sixth and seventh ribs



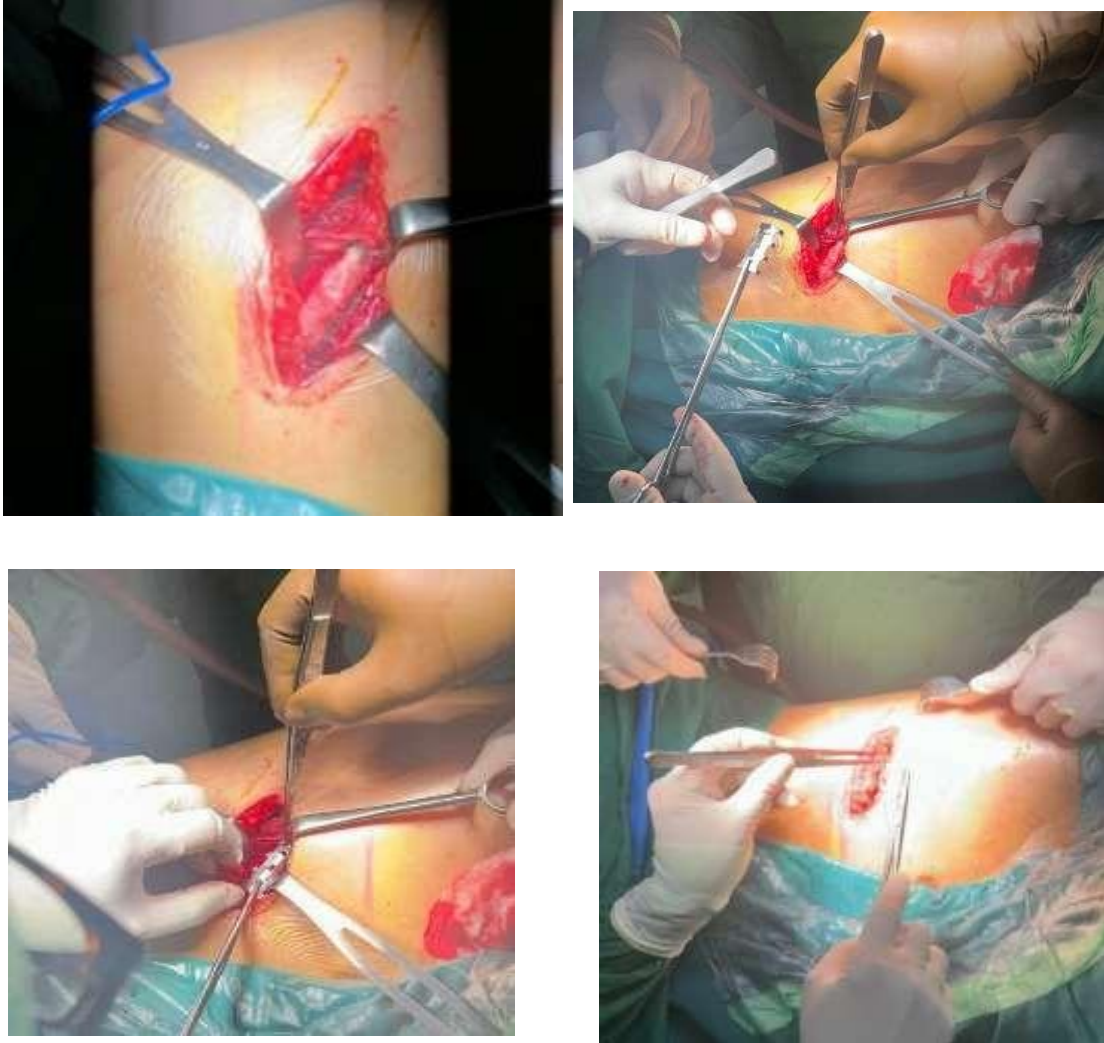


Figure 4. Intraoperative photographs showing thoracotomy and internal rib fixation of the right posterior sixth and seventh ribs using a SHAPP plate

During surgery, the patient was induced with general anesthesia and epidural anesthesia for pain management purpose. Patient positioned posterolateral and a lateral thoracotomy was performed. During opened chest wall, we found ribs right posterior 6-7 already had callus in fracture line, but the grew callus is malunion. Then, we clipping right posterior ribs 6-7 using SHAPP Plate with size of 16 mm x 4.0 mm. After that, we ensured reposition of the fracture is still preserved in an anatomical position. Surgical wound was closed layer by layer. The muscle layers are then approximated with 2-0 Vicryl, followed by a 3-0 Vicryl running suture of the subcutaneous tissue. Finally, the skin is closed using interrupted or intradermal absorbable running suture. (Fig 3).

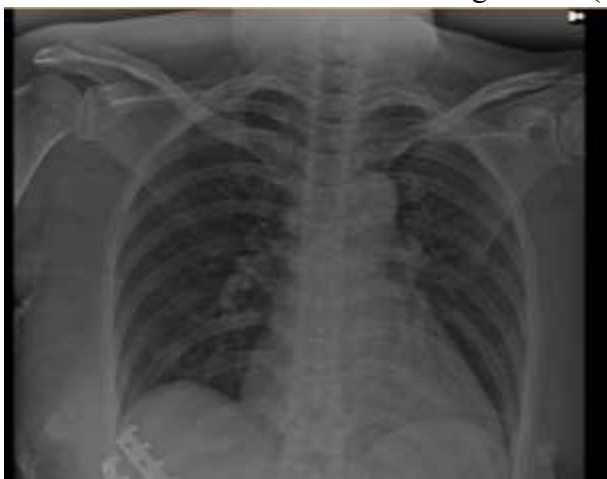

Figure 5. Postoperative chest X-ray confirming appropriate SHAPP plate placement and rib alignment

After surgery and observed in recovery room for 2 hours, the patient relayed resolution of the painful chest pain and right shoulder pain minimal. Post operative chest x-ray film confirmed internal fixation is visible with the right ribs position relatively good plate position (Fig 5). She moved to ward and got therapy paracetamol 500 mg six times per day orally and ketorolac 30 mg three times per day intravenously. After four days hospitalization, she was discharged. Two weeks after surgery, patient has recovered well with no residual pain or instability, no right chest pain. One month after surgery, there was no any recurrence pain or complaint that found in patient. Patient suggested to do daily physiotherapy for respiratory support.

4. Discussion

Rib fractures represent one of the most frequently encountered traumatic injuries and are associated with substantial morbidity and mortality, particularly when pain and chest wall instability impair respiratory mechanics. The structural stability of the chest wall is primarily maintained by ribs four through ten, which play a crucial role during respiration. Fractures involving these ribs may cause continuous mechanical irritation between fracture fragments, resulting in persistent pain that limits daily activity, as observed in the present case.

Rib fractures are frequently underdiagnosed during initial imaging evaluation. Previous studies have reported that up to 39.5% of rib fractures may be missed on initial computed tomography (CT) scans. Advanced imaging modalities, including CT, magnetic resonance imaging (MRI), and ultrasonography, have therefore been recommended to improve diagnostic accuracy. In the present case, follow-up CT imaging did not demonstrate a visible fracture line of the right posterior seventh rib, despite persistent pain. This finding supports existing evidence that radiological healing or inconspicuous fracture lines do not necessarily correlate with clinical recovery, particularly in cases complicated by malunion or chronic pain.

Conservative management remains the first-line treatment for most rib fractures and focuses on adequate pain control and respiratory support. Multimodal analgesia, including acetaminophen, nonsteroidal anti-inflammatory drugs (NSAIDs), and opioids when required, is essential to prevent respiratory complications. In this case, initial conservative treatment resulted in temporary improvement, leading to delayed surgical intervention. However, persistent activity-related pain and functional limitation suggested failure of conservative management, consistent with previous reports indicating that 40–60% of patients treated non-operatively may experience prolonged pain or delayed return to work.

The decision to proceed with surgical fixation was based on persistent pain, radiological evidence of malunion, and impaired quality of life. Current literature increasingly supports surgical stabilization of rib fractures, particularly in patients with ongoing pain or chest wall instability. Compared with conservative treatment, surgical fixation has been associated with better pain control, earlier mobilization, and faster return to daily activities. Although early fixation within 72 hours is often recommended, this case demonstrates that delayed surgical intervention may still

provide significant clinical benefit in selected patients with chronic symptoms. Various rib fixation techniques have been described, including bicortical plate fixation, bioabsorbable systems, Judet struts, Kirschner wires, and intramedullary devices. Among these, plate fixation remains the most widely used due to its stability and adaptability. The SHAPP plate represents an alternative fixation method with structural characteristics comparable to Judet struts or U-shaped plates. Compared with conventional plating systems, the SHAPP plate offers technical simplicity, adaptability to posterior rib fractures, and the potential for fixation of multiple ribs through a relatively limited surgical approach. In the present case, internal fixation using a SHAPP plate resulted in rapid pain resolution, stable chest wall reconstruction, and early return to normal activity, supporting its effectiveness as a viable fixation option.

Despite the favorable outcome, this study has several limitations. As a single-case report, the findings cannot be generalized to all patients with rib fractures. The follow-up period was relatively short, and long-term outcomes such as implant-related complications or late recurrence of pain could not be evaluated. Additionally, the absence of a direct comparison group limits the ability to draw definitive conclusions regarding the superiority of the SHAPP plate over other fixation methods.

Nevertheless, this case contributes to the growing body of evidence supporting surgical rib fixation in patients with persistent or chronic pain following rib fractures. The successful outcome observed in this patient suggests that internal rib fixation using a SHAPP plate may be an effective treatment option when conservative management fails. Further prospective studies and comparative trials are needed to establish standardized indications and to determine the relative advantages of different rib fixation techniques.

5. Conclusion

Internal rib fixation using a SHAPP plate provided significant clinical improvement in this patient with posterior rib fractures and chronic pain following blunt chest trauma. The procedure resulted in substantial pain relief, restoration of chest wall stability, and a rapid return to normal daily activities without recurrence of symptoms. This case suggests that surgical rib fixation may be an effective treatment option for patients with persistent or chronic pain due to rib fractures when conservative management fails, although further studies are needed to establish clear indications and standardized guidelines.

6. References

1. Zachary MB, Benjamin G, Ujwal Y, Valerie S, Brett W, Charity HE, et al. Rib fracture displacement worsens over time. *European Journal of Trauma and Emergency Surgery*. (2021) 47:1965–1970.
2. Yongjing L, Shun X, Qi Y, Yu T, Leilei P, Shengbo Q, et al. Surgical versus conservative therapy for multiple rib fractures: a retrospective analysis. *Annals of Translational Medicine*. 2018;6(22):439.
3. NIH; National Library of Medicine. Thoracic Trauma. [Internet] 2023 [cited 2024 August 23]. Available from: <https://www.ncbi.nlm.nih.gov/books/NBK534843/>.
4. Reinier BB, David R, Mirjam BJ, Rolf HHG, Falco H, Michael JRE, et al. Rib fixation versus non-operative treatment for flail chest and multiple rib fractures after blunt thoracic trauma: a multicenter cohort study. *European Journal of Trauma and Emergency Surgery*. (2019) 45:655–663.
5. Farhan AM, Usama Z, Tashfeen I, Syed ZAS, Ahmad A, Umer M. Rib fixation versus conservative management of rib fractures in trauma patients. *J Ayub Med Coll Abbottabad* 2018;30(4).

6. Moussa M, Bader AS, Ghassan AE, Youssef A. Costal cartilage fracture: A commonly missed thoracic injury in trauma patients. Elsevier. Radiology Case Reports Volume 17, Issue 1, January 2022, Pages 95-98.
7. Gregor JK, Mohammad AH, Fabrizio M. Surgical fixation of rib fractures: how I do it. J Vis Surg 2020;6:16 | <http://dx.doi.org/10.21037/jovs.2019.11.04>
8. Ronald WK. Surgical Plate Fixation of Simple Rib Fractures: A Case Report. Journal of International Surgery and Clinical Medicine 2022;2(1): 6-9 | <https://doi.org/10.51559/jiscm.v2i1.22>
9. Puruhito. Buku ajar primer ilmu bedah toraks, kardiak, dan vaskular. 1st ed. Surabaya: Pusat Penerbitan dan Percetakan Unair; 2013. p.34-35.
10. Dedy F, Ristiawan ML, Isngadi. Anestesi Epidural Thorakal pada Operasi Shapp Plate pada Pasien dengan Fraktur Kosta Tertutup Multipel. Anesthesia & Critical Care. Vol. 32 No. 2 Juni 2014