

## Development of Pineapple Skin Extract Hydrogel Patch Applications (*Ananas comosus L.*) as Wound Dressing in Diabetic Ulcers in Mice (*Mus musculus*)

Putik Titian Citra Hening<sup>1)</sup>, Anisah Putri Yuana Sari<sup>1)</sup>, Marshanda Nikita<sup>1)</sup>, Fajrina Rizqi Riyadi<sup>2)</sup>, Ahmad Maulana Al Fatah<sup>3)</sup>, Ihsanti Dwi Rahayu<sup>1\*)</sup>

<sup>1)</sup>Pharmacy Study Program, Department of Pharmacy, Faculty of Medicine, University of Lampung, Lampung, Indonesia,

<sup>2)</sup>Medical Education Study Program, Faculty of Medicine, University of Lampung, Lampung, Indonesia,

<sup>3)</sup>Applied Biology Study Program, Faculty of Mathematics and Natural Sciences, University of Lampung, Lampung, Indonesia

Email : [ihsanti.rahayu@fk.unila.ac.id](mailto:ihsanti.rahayu@fk.unila.ac.id)

### Abstract

Diabetes mellitus is a chronic metabolic disorder caused by high blood glucose levels. One common complication in diabetes mellitus sufferers is diabetic ulcers. Research has shown that pineapple skin contains flavonoid, an active compound with anti-inflammatory and antimicrobial properties, which can accelerate wound healing. This study aims to determine the effect of applying a hydrogel patch containing pineapple peel extract (*Ananas comosus L.*) as a wound dressing on male white mice (*Mus musculus*) with diabetic ulcers. The study involved several stages, including pineapple peel extraction, hydrogel patch preparation, antibacterial activity testing, and application of the hydrogel patch on test animals. The research used 20 male white mice of the *Deutschland Denken Yoken* (DDY) strain divided into 5 groups. The negative control group received a hydrogel patch without extract, while the positive control group received Hydrocolloid Dressing. Treatment groups I, II, and III were given hydrogel patches with 10%, 20%, and 30% pineapple peel extract, respectively. The results showed that the hydrogel patch with pineapple peel extract accelerated wound healing in diabetic ulcer models. The antibacterial activity test indicated antimicrobial activity against *Staphylococcus aureus*, commonly found in diabetic ulcers. The hydrogel patch application reduced inflammation and improved skin tissue structure in test animals, demonstrating the potential of pineapple peel extract hydrogel patches as an effective alternative wound dressing for diabetic ulcers.

**Keywords:** diabetic ulcer, pineapple peel extract, hydrogel patch, wound dressing

### 1. INTRODUCTION

The World Health Organization (WHO) stated that in 2021 there will be more than 537 million adults living with diabetes worldwide. According to the International Diabetes Federation (IDF), the number of diabetes patients in Indonesia increased

rapidly by 167% over the past ten years, as of 2021. Diabetes mellitus often leads to complications such as diabetic ulcers.

Currently, the incidence of diabetic ulcers in Indonesia is quite high, with an annual prevalence of 5-7.5%. Therefore, the

management of diabetic ulcers requires a comprehensive approach, including good glycemic control and proper wound care using appropriate wound dressings. On the other hand, the Central Statistics Agency (BPS) stated that in 2022 Lampung Province will be the largest pineapple producer in Indonesia with total production reaching 861,706 tons. However, in general, the majority of Lampung people only consume pineapple flesh, while pineapple tubers and skin are often considered waste.

Pineapple skin has secondary metabolites, such as flavonoids (Base et al., 2023). Flavonoids act as antioxidants, anti-inflammatory, antibacterial, anticancer and antiviral so they can play a role in the process of restoring damaged body tissue, especially in conditions where diabetic wounds occur (Rathnavelu et al., 2016). This is confirmed by research which states that ethanol extract of pineapple peel with a concentration of 50% produces an inhibitory zone with a diameter of 13 mm against *Escherichia coli* bacteria, 16 mm against *Staphylococcus aureus* (Omorotionmwan et al., 2019). Wounds that are moist can accelerate the rate of tissue epithelialization and speed up the process of tissue autolysis, thereby reducing the risk of wound infection (Angriani et al., 2019). Accelerating the wound healing process can also be helped by using medication in the form of a hydrogel patch. Hydrogel patches are a form of dressing that possess beneficial properties and are often used as wound dressings in the healing process, particularly for diabetic ulcers (Harliantika dan Noval, 2021). The coating on the hydrogel patch *preparation* has the ability to absorb and retain water moisture when it comes into

contact with a wet wound, thereby preventing infection and accelerating skin regeneration (Hanistya & Samlan, 2021).

This research was conducted in the context of testing and evaluating the use of pineapple peel extract in the preparation of *hydrogel patches* for healing diabetic ulcers. This research aims to develop a formulation and test the effectiveness of a hydrogel patch *preparation* containing pineapple peel extract (*Ananas comosus* L.) as a wound dressing for diabetic ulcers in *Deutschland Denken Yoken* (DDY) mice. It is hoped that this research can provide innovative and effective solutions in treating diabetic ulcers and provide additional benefits in utilizing pineapple peel waste.

## 2. METHODS

This research was conducted at the Chemistry Laboratory, Microbiology Laboratory, Pharmaceutical Laboratory, Animal House, Faculty of Medicine, University of Lampung, from April to June 2024.

### Materials and Tools

The materials used in this research are pineapple peel, filter paper, distilled water, ethanol 96%, chloroform, *dimethyl sulfoxide* (DMSO), Polyvinyl Alcohol (PVA), Polyethylene Glycol (PEG 400), Hydroxypropyl Methyl Cellulose (HPMC), aluminum foil, non-woven plaster, universal pH, mouse feed, male white mice (*Mus musculus*) *Deutschland Denken Yoken* (DDY) strain, alloxan, razor, biopsy punch, glucometer strips, *Staphylococcus aureus* bacterial culture, Hydrocolloid Dressing, Mueller Hinton Agar (MHA) media, and Gentamicin 10 µg/disc paper disks, blank paper disk. The tools used in this research

includes were analytical balance, blender, rotary evaporatory, desiccator, vernier caliper, incubator, oven, thermometer, hot plate, magnetic stirrer, glucometer, waterbath, injection syringe.

### **Plant Determination Test**

Plant taxonomic identification was carried out at the Biological Botany Laboratory, FMIPA, University of Lampung.

### **Making Pineapple Peel Simplisia**

Pineapple skin samples (*Ananas comosus* L.) from this research were obtained from the Bambu Kuning Market, Bandar Lampung City. The pineapple skin that will be used is washed first using running water and then drained. Clean pineapple skin is wet sorted. Next, drying was carried out using sunlight and an oven at a temperature of 50°C. Simplify dry pineapple skin, blend until it becomes powder.

### **Making Pineapple Peel Extract**

Pineapple skin is extracted using the maceration method. The stages of the maceration process include collecting materials, sorting, washing, drying, grinding, and soaking in 96% ethanol for 3 x 24 hours in a container protected from direct sunlight. The filtrate was obtained by filtering using filter paper and evaporating using a rotary evaporator at a temperature of 40-50°C until a thick extract was formed.

### **Phytochemical Screening Test**

The thick extract obtained was subjected to a qualitative phytochemical screening test to identify secondary metabolite compounds in pineapple samples by observing color changes after adding reagents. The compounds analyzed included flavonoids, tannins, saponins, phenolics, alkaloids, steroids, and triterpenoids (Reiza et

al., 2019). For flavonoids, the extract was dissolved in 70% ethanol, heated, and then mixed with concentrated HCl and Mg powder; a yellow-orange to dark red color indicated positive results. Phenolics were tested by adding FeCl<sub>3</sub> solution to the extract, with a blue or purple color indicating their presence. The saponin test involved shaking the extract solution, and persistent foam indicated saponin content. Tannins were tested using 1%FeCl<sub>3</sub>, with a blackish green or blackish blue color indicating positive results. Triterpenoid and steroid tests used chloroform, anhydrous acetic acid, and concentrated H<sub>2</sub>SO<sub>4</sub>, with a brownish or violet ring for triterpenoids and a bluish-black green color for steroids indicating positive results. The alkaloid test involved Mayer, Wagner, and Dragendorff reagents, showing positive results through white, orange to brown precipitates in each test tube (Reiza et al., 2019)

### **Antibacterial Test**

The antibacterial test was carried out using the disc diffusion method on MHA media against gram-positive bacteria in the form of *Staphylococcus aureus*. The extract concentrations tested were 10%, 20%, and 30% and Gentamicin as a positive control (Sitepu et al., 2022). This method involves absorbing antibacterials onto paper discs, which are then attached to a medium homogenized with bacteria. After incubation, an inhibitory zone forms around the disc as an indication of an antibacterial reaction (Novita, 2016)

## Formulation of the Hydrogel Patch

**Table 1. Pineapple Peel Extract Hydrogel Patch Formulation**

Material	Function	Control	F1	F2	F3
Pineapple Peel Extract	Active ingredient	-	10 %	20%	30%
PVA	Backing	2.5%	2.5%	2.5%	2.5%
PEG 400	Plasticizer	10%	10%	10%	10%
HPMC	Gel base	5%	5%	5%	5%
DMSO	Enhancer	3%	3%	3%	3%
Aquadest (ad)	Solvent	100 g	100 g	100 g	100 g

Description: control = formula without pineapple peel extract; F1 = formula with 10% pineapple peel extract; F2 = formula with 20% pineapple peel extract; F3 = formula with 30% pineapple peel extract.

The formulation stage of this preparation begins with the process of weighing the ingredients, then all the ingredients are mixed for 30 minutes using a magnetic stirrer. Next, the preparation was put into a baking dish and dried in the oven at 40°C for 24 hours. Once solid, it is cut to 1 x 1 cm<sup>2</sup> then attached to a layer of non-woven plaster. Packaged in aluminum foil and stored in a cool place away from sunlight.

### Application of Hydrogel Patch on Test Animals

#### Selection of Test Animals

In testing the effectiveness of the preparation, test animals were used in the form of male white mice (*Mus musculus*) of the DDY strain aged 6-8 weeks with a body weight of around 25-30 grams (Azizah & Qomariyah, 2021)

#### Animal Model Testing of Diabetes Mellitus

Before being given treatment and measuring initial blood glucose levels, all mice underwent fasting for 12 hours. Then the mice were induced subcutaneously with 150 mg/kg alloxan. On the third day after

induction, fasting blood sugar is checked. Mice with fasting blood sugar more than 180 mg/dl are considered diabetes model mice (Haryanto et al., 2023)

#### Create Diabetic Ulcers in Test Animals

Ulcer creation was carried out when the mice were already experiencing hyperglycemia. The creation of ulcers begins with shaving the hair on the mice's backs, then the mice are anesthetized with chloroform inhalation. Then an ulcer was created by making a hole in the back of the mouse with a 5 mm biopsy punch. The wound was then made into an infected wound model by administering *Staphylococcus aureus* bacteria. After the wound model is formed, the wound is left for 3 days. (Golmohammadi et al., 2020).

#### Hydrogel Patch Preparation in Test Animals

Mice that had become diabetic ulcer models were divided into 5 treatment groups. The positive control group (K1) was given Hydrocolloid Dressing. The negative control group (K2) was given a hydrogel patch without extract. Treatment groups I (K3), II (K4), and III (K5) were given pineapple peel extract hydrogel patches with concentrations of 10%, 20%, and 30%. Observations were made of wound diameter closure with a pineapple peel extract hydrogel patch for 21 days. Replacement of pineapple peel extract hydrogel patch and documentation done every 2 days. Evaluation of healing was carried out by measuring the wound diameter vertically and horizontally using ImageJ software.

#### Data analysis

Data analysis used included data normality tests using *the Shapiro-Wilk test*

and homogeneity tests using *the Levene test*. The data were distributed normally and homogeneously, followed by the ANOVA ( Analysis of Variant ) test to test the significance of the differences in the averages of several groups, to determine whether there were differences between treatment groups, which was followed by the LSD ( Least Significant Difference ) test with a significant value of  $p < 0,05$  states that there is a significant average difference (Mustika et al., 2020).

### 3. RESULT AND DISCUSSION

#### Plant Determination

Plant determination tests were carried out at the Biological Botany Laboratory, FMIPA, University of Lampung. Based on the identification results, it can be seen with certainty that the sample used in this research is Pineapple (*Ananas comosus* (L.) Merr.). Pineapple plants belong to the *Ananas* genus and *the Bromeliaceae* family.

#### Pineapple Skin Extraction Results

In the extraction process, 10 kg of pineapple skin was used. Pineapple skin shrinks after drying by 89.68%. The net weight of pineapple peel *simplicia* after drying is 1032 grams. Extraction of pineapple peel waste with 96% ethanol solvent produced a thick extract of 121.21 grams, then the yield value was calculated. The results of the yield calculation obtained a value of 11.74%, while the requirement for the yield of thick extract was that the value was not less than 10% (Farmakope Herbal, 2017). So the yield of pineapple peel extract meets the requirements (Syamsul et al., 2020).

#### Phytochemical Test Results

Based on the results of phytochemical tests that have been carried out, the ethanol extract of pineapple peel positively contains several secondary metabolites, namely tannins, saponins, flavonoids, triterpenoids, phenolics and alkaloids in *dragendorff* and *bouchardat* reagents (Reiza et al., 2019).

**Table 2. Results of Phytochemical Tests**

<b>Results of Phytochemical Tests</b>				
<b>Compound groups</b>	<b>Reagents</b>	<b>Positive results</b>	<b>Results Identifications</b>	<b>Conclusions</b>
Tannin	FeCl <sub>3</sub> 1%	Dark blue or blackish-green in color	Green-black in color	<b>Positive</b>
Saponins	HCl	Foam forms and lasts for 5 minutes	Foam lasts 5 minutes	<b>Positive</b>
Flavonoids	Concentrated HCl + Mg	Orange to red in color	Deep red in color	<b>Positive</b>
Steroids	Acetic anhydride and concentrated H <sub>2</sub> SO <sub>4</sub>	Bluish-green in color	No color change	<b>Negative</b>
Terpenoids	Acetic anhydride and concentrated H <sub>2</sub> SO <sub>4</sub>	Brownish and violet rings	Brownish ring formed	<b>Positive</b>
Phenolics	Iron(III) chloride 1%	Blue or purple in color	Blue coloured	<b>Positive</b>
Alkaloids	Mayer	White precipitate formed	Not formed	<b>Negative</b>
	<i>Bauchardat</i>	Formation of brown sediment.	Brown precipitate formed	<b>Positive</b>
	<i>Dragendorff</i>	Formed brownish orange precipitation	Formed brownish orange precipitation	<b>Positive</b>

### Antibacterial Test Results

In the antibacterial test, the inhibition zone was measured to determine the antibacterial activity of the hydrogel patch preparation. The inhibition zone measurements were interpreted as follows:

$$\text{Zone of Inhibition} = \frac{(VD - D) + (HD - D)}{2}$$

Antibacterial inhibitory power is grouped into four groups; weak (<5 mm), moderate (5-10 mm), strong (10-15 mm), and very strong (>15 mm) (Davis and Stout, 1971 quoted from Masykuroh, 2022).

**Table 3. Antibacterial Test Results**

<b>Concentration</b>	<b>Zone of inhibition (mm)</b>	<b>Categorize</b>
Control (+)	16.34	Strong
10%	0.48	Weak
20%	1.05	Weak
30%	0.85	Weak
Control(-)	0	Weak

Information: D = disk diameter, VD = vertical diameter, HD = horizontal diameter

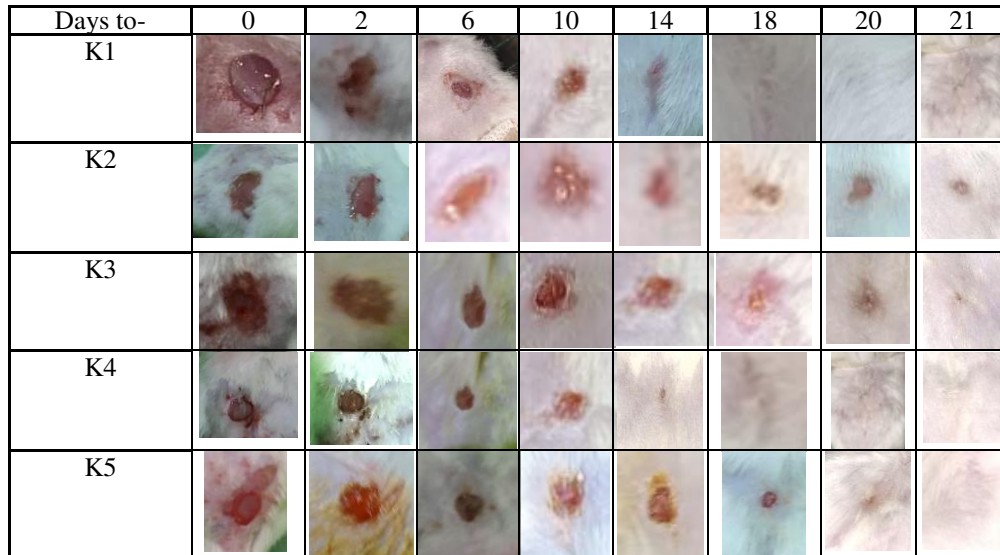
Ethanol extract of pineapple peel has antibacterial activity that falls into the weak category in inhibiting the growth of *Staphylococcus aureus* bacteria. In this study, the average value of the diameter of the inhibition zone formed at concentrations of

10%, 20%, and 30% was 0.48 mm, 1.05 mm, 0.85 mm, respectively, and the negative control did not form an inhibition zone so it did not have an average, and the positive control had an average of 16.34 mm.

#### **Test Results of the Effectiveness of Pineapple Peel Extract Hydrogel Patch Preparation in Healing Diabetic Ulcers in Test Animals**

The healing process of diabetic ulcers in test animals treated with the pineapple peel extract hydrogel patch showed promising results over the course of the study. On the first day, the skin around the wound treated with the pineapple peel extract hydrogel patch showed typical signs of inflammation, namely redness and discharge. This shows that an inflammatory process occurs which indicates increased blood flow and immune cell activity in response to injury (Andriyono Ilham Reandy, 2019). Furthermore, on the 6th day the redness around the wound was still clearly visible. However, when entering the

10th day, the wound begins to dry out and a thin layer forms which indicates the proliferation process of forming new tissue to cover the wound. This outcome is likely due to the moist environment provided by the hydrogel, the proteolytic activity of bromelain, and the antioxidant properties of the compounds in the pineapple peel extract, which contributed to the accelerated healing of the diabetic ulcer.



**Figure 1. Evaluation of wound healing**

Description: K1: group 1 as positive control with *hydrocolloid wound dressing*; K2: group 2 as negative control with formula without extract; K3: group 3 with *hydrogel patch 10% pineapple peel extract*; K4: group 4 with *hydrogel patch 20% pineapple peel extract*; K5: group 5 with *hydrogel patch 30% pineapple peel extract*

In the results of observations on days 6 to 14, the wound closure process was clearly visible,

especially in group 1 and group 4. In the negative control, the wound had not completely closed on day 21, but the wound closure process was still occurring. From measuring the diameter of the wound, the

percentage of wound closure is then calculated using the formula:

$$\text{Wound closure percentage} = \frac{\text{Initial wound area} - \text{Final wound area}}{\text{Initial wound areal}} \times 100\%$$

(Handayani et al., 2015)

**Table 4. Percentage of Wound Closure in Test Animals (units%)**

Days to	Group (K)				
	K 1	K2	K3	K4	K 5
2	3.68 ± 0.58	7.03 ± 2.47	3.01±3.17	7.03 ± 5.84	2.09 ± 1.6
4	19.14 ± 8.51	20.52±10.10	21.05±5.97	25.77±20.38	17.24 ± 13.80
6	36.17±16.89	42.78±20.9	57.47±12.74	54.74±8.95	54.00±6.76
8	53.21±15.17	54.74±17.57	60.67±7.94	67.90±8.05	59.92±5.98
10	64.64±15.6	51.89±19.74	67.40±8.39	72.96±9.30	70.37±2.86
12	80.98±21.98	70.87±5.25	70.61 ± 10.08	80.54±13.22	70.46±11.24
14	87.89±15.33	80.20±6.4	76.60±11.24	85.22±10.23	84.71±17.92
16	94.26±11.47	64.87±25.35	76.30±19.34	100±0	84.57±20.49
18	100±0	95.60±8.78	88.35±14.94	100±0	95.64±8.7
20	100±0	94.67±10.66	95.47±9.05	100±0	100±0
21	100±0	95.63±8.73	100±0	100±0	100±0

In testing the effectiveness of the pineapple peel extract hydrogel patch preparation on

test animals with diabetic ulcers, it showed that there was a difference in wound closure

time. On the 8th day, the percentage of diabetic ulcer wound closure in group 4 reached 69.5%, significantly greater than the positive group with a percentage of 58.2%. Meanwhile, the negative control experienced

a decrease in percentage, this could be due to the condition of the ulcer becoming more extensive. The percentage of closure of the diameter of diabetic ulcers reaches 100% on days 16 to 21.

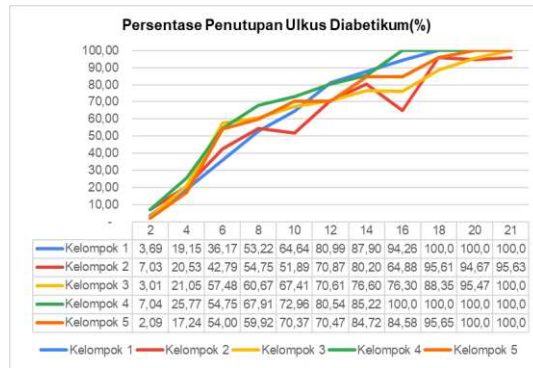


Figure 2. Diabetic ulcer wound closure chart

The results showed that group 4 had the fastest healing process compared to all other groups. A decrease in wound diameter was observed in all groups, including the negative control group, which was given a hydrogel patch without pineapple peel extract. Overall, using pineapple peel extract hydrogel patches as a wound dressing increased the percentage of diabetic ulcer closure. The hydrogel patch with 20% extract provided the best results, outperforming the positive control, a market hydrocolloid dressing. Hydrocolloid dressings were chosen as the positive control due to their similar physical properties to hydrogel patches and their common use in diabetic ulcer treatment.

Wound diameter closure data on day 16 was tested for normality using the Shapiro-Wilk test obtained  $p > 0.05$  so that it can be stated that the data is normally distributed, then a homogeneity test was carried out with the leneve method obtained the result  $p = 0.61$  ( $p > 0.05$ ) so it can be concluded that the data obtained is

homogeneous. From these two tests the data is declared normally distributed and homogeneous so that it can be continued with the one way anova test to analyze the average difference of grouped data.

In the one way anova test, the results obtained were  $p = 0.573$  ( $p > 0.05$ ) so it can be concluded that there is no difference in mean values between test groups. In descriptive observations, it was found that the application of pineapple peel extract hydrogel patches had a trend of decreasing wound diameter in mice with diabetic ulcer.

#### 4. Conclusion

Based on the results of phytochemical screening, pineapple peel extract is positive for tannins, saponins, flavonoids, terpenoids, phenolics and alkaloids. The antibacterial activity of pineapple peel extract with concentrations of 10%, 20%, and 30% against *S.aureus* is classified as weak with inhibition of 0.48; 1.05; and 0.85 mm respectively with 20% concentration superior to other

concentrations. In the patch characteristic test of pineapple peel extract hydrogel, it was found that formula 0 and formula 1 were more stable than the other formulas. In the effectiveness test of pineapple peel extract hydrogel patches on test animals, it was found that group 4 with the administration of hydrogel patches containing pineapple peel extract by 20% achieved the fastest percentage of diabetic ulcer closure compared to other treatment groups. Descriptive tests showed that there was a trend of decreasing the diameter of diabetic ulcers in test animals given pineapple peel extract hydrogel patches. It can be concluded that pineapple peel extract contains secondary metabolites that have the potential for wound closure. Giving hydrogel patches containing pineapple peel extract by 20% effectively accelerates diabetic ulcer wound closure in test animals.

## 5. Bibliography

- Andriyono Ilham Reandy. (2019). *Kaempferia galanga* L. sebagai Anti-Inflamasi dan Analgetik. *Jurnal Kesehatan*, 10(3), 495–502.
- Angriani, S., Hariani, H., & Dwianti, U. (2019). The Effectivity of Modern Dressing Wound Care with Moist Wound Healing Method in Diabetic Ulcer at Wound Care Clinic of ETN Centre Makassar. *Jurnal Media Keperawatan*, 10(1), 2087–2122.
- Azizah, S., & Qomariyah, N. (2021). Aktivitas Antidiabetik Ekstrak Daun Jambu Mete (*Anacardium occidentale* L.) terhadap Kadar Glukosa dan Penyembuhan Luka Ulkus Diabetikum pada Mencit (*Mus musculus*). *LenteraBio: Berkala Ilmiah Biologi*, 11(1), 15–25.
- Badan Pusat Statistik Indonesia. 2023. Produksi Tanaman Buah-buahan, 2021-2022. URL: <https://www.bps.go.id/id/statistics-table/2/NjIjMg%3D%3D/produksi-tanaman-buah-buahan.html>. Diakses pada 14 Februari 2024.
- Base, N. H., A. Tenriugi Daeng Pine, Yusriyani, Raymond Arief N Noena, & Taufiq. (2023). Pemanfaatan Limbah Kulit Buah Nanas (*Ananas Comosus*) Sebagai Minuman Fermentasi Yang Menyehatkan. *Jurnal Pengabdian Masyarakat Yamasi*, 2(1), 16–21.
- Golmohammadi, R., Najar-Peerayeh, S., Tohidi Moghadam, T., & Hosseini, S. M. J. (2020). Synergistic Antibacterial Activity and Wound Healing Properties of Selenium-Chitosan-Mupirocin Nanohybrid System: An in Vivo Study on Rat Diabetic Staphylococcus aureus Wound Infection Model. *Scientific Reports*, 10(1), 1–10.
- Handayani, F., Siswanto, E., & Ayu Trisna Pangesti Akademi Farmasi Samarinda, L. (2015). Uji Aktivitas Ekstrak Etanol Gambir (*Uncaria gambir* Roxb.) Terhadap Penyembuhan Luka Tikus Putih Jantan (*Mus musculus*). *Jurnal Ilmiah Manuntung*, 1(2), 133–139.
- Hanistya, R., & Samlan, K. (2021). Formulasi Dan Karakteristik Fisik Sediaan Plester Hidrogel Ekstrak Daun Ciplukan (*Physalis angulata* L.) Dan Batang Kayu Manis (*Cinnamomum burmannii*). *The Journal of Muhammadiyah Medical Laboratory Technologist*, 4(2), 201.
- Harliantika, Y., & Noval, N. (2021). Formulasi dan Evaluasi Hidrogel Ekstrak Etanol Daun Gaharu (*Aquilaria malacensis* Lamk.) dengan Kombinasi Basis Karbopol 940 dan HPMC K4M

- (Formulation and Evaluation Hydrogel of Agarwood Leaf (*Aquilaria malacensis* Lamk.) Extract Ethanol with Combination Ca. *Journal of Pharmaceutical Care Anwar Medika*, 3(2), 55–70.
- Haryanto, H., Sutandi, A., Kusumawati, E., Nurhayati, S., Fitri, F. M., Nafsi, G., & Nuraeni, S. W. (2023). Potential of Therapeutic *Curculigo latifolia* Extracts on Alloxan-induced Diabetes in a Male *Mus musculus*. *Biosaintifika*, 15(3), 370–377.
- Kementerian Kesehatan RI. 2017. Farmakope Herbal Indonesia Edisi II. Jakarta: Kementerian Kesehatan RI.
- Masykuroh, A., & Puspasari, H. (2022). Aktivitas Anti Bakteri Nano Partikel Perak (Npp) Hasil Biosintesis Menggunakan Ekstrak Keladi Sarawak *Alocasia Macrorrhizost* terhadap *Staphylococcus Aureus* Dan *Escherichia Coli*. *Bioma : Jurnal Biologi Makassar*, 7(1), 76–85.
- Mustika, Jaluri, P. D. C., & Lovianie, M. M. (2020). Pengaruh Pemberian Sediaan Emulgel-Kitosan Ekstrak Kulit Buah Pisang Ambon (*Musa Paradisiaca* L.) untuk Penyembuhan Luka Bakar Pada Kelinci. *Jurnal Borneo Cendekia Medika*, 11, 1–10.
- Novita, W. (2016). 2016. Uji Aktivitas Antibakteri Fraksi Daun Sirih (*Piper Betle* L) Terhadap Pertumbuhan Bakteri *Streptococcus Mutans* Secara In Vitro. *Jambi Medical Journal*. 4(2):40-155..
- Omorotionmwan, F. O.-O., Ogwu, H. I., & Ogwu, M. C. (2019). Antibacterial Characteristics And Bacteria Composition Of Pineapple (*Ananas Comosus* [Linn.] Merr.) Peel And Pulp. *Food and Health*, July, 1–11.
- Rathnavelu, V., Alitheen, N. B., Sohila, S., Kanagesan, S., & Ramesh, R. (2016). Potential role of bromelain in clinical and therapeutic applications (Review). *Biomedical Reports*, 5(3), 283–288.
- Reiza, I. A., Rijai, L., & Mahmudah, F. (2019). Skrining Fitokimia Ekstrak Etanol Kulit Nanas (*Ananas comosus* (L.) Merr). *Proceeding of Mulawarman Pharmaceuticals Conferences*, 10, 104–108.  
<https://doi.org/10.25026/mpc.v10i1.371>
- Silverman, M., Lee, P. R., & Lydecker, M. (2023). Formularies. *Pills and the Public Purse*, 97–103.
- Sitepu, N., Rahman, A. O., & Puspasari, A. (2022). Efektivitas Antibakteri Ekstrak Kulit Kulit Nanas (*Ananas Comosus*) N-Heksana Terhadap Bakteri *Staphylococcus Aureus* Atcc 25923. *Journal of Medical Studies*, 2(1), 59–67.
- Syamsul, E. S., Anugerah, O., & Supriningrum, R. (2020). PENETAPAN Rendemen Ekstrak Daun Jambu Mawar (*Syzygium Jambos* L. Alston) Berdasarkan Variasi Konsentrasi Etanol Dengan Metode Maserasi. *Jurnal Riset Kefarmasian Indonesia*, 2(3), 147–157.