

Article

## RESULTS OF MEASURING LACTATE LEVELS VALUE IN FREE FLAP RECONSTRUCTION

Mufida Muzakkie<sup>1\*</sup>, & Karnissa Rizkia Adhania<sup>2</sup>

1. Plastic Reconstructive and Aesthetic Surgeon, Plastic Reconstructive and Aesthetic Surgery Division, Mohammad Hoesin Central General Hospital - Faculty of Medicine, Sriwijaya University, Palembang, Indonesia.
2. Program Study of Medical Education, Faculty of Medicine, Sriwijaya University, Palembang, Indonesia.

### ABSTRACT

**Introduction :** Free flap surgery which is performed by transferring tissue along with its vascularization, can fail due to vascular compromised which cause by thrombosis formation either in vein or artery. Disruption of blood flow patency that not treated immediately can cause ischemia and necrosis occurred in free flap, especially within five days after reconstruction. Previous study has proven that free flap monitoring with lactate levels measurement can accurately for evaluate the occurrence vascular compromised in free flap.

**Method :** This study is a descriptive observational study with cross-sectional design. It was conducted by observing medical record of free flap reconstruction patient from November 2022 until November 2023 at Plastic and Reconstructive Surgery Department of RSUP Dr. Mohammad Hoesin Palembang. Data collection was carried out using total sampling technique and analysed using Statistical Package for the Social Science (SPSS) version 22.0 with univariate technique.

**Result :** Free flap with vascular compromise has higher lactate levels value than viable one. Lactate levels value transition of viable free flap showed an increase after anastomosis and gradually decrease at the next assessment time, while lactate levels in free flap with vascular compromise increased to above reference value, mainly on the first day vascular compromise occurred.

**Conclusion:** Clinical monitoring which combined with lactate levels assessment can accelerate the diagnose of blood flow patency disruption in free flap so that cause success rate improvement and better prognosis of free flap reconstruction patients.

**Keywords:** Free flap monitoring method; Vascular compromise; Lactate

**Latar Belakang:** Operasi *free flap* yang dilakukan dengan memindahkan jaringan beserta vaskularisasinya dapat mengalami kegagalan akibat gangguan vaskular yang disebabkan oleh pembentukan trombosis, baik pada vena maupun arteri. Gangguan pada patensi aliran darah yang tidak segera ditangani dapat menyebabkan iskemia dan nekrosis pada *free flap*, terutama dalam lima hari setelah rekonstruksi. Penelitian sebelumnya telah membuktikan bahwa pemantauan *free flap* dengan pengukuran kadar laktat dapat secara akurat mengevaluasi terjadinya gangguan vaskular pada *free flap*.

**Metode:** Penelitian ini merupakan studi observasional deskriptif dengan desain *cross-sectional*. Penelitian dilakukan dengan mengamati rekam medis pasien rekonstruksi *free flap* dari November 2022 hingga November 2023 di Departemen Bedah Plastik dan Rekonstruksi RSUP Dr. Mohammad Hoesin Palembang. Pengumpulan data dilakukan dengan teknik total sampling dan dianalisis menggunakan perangkat lunak *Statistical Package for the Social Science* (SPSS) versi 22.0 dengan teknik *univariat*.

**Hasil:** *Free flap* dengan gangguan vaskular memiliki nilai kadar laktat yang lebih tinggi dibandingkan dengan flap yang masih hidup. Perubahan nilai kadar laktat pada *free flap* yang masih hidup menunjukkan peningkatan setelah anastomosis dan secara bertahap menurun pada waktu penilaian berikutnya, sedangkan kadar laktat pada *free flap* dengan gangguan vaskular meningkat di atas nilai referensi, terutama pada hari pertama terjadinya gangguan vaskular.

**Kesimpulan:** Pemantauan klinis yang dikombinasikan dengan penilaian kadar laktat dapat mempercepat diagnosis gangguan patensi aliran darah pada *free flap* sehingga meningkatkan tingkat keberhasilan dan prognosis yang lebih baik bagi pasien rekonstruksi *free flap*.

**Kata Kunci:** Free flap monitoring method; Vascular compromise; Lactate

#### Conflicts of Interest Statement:

The author(s) listed in this manuscript declare the absence of any conflict of interest on the subject matter or materials discussed.

Received: 11-03-2024, Revised: 11-08-2024, Accepted: 17-038-2024

Copyright by Muzakkie, M., & Adhania, K. R. (2024). | P-ISSN 2089-6492; E-ISSN 2089-9734 | DOI: 10.14228/jprjournal.v11i1.374  
 Published by Lingkar Studi Bedah Plastik Foundation. This is an open-access article distributed under the terms of the Creative Commons Attribution-Non Commercial-No Derivatives License 4.0 (CCBY-NC-ND), where it is permissible to download and share the work provided it is properly cited. The work cannot be changed in any way or used commercially without permission from the journal. This Article can be viewed at [www.jprjournal.com](http://www.jprjournal.com)

## INTRODUCTION

Free flap surgery is the highest level in defect closure reconstruction, and may compose from any type of tissue such as skin, muscle, and bone.<sup>1</sup> The aim of this surgery is to return function and repair anatomical structure of the defect so that can improve life quality of patients. Tissue transfer in free flap surgery is done along with its vascularization from one body site as a donor to defect in another site.<sup>2</sup> Therefore, the success rate of free flap transfer depends on blood flow that carrying oxygen through anastomosis location between donor and recipient site.<sup>1</sup>

Post-surgery failure of free flap mostly occurs within 24 hours after surgery due to thrombosis formation in blood vessels that supply it.<sup>1,2,3</sup> Ischemia and necrosis occurrence risk maybe increase within the first five days after surgery if that disruption of blood flow patency in free flap not treated immediately.<sup>4,5</sup> Early detection and immediate re-exploration of vascular compromised can improve success rate of free flap salvage surgery.<sup>3,6</sup>

Clinical monitoring by physical examination is gold standard for detecting thrombosis formation in post-surgery free flap.<sup>2,7</sup> This monitoring method usually need frequent assessment time, that is every hour on the first day and every two until four hours on second until third days after surgery.<sup>1,2,8</sup> However, clinical monitoring very depends on experience of expert who assess that free flap, low objectivity level, and lack of standardization.<sup>1,2,6,8,9</sup>

Free flap monitoring method should be objective, sensitive, accurate, non-invasive, easy to perform and to interpret, its assessment results are easy to record, sustainable, can be reused or reproduction, don't harm patient or free flap, and don't need expensive cost.<sup>2,10</sup> Objective monitoring method can provide same results of assessment without depending on clinician experience or expertise.<sup>7</sup> In addition, the need for frequent assessment may also decrease.<sup>1</sup>

Study conducted by Henault, et al. found that lactate levels measurement as free flap monitoring method with cut-off value of 6.4 mmol/L can assess blood flow patency disruption accurately which has sensitivity 98.5% and specificity 99.5%.<sup>11</sup> Therefore, the diagnose of

free flap vascularization disruption can accelerate by combining clinical monitoring and lactate levels measurement.<sup>4</sup>

## METHOD

This study is descriptive observational study with cross-sectional design. The aim of this study is to know lactate value comparison in free flap reconstruction patients at Dr. Mohammad Hoesin Central General Hospital Palembang from November 2022 until November 2023 which appropriate with inclusion and exclusion criteria.

Data collection was carried out using total sampling technique by observing medical record lactate level measurement and clinical monitoring results of free flap reconstruction patients. Data were analysed using Statistical Package for the Social Science (SPSS) version 22.0 and univariate technique. Ethical approval from faculty of medicine Sriwijaya University ethics committee declared that this study has been granted exempt status on 27 September 2023.

## RESULTS

The study consisted of 19 patients that divided into 15 patients with viable free flap, 3 patients with venous compromise, and 1 patient with arterial compromise. Information about patient characteristics is presented in Table 1. Free flap reconstruction was most commonly performed on patients with an age range of 19-44 years (47,4%) and male (63,2%). The majority of free flap reconstruction patients were diagnosed with benign tumour (11,1%) and malignancies (88,9%). Furthermore, other diagnoses in patients of this study include scalp defect that performed craniectomy due to electrical burn injury resulting cranium osteomyelitis, defect closure after colli contracture release, Parry-Romberg syndrome reconstruction, reconstruction of traumatic amputation of inferior labium oris, mandibular myxofibrosarcoma with colli contracture, defect after actinomyces excision, and post craniotomy defect due to SOL intracranial.

The type of free flap that most commonly used was anterolateral thigh free flap (ALT) (57,9%). Radial forearm free flap (31,6%), fibular

free flap (5,3%), and anteromedial free flap (5,3%) were used in reconstruction patients of this study. Free flaps with viable condition were the most common outcome at every assessment time. Furthermore, free flaps with venous compromise occurred more frequently than arterial compromise and all vascular compromise occurred primarily on first day after reconstruction.

**Table 1.** Patient's characteristics

Patient's characteristics	n	%
Age (years)		
0-5	0	0
6-10	0	0
11-18	3	15,8
19-44	9	47,4
45-59	6	31,6
≥60	1	5,3
Total	19	100,0
Sex		
Female	7	36,8
Male	12	63,2
Total	19	100,0
Diagnosis		
Tumour	9	47,4
Cranium osteomyelitis due to electrical burn	3	15,8
Defect after colli contracture release	1	5,3
Parry-Romberg syndrome reconstruction	1	5,3
Traumatic amputation of inferior labium oris	1	5,3
Mandibular myxofibrosarcoma with colli contracture	1	5,3
Defect after actinomycosis excision	2	10,5
Post craniotomy defect due to SOL intracranial	1	5,3
Total	19	100,0
Free Flaps Type		
Radial forearm free flap	6	31,6
Fibular free flap	1	5,3
Anterolateral thigh free flap	11	57,9

Patient's characteristics	n	%
Anteromedial thigh free flap	1	5,3
Total	19	100,0
Outcome		
Viable	15	78,9
Venous compromise	3	15,8
Arterial compromise	1	5,3
Total	19	100,0

Note: SOL= Space Occupying Lesion

Lactate levels was measured at several times: before ischemic time, after anastomosis, the first day, the third day, and the fifth day. Frequency distribution of lactate levels in viable free flaps divided based on the five measurement times. However, free flap with vascular compromise, its only divided into three measurement times: the first day, the third day, and the fifth day.

The results of lactate levels measurement on the first day are shown in Table 2. Viable free flaps and free flaps with venous compromise had lactate levels averages of 2.97 mmol/L and 7.33 mmol/L respectively. Lactate level on the first day couldn't be measured in free flap with arterial compromise due to total occlusion in its vascularization.

**Table 2.** Lactate levels of free flaps on the first day

Lactate levels (mmol/L)	Viable (n=15)	Arterial compromise (n=1)	Venous compromise (n=3)
Mean	2,97	-	7,33
Median	2,70	-	7,30
Standard Deviation	1,65	-	1,35
Minimum	1,20	-	6,00
Maximum	6,40	-	8,70

Lactate levels measurement results on the third day are shown in Table 3. Viable free flaps, free flap with arterial compromise, and free flaps with venous compromise had lactate levels averages of 2.25 mmol/L, 5.6 mmol/L, and 5 mmol/L, respectively. This shows that viable free flaps have a lower lactate average value than free flaps with vascular compromise. Moreover, free flap with arterial compromise has a higher lactate value compared to free flaps with venous compromise.

**Table 3.** Lactate levels of free flaps on the third day

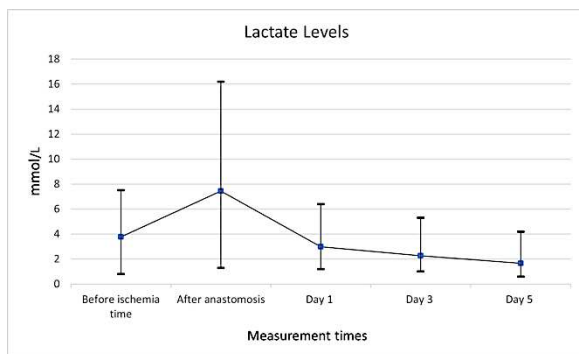
Lactate levels (mmol/L)	Viable (n=15)	Arterial compromise (n=1)	Venous compromise (n=3)
Mean	2,25	5,60	5,00
Median	2,10	5,60	5,20
Standard Deviation	1,34	0,00	2,61
Minimum	1,00	5,60	2,30
Maximum	5,30	5,60	7,50

The results of lactate levels measurement on the fifth day are shown in Table 4. Viable free flaps, free flap with arterial compromise, and free flaps with venous compromise had lactate levels averages of 1.67 mmol/L, 3.1 mmol/L, and 6.4 mmol/L, respectively. On the fifth day, lactate level average of free flap with arterial compromise decreased to be lower than that of the free flaps with venous compromise.

**Table 4.** Lactate levels of free flaps on the fifth day

Lactate levels (mmol/L)	Viable (n=15)	Arterial compromise (n=1)	Venous compromise (n=3)
Mean	1,67	3,10	6,40
Median	1,30	3,10	6,20
Standard Deviation	0,99	0,00	0,53
Minimum	0,60	3,10	6,00
Maximum	4,20	3,10	7,00

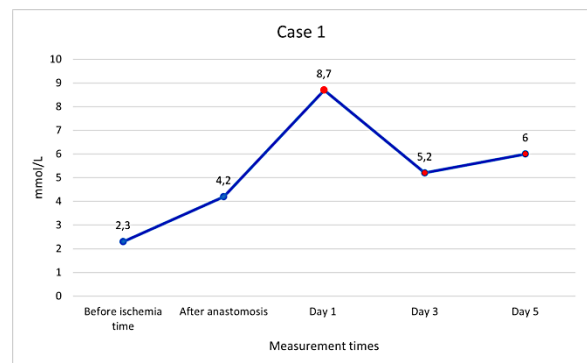
Lactate levels transition graph of viable free flaps presented in Figure 1. Lactate levels increased right after anastomosis. It subsequently decreased consistently at the following measurement times with more stable value.



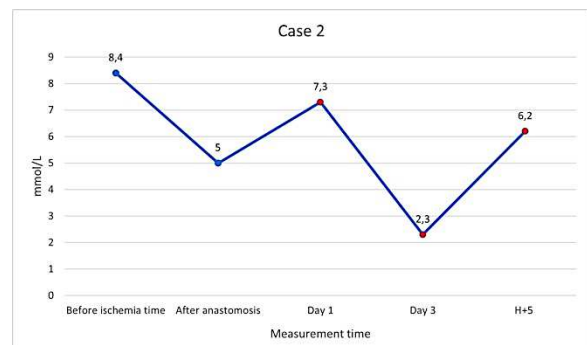
**Figure 1.** Lactate levels transition of viable free flap

The free flap with venous compromise in case 1 has a lactate level transition graph shown in Figure 2. Lactate level increased from 4.2

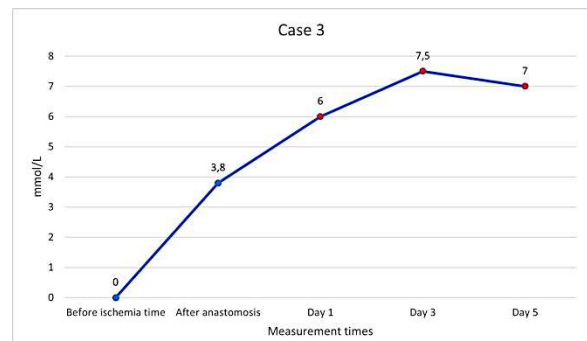mmol/L to 8.7 mmol/L on the first day of compromise. It then decreased on the third day and increased again on the fifth day. This pattern is also observed in the free flap with venous compromise in case 2 (Figure 3), where lactate level increased from 5 mmol/L to 7.3 mmol/L on the first day and decreased in third day. Meanwhile, free flap with venous compromise in case 3 (Figure 4) showed lactate level increasing on the first to third day and decreasing on the fifth day. All three cases showed an increase in lactate levels value, especially on the first day of compromise.



**Figure 2.** Lactate level transition in case 1 (venous compromise)

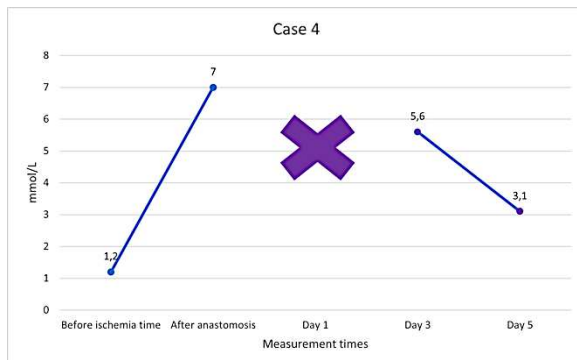

**Figure 3.** Lactate level transition in case 2 (venous compromise)



**Figure 4.** Lactate level transition in case 3 (venous compromise)

Lactate level transition of the free flap with arterial compromise in case 4 shown in Figure 5. On the first day, lactate level of the free flap couldn't measure due to total vascular occlusion. However, the lactate level after anastomosis extremely increased from 1.2 mmol/L to 7 mmol/L. It then decreased from 5.6 mmol/L to 3.1 mmol/L on the fifth day.



**Figure 5.** Lactate level transition in case 4 (arterial compromise)

## DISCUSSION

This study showed that viable free flaps had higher lactate level than free flaps with vascular compromise. Furthermore, free flap with arterial compromise exhibited higher lactate level compared to those with venous compromise. Ideally, the lactate levels comparison for each outcome should be based on the measurements taken on the the first day of compromise, as these results are not influenced by immediate treatment given. However, lactate level of free flap with arterial compromise on the first day couldn't be measured due to total occlusion of its blood vessel. Therefore, comparison of lactate levels in this study based on measurement results from the third day.

Similar results were obtained in the study conducted by Henault, et al. in 2014 compared to this study, indicating that lactate levels in viable free flaps were lower than the non-viable free flaps with average values of 2.6 mmol/L and 11.2 mmol/L, respectively.<sup>11</sup> The study conducted by Kishi, et al. found that the average lactate level values of viable free flap was 2.44 mmol/L, while in free flap with congestion, it was 9.18 mmol/L.<sup>7</sup> This shows that free flaps with vascular compromise have a higher lactate level value compared to viable free flaps. The study that analysed lactate level values in free flaps with arterial and venous compromise separately

couldn't be found until the conduct of this study. David, et al. conducted experiments on the pigs that had undergone free flap surgery by ligating the blood vessels of flap, and it was found that the lactate levels in free flaps where one artery was ligated were higher than in those where two veins were ligated. Each group had lactate levels of 18 mmol/L and 5.52 mmol/L, respectively.<sup>4</sup> Free flaps with venous compromise has experience partial anaerobic metabolism because oxygen is still supplied to the tissue through artery, resulting in lower lactate levels compared to free flaps with arterial compromise.<sup>10</sup>

Lactate levels transition graph of viable free flaps in this study exhibited an increase in values after anastomosis, even one patient experienced a drastic increase in lactate value that raising from 1.3 mmol/L to 16.2 mmol/L. Lactate levels began to decreased on the first day after surgery and continued to decrease consistently until the last measurement. Lactate levels were more stable on the third day and the values began to decrease below the reference value, which was cut-off value based on the study conducted by Henault, et al.<sup>11</sup> for diagnosing vascular compromise in free flaps ( $\geq 6.4$  mmol/L). Free flaps undergo transient anaerobic metabolism during ischemic time until after anastomosis because the oxygen that carried by blood to tissue is not adequate. Therefore, lactate levels increased after anastomosis as a result of this transient anaerobic metabolism.<sup>7</sup> The study conducted by Nikhar, et al. in 2023 indicated that no correlation could be found between the increase in systemic lactate levels and the failure of free flap surgery.<sup>12</sup> The result of that study indirectly showed that changes in systemic lactate levels didn't influence the lactate levels of free flaps. This led to a stable transition value of free flaps lactate levels.

Four cases of free flaps with vascular compromise were found in this study. Free flaps in cases 1,2, and 3 experienced venous compromise, while the free flap in case 4 showed arterial compromise. Compromise began in all free flap cases with an increase in lactate levels, surpassing the reference value in the first day after surgery. Hypoxia occurred in free flaps with vascular compromise due to a decrease of blood supply carrying oxygen to the tissue, causing a shift in the free flap metabolism from aerobic to anaerobic.<sup>7,9,10</sup> The change leads to an increase in lactate production as a result of anaerobic metabolism.<sup>7,10,13,14</sup>

## CONCLUSION

The measurement of lactate levels in free flaps with vascular compromise reveals higher values compared to viable free flaps. Furthermore, free flaps with venous compromise exhibit lower value than those with arterial compromise. Lactate level measurement in free flaps, which objective, easy to perform, doesn't require frequent measurements, and has an inexpensive cost, is suitable for combined use with clinical monitoring to accelerate the diagnosis of vascular compromise.

### Correspondence regarding this article should be addressed to:

Mufida Muzakkie. Plastic Reconstructive and Aesthetic Surgeon, Plastic Reconstructive and Aesthetic Surgery Division, Mohammad Hoesin Central General Hospital - Faculty of Medicine, Sriwijaya University, Palembang, Indonesia.. E-Mail: [mufida.muzakkie@gmail.com](mailto:mufida.muzakkie@gmail.com)

## REFERENCES

1. Moosa S, Dydynsky R. The Role of Artificial Intelligence in Predicting Flap Outcomes in Plastic Surgery: Protocol of a Systematic Review. *Undergrad Res Nat Clin Sci Technol URNCST J*. 2022 May 4;1-8.
2. Kohlert S, Quimby A, Saman M, Ducic Y. Postoperative Free-Flap Monitoring Techniques. *Semin Plast Surg*. 2019 Feb;33(01):013-6.
3. Ritschl L, Schmidt L, Fichter A, Hapfelmeier A, Kanatas A, Wolff KD, et al. Prediction of Flap Necrosis by Using Indocyanine Green Videoangiography in Cases of Venous Occlusion in the Epigastric Flap Model of the Rat. *J Reconstr Microsurg Open*. 2018 Jul;03(02):e62-9.
4. David G, Vivien M, Sarra C, Brice G, Anna H, Philippe R, et al. Monitoring of myocutaneous flaps by intracapillary glucose and lactate measurements: experimental study. *Clin Pract [Internet]*. 2017 [cited 2023 Jul 24];14(2). Available from: <http://www.openaccessjournals.com/articles/monitoring-of-myocutaneous-flaps-by-intracapillary-glucose-and-lactate-measurements-experimental-study.html>
5. Birkenfeld F, Naujokat H, Helmers AK, Purcz N, Möller B, Wiltfang J. Microdialysis in postoperative monitoring of microvascular free flaps: Experiences with a decision algorithm. *J Cranio-Maxillofac Surg*. 2019 Aug;47(8):1306-9.
6. Karakawa R, Yoshimatsu H, Narushima M, Iida T. Ratio of Blood Glucose Level Change Measurement for Flap Monitoring. *Plast Reconstr Surg - Glob Open*. 2018 Jul;6(7):e1851.
7. Kishi K, Ishida K, Makino Y, Miyawaki T. A Simple Way to Measure Glucose and Lactate Values During Free Flap Head and Neck Reconstruction Surgery. *J Oral Maxillofac Surg*. 2019 Jan;77(1):226.e1-226.e9.
8. Kääriäinen M, Halme E, Laranne J. Modern postoperative monitoring of free flaps. *Curr Opin Otolaryngol Head Neck Surg*. 2018 Aug;26(4):248-53.
9. Tachi K, Nakatsukasa S, Nakayama Y. Monitoring free flap venous congestion using continuous tissue glucose monitoring: A case report. *JPRAS Open*. 2018 Sep;17:49-53.
10. Handayani S. A Simple Method to Measure Serum Lactate Concentration as A Reliable Parameter to Detect Flaps Blood-flow Patency. *J Plast Reconstr [Internet]*. 2012 [cited 2023 Jul 24];1(4). Available from: <http://jprjournal.com/index.php/jpr/article/view/89>
11. Henault B, Pluvy I, Pauchot J, Sinna R, Labruère-Chazal C, Zwetyenga N. Capillary measurement of lactate and glucose for free flap monitoring. *Ann Chir Plast Esthét*. 2014 Feb;59(1):15-21.
12. Nikhar SA, Metta R, Nimmagadda R, Gopinath R. Does the systemic rise in serum lactate levels correlate to free flap failure in head and neck reconstructive surgeries—series of cases. *Ain-Shams J Anesthesiol*. 2023 Sep 12;15(1):73.
13. Rabinowitz JD, Enerbäck S. Lactate: the ugly duckling of energy metabolism. *Nat Metab*. 2020 Jul;2(7):566-71.
14. Setala L, Gudaviciene D. Glucose and Lactate Metabolism in Well-Perfused and Compromised Microvascular Flaps. *J Reconstr Microsurg*. 2013 Jun 11;29(08):505-10.