



SAFE SURGICAL PELVIC RING INJURY IN ELDERLY: A CASE REPORT

Nyoman Orthi Laksana¹

¹Orthopedics and Traumatology Hospital, Surabaya, Indonesia

ABSTRACT

In elderly, pelvic ring injury can happen in low energy trauma, thus can be a problem in mortality, with the additional risk and complications that caused by prolonged immobilization. The initial treatment prior to stabilize the hemodynamic and pelvic. The goal of the treatment for this problem is to minimize the further risk and complications. The surgical technique is minimal invasive technique (approach) that made less dissection and damage the structure, that allowed better healing, early mobilization and function. Case presentation 76 years old female, which sustained pelvic ring injury following fall from a height with her left hip bump to the floor. In the emergency department, there was a problem with the hemodynamic and already stabilized with balance fluid, blood transfusion and performed pelvic sling for pelvic stabilizer and then followed by surgery for six days later. After hemodynamic stabilization, the performing in both anterior stabilization with plate screw fixation by modified stoppa combined with minimal ilioinguinal approach and in the posterior stabilization by percutaneous screw technique. These technique allowed the access to the pelvic region with less sacrifice the structures which can induced more and other trauma. Otherwise it may also give better opportunity in recovery and minimized the risk and complications, such promoted early mobilization and less length of stay in the hospital. In elderly, pelvic ring injury is a fragile problem, with high risk of mortality and also might decrease in function. By proper treatment, less or minimize the approach, with combined open reduction internal fixation by modified stoppa, small ilioinguinal approach for anterior stabilization and with the less invasive percutaneous screw for posterior stabilization technique in surgery, the risk and complication might have decreased.

Keywords: Pelvic ring injury in elderly, modified stoppa, small ilioinguinal and percutaneous screw.



This is an open access article under the [CC-BY-SA](https://creativecommons.org/licenses/by-sa/4.0/) license.

Article History:

Submission : July 5th, 2021
Revision : July 18th, 2021
Accepted : December 19th, 2023

Corresponding Author:

Nyoman Orthi Laksana
Orthopedics and Traumatology Hospital, Surabaya,
Indonesia
Nyomanorthilaksana@gmail.com

INTRODUCTION

Pelvic ring injury occurs relatively rare in elderly, it's account for about 1-3% of all injury and most cases require a hospital treatment. The incidence commonly because of fall from height or traffic accident with a mild or as a high energy trauma and may be presented a significant problem in morbidity and mortality (1). A very important mandatory to treat the initial management is to begin with assessment and treat the hemodynamic stabilization, especially in the unstable pelvic ring injury and immediated to performed pelvic stabilization, as an initial fixation. After restored and already maintained in stable condition, the definitive surgery for the pelvic region can be performed that usually done in up to seven days. In this case with the anteroposterior stabilization, with less or minimal invasive technique of surgery, the blood loss and further damaging soft tissue exposure can be minimized. Biomechanically, it is very important to perform the stable in fixation or reconstruction, that can be done with both in the anterior and posterior approaches (1).

PRESENTATION OF CASE

Female, 76 years old, who had sustained pelvic ring injury following fall from a height with her left hip bump to the floor. When she arrived in the emergency department, there was a problem in the hemodynamic and already performed resuscitation with balance of fluid, blood transfusion and pelvic sling to stabilize the caused of blood lost and to reduce the pain. After the stabilization, the hemodynamic is stable and pain subsides and followed by internal

fixation six days later. The technique was performing both accesses, the anterior and posterior of the pelvic regions with the minimal or less invasive technique, allowed to stabilize the fractures sites and very important reduced the risk and complications. This allowed early mobilization and less time staying in the hospital.

DISCUSSION

A pelvic ring injury with combined lateral and vertical force was detected on the radiography while the blood pressure began to decreased, and pelvic sling applied urgently. In this case by precise in clinical finding (primary survey), it's very important performing a pelvic stabilization before the hemodynamic become unstable. The management of pelvic ring injuries should be treated in multi disciplines, most important in elderly patient that physiologically is less tolerant trauma and bleeding, the healing and function. The surgeons should prepare for all the important considerations from the initial management. Hypovolemic shock caused by the bleeding is a major factor to the mortality in the pelvic ring injuries. The sources of the bleeding include the intra pelvic problem in venous plexus, arteries, and cancellous bone. In this case, the vital sign can be diminished and considered with some other combined other factors such comorbid that created shock in this patient (1).

Percutaneous screw fixation for the left posterior Sacroiliac joint After the initial hemodynamic stabilization and pelvic sling, then performed posterior stabilization with minimal invasive

technique with percutaneous screw fixation. Using a canulated screw and fixed the left sacroiliac joint. Percutaneous fixation of unstable posterior pelvic ring injuries shows better results and fewer complications if compared to open technique of fixation (4). Most reported complications with percutaneous fixation are nerve root injury, screw misplacement, and loss of reduction. The extended approach has disadvantages which are the length of the incision is enlarged, soft tissue is more extensive, the longer time in operation, more bleeding or blood loss and the risk of infection increase. The percutaneous screw in stabilizing of the pelvic ring injury has an advantage that can avoid extensile surgical damage. The important considerations are to minimize risk and complication in the region of pelvic, the general condition of the patient and improve the time of healing with early mobilization (5,8).

The Iliosacral screw fixation needs an image as a guidance to lead in the percutaneous fixation procedure's (the inlet, outlet, AP and lateral view). The anatomic reduction should be achieved. First, should identify the sacral foramina in outlet view, the spinal canal in the inlet view and the S1 body (with location S1 nerve root tunnel). The landmark for true sacral image with the lateral projection, start with body of S1 and the iliac cortical density, then make an entry point for the screw that should be anterior to S1 and inferior to the iliac cortical density, that parallel to the allar of sacrum, usually inferior and posterior. This safe zone is to avoid the anterosuperior border that can injure the L5 nerve root if penetrates by the screw. The small incision (stab) at the

identified site, with blunt dissection to the bone, make a save passage for the drill sleeve, guide by the image at inlet-outlet, and lateral view, the inserted the measured screw (partially threaded) with washer (at first safe guide by wire). The screw must be not too tight or excessive because the porotic bone usually occurs in elderly patient. Finally, with image the fixation of the percutaneous screw is acceptable (10).

It was found in the present study that the best internal fixation method for fixing posterior pelvic ring injury is the modified triangular osteosynthesis approach, followed by S1 screw fixation (Figure 1.). A study showed that an additional second screw for posterior fixation did not give any significant different at the functional outcome. This study provides guidance on the selection of fixation methods for posterior pelvic ring injury (5,9).

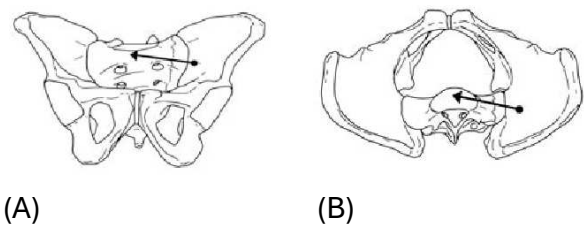


Figure 1. (A) Percutaneous screw fixation, left is the AP view. (B) right is the coronal view in the posterior with stabilization by percutaneous screw technique.

Open reduction and internal fixation for anterior pelvic region compared to external fixation, open reduction and internal fixation may have a better result, with the superior biomechanical stability, and allows earlier immobilization. The indications for ORIF are symphyseal widening (>2.5 cm), tilt fracture that is difficult to close in reduction, SI joint

dislocation, iliac fracture, unstable acetabular fracture, and in conjunction with laparotomy in the absence of fecal or urinary contamination. Patient is on the supine position that appropriate for the modified stoppa and lateral window (3,4). The anterior structure of the pelvis is accessed with the modified Stoppa, additional lateral window (extend of the approach is depending on the severity of injuries with necessary exposure). With the modified stoppa, begin with the Pfannenstiel incision above the pubic symphysis, subcutaneous, fascia incised longitudinal, the rectus muscle is divided and retracted laterally with the medial part detached from the upper part of the symphysis, the upper border pubic rami are blunt dissection and carried laterally along in the pelvic brim.

Along the medial surface, careful dissection must avoid injuring the corona mortis (an anastomosis between the external iliac and obturator arteries) that can be ligated, the periosteum continues dissected laterally along the pubic bone, expose and identify the fractures. Continue with the additional lateral window, a curved incision from the posterior gluteus medius and extend to ASIS (small incision that allows to place the plate conjunction to anterior part of the pelvic along the ilium at the iliopectineal site), this should be aware of the lateral femoral cutaneous nerve. With image guidance, reduction of the bone is performed and allowed made an access for the curve plate and fixed by placing the plate and screws that be placed in the anterior and lateral part (Bridging) (3,7). The Modified Stoppa combined with lateral window can significantly shorten operative

time and may decrease blood loss (Figure 2.) (3,4).

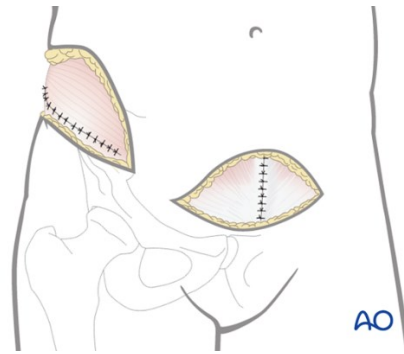


Figure 2. The Ilioinguinal approach, Modified Stoppa approach (AO)

CONCLUSIONS

In elderly, pelvic ring injury is a fragile problem, with high risk in morbidity and mortality rate. By proper initial and definitive treatment, the minimal invasive modified stopper at the anterior continue with small lateral ilioinguinal approach that fixed with plate and screw. Then for the posterior performed percutaneous screwing technique in surgery. This technique provides less trauma that can avoid more extensive damage, and so far with better in result compared with other open technique Tod reduced the risk and complications. The outcome may give a better opportunity in recovery by early mobilization and less time of stay in the hospital.

REFERENCES

1. Kim, B.S., Oh, J.K., Cho, J.W., Yeo, D.H., Cho, J.M. Minimally Invasive Stabilization with Percutaneous Screws Fixation of APC-3 Pelvic Ring Injury. *Journal of Trauma and Injury*. 2019;32(1): 60-65

2. Wu, H., Zhang, L.J., Guo, X.M., Jiang, X.J. Meta-analysis of Modified Stoppa Approach in Anterior Pelvic Ring and Acetabular Fractures. *Medicine*. 2020; 99(4):p e 18395
3. Mahmood, K., Darshan, M.S., Maley, D.K., Delair, A.I., Baig, R. A Meta Analysis of Modified Stoppa pproach and Ilioinguinal Approach in Open Reduction and Internal Fixation of Pelviacetabular Fractures. *Int J Orthop Sci* 2020;6(3):832-837
4. Zaki, M.E., Hadhood, M.M., Ayoub, M.A., El Sawy, A.M., El Agroudy, E.E. Open Versus Percutaneous Fixation of Unstable Posterior Pelvic Ring Injuries. 2019;32(2):640-645
5. Lu, Y., He, Y., Li, W., Yang, Z., Peng, R., Li, Y. Comparison of Biomechanical Performance of Five Different Treatment Approaches for Fixing Posterior Pelvic Ring Injury. *Journal of Healthcare Engineering* 2020; Vol 2020 Article ID 5379593
6. Cole, P.A., Dyskin, E.A., Gilbertson, J.A. Minimally invasive Fixation for Anterior Pelvic Ring Disruptions. *Injury*.2015 Sep; 46 Suppl 3:S27-34
7. Ferguson, T., Forward, D., Buckley, R. Modified Stoppa Technique, Approach, Open Reduction Internal Fixation. [online] surgeryreferenve.aofoundation.org. Available at <<http://surgeryreference.aofoundation.org/orthopaedic-trauma/adult-trauma/acetabulum/anterior-column/orif-through-modified-stoppa-approach>> [Accessed 7 June 2021]
8. Iorio, J.A., Jakoi, A.M., Rehman, S., Percutaneous Sacroiliac Screw Fixation of the Posterior Pelvic Ring. *Orthop Clin North Am*. 2015 Oct;46(4):511-21
9. Khaled, S.A., Soliman, A., Wahed M.A. Functional Outcome of Unstable Pelvic Ring Injuries after Iliosacral Screw Fixation: Single versus Two Screw Fixation. *Eur J Trauma Emerg Surg* 2015 Aug;41(4):387-92
10. Banerjee, R., Brink, P., Cimerman, M., Pohlemann, T., Tomazevic, M., Trafton, P., Iliosacral Screw for SI Joint. [Online] Surgeryreference.aofoundation.org. Available at: <http://surgeryreference.aofoundation.org/orthopedic-trauma/pelvic-ring/basic-technique/iliosacral-screw-for-for-si-joint?searchurl=%2fSearchResults#introduction> [Accessed 7 June 2021]