



Pengaruh Ekstrak Floret Pisang Raja Terhadap Gambaran Histopatologi Lambung : Analisis pada Tikus Wistar yang Diberi Etanol

Effect of Plantain Floret Extract on Gastric Histopathology: Analysis on Ethanol Given-Wistar Rats

Firda Athaya Nadhirah¹, Dyah Mustika Nugraheni¹, Rina Purnamasari¹

¹Medical Faculty of University of Muhammadiyah Semarang

Correspondence email: firda.athaya.fa@gmail.com

KATA KUNCI KEYWORDS

Ekstrak floret pisang, etanol, histopatologi lambung
banana floret extract; ethanol; gastric histopathology

ABSTRAK

Latar belakang: Konsumsi alkohol dapat menyebabkan kerusakan pada mukosa lambung. *Floret* pisang raja memiliki sifat antioksidan yang dapat mencegah kerusakan sel-sel lambung. Penelitian ini bertujuan untuk mengetahui pengaruh ekstrak *floret* pisang raja terhadap gambaran histopatologi lambung tikus wistar yang diberi etanol 40%. **Metode:** Penelitian ini menggunakan metode Post-test only group design. Sampel terdiri dari 30 ekor tikus wistar jantan yang dibagi menjadi 5 kelompok yaitu K- diberi makan dan minum standar, kelompok K+ diberi aquadest plasebo 1,8ml/200g/hari setelah 60 menit diberi etanol 40% 1,8ml/200g/hari, kelompok P1, P2, dan P3 diberi ekstrak *floret* dengan dosis (140mg/kg BB, 280mg/kg BB, dan 560mg/kg BB) dan setelah 60 menit diberi etanol 40%. Perlakuan dilakukan selama 30 hari, kemudian sampel dihentikan untuk diamati perbesaran mikroskopis histopatologis 400x dan dianalisis dengan kriteria *Barthel-Manja*. Data dianalisis menggunakan *Kruskal Wallis* dan *Mann Whitney*. **Hasil:** Rerata kerusakan mukosa lambung pada kelompok K-, K+, P1, P2, dan P3 berturut-turut adalah 1,03±0,26, 1,46±0,27, 1,40±0,56, 1,46±0,32, 1,83±0,26. Hasil uji *Kruskal Wallis* menunjukkan perbedaan yang signifikan ($p=0,02$). Hasil uji *Mann Whitney* menunjukkan perbedaan yang nyata pada kelompok K- dan K+, K+, dan P3, sedangkan pada kelompok K+ dan P1, P2 tidak menunjukkan signifikansi. **Kesimpulan:** Dosis 140mg/kg BB, 280mg/kg BB, dan 560mg/kg BB tidak dapat mencegah kerusakan lambung tikus Wistar yang diberi etanol 40%.

ABSTRACT

Introduction: Alcohol consumption can cause damage to the gastric mucosa. *Floret* plantain has antioxidant properties that can prevent damage to stomach cells. This study aims to find out the effect of *floret*

extract of plantain on the histopathological features of Wistar rat's stomach given ethanol 40%. **Methods:** This study used the Post-test only group design method. The sample consists of 30 male Wistar rats were divided into 5 groups namely C- was given food and drink standardly, group C+ was given a placebo aquadest 1.8ml/200g/day after 60 minutes given 40% ethanol of 1.8ml/200g/day, group T1, T2, and T3 were given floret extract at a dose (140mg/kg body weight, 280mg/kg body weight and 560mg/kg body weight) and after 60 minutes was given 40% ethanol. The treatment was carried out for 30 days, and then the samples were terminated in order to observe the histopathological microscopically magnification 400x and analyzed with Barthel-Manja criteria. Data were analyzed using Kruskal Wallis and Mann Whitney. **Results:** The mean of gastric mucosal damage in the C-, C+, T1, T2, and T3 were groups respectively 1.03 ± 0.26 , 1.46 ± 0.27 , 1.40 ± 0.56 , 1.46 ± 0.32 , 1.83 ± 0.26 . The Kruskal Wallis test results showed significant differences ($p=0.02$). The Mann Whitney test results showed significant differences in group C- and C+, C+, and T3, while the C+ and T1, T2 showed no significance. **Conclusions:** Dosing 140mg/kg body weight, 280mg/kg body weight and 560mg/kg body weight were unable to prevent stomach damage to Wistar rats given 40% ethanol.

INTRODUCTION

Based on the Global Status Report on Alcohol and Health 2018, about 2,088,800 people of Indonesian experienced health problems due to alcohol consumption. Alcohol can damage the stomach by increasing the permeability of the gastric barrier, resulting in the re-diffusion of HCL and pepsin into the gastric tissue (Yu *et al.*, 2014 ; Purbaningsih, 2020).

Ethanol is also metabolized to acetaldehyde, which is then converted into acetate with the help of ALDH. ALDH can be found in gastric cells. If ALDH does not function properly, acetaldehyde will produce a lot of ROS (Irramah, 2017). Increased ROS can cause oxidative stress. Under conditions of oxidative stress, antioxidant supplementation is required using floret plantain extract (*Musa X Paradisiaca var Raja*), which has the potential to scavenge free radicals

because it has antioxidants derived from saponins, phenols, flavonoids and tannins. This study aims to find out the potential of the floret extract of plantain (*Musa x Paradisiaca*) to prevent gastric damage of Wistar rats exposed to 40% ethanol.

METHODS

This research was conducted at the Biology Laboratory of the Faculty of Mathematics and Natural Sciences, Semarang State University, Roemani Hospital Semarang, and the Biomedical Laboratory of the Faculty of Medicine, University of Muhammadiyah Semarang. The type of research is true experimental with post-test only control group design conducted on male Wistar rats aged 8-12 weeks, weighing 150-200 grams, and healthy (active motion, thick white fur, clear eyes, and agile). Mice were obtained from the Biology laboratory of the State

University of Semarang. The sample consisted of 30 male Wistar rats which were divided into 5 groups randomly. The group consisted of C- fed ad libitum, C+ given placebo aquadest 1.8ml/200g/day 60 minutes apart given 40% ethanol dose 1.8ml/200g/day, T1 was given *floret* extract 140mg/kgBW rats at 60 minutes interval of 40% ethanol at a dose of 1.8ml/200g/day, T2 was given *floret* extract 280mg/kgBW rats 60 minutes was given 40% ethanol, and T3 was given *floret* extract 560mg/kgBW of rats at 60 minutes of administration of 40% ethanol. The treatment was for 30 days, then the rats were terminated on the 31st day and the gastric organ samples were taken from the Wistar rats, then histological preparations were made using the paraffin block method with Hematoxylin-eosin (HE) staining. Observation of the histopathological description of the stomach of Wistar rats was carried out using a trinocular microscope with a magnification of 400x in 5 fields of view of each sample of the stomach of Wistar rats. Observations were carried out by a specialist in Anatomical Pathology. Assessing the score of gastric mucosal damage using the Barthel-Manja criteria. The average degree of gastric mucosal damage was analyzed using the Kruskal Wallis and Mann Whitney test.

Plantain *florets* in this study used *florets* that were undamaged and free from pests. The *florets* were obtained from Gondang Village, Cepiring District, Kendal Regency with a dry weight of 400 g. The dried *florets* are ground with a grinding machine until smooth. *Floret* powder was macerated using 96% ethanol in a ratio of 1:5 for 48 hours.⁶ The next step was filtering

using Whatman No. paper. 40. The filtering results were concentrated with a rotatory evaporator at a temperature of 45°C to obtain a thick extract of 40 g. The next stage of the plantain *floret* extract was to carry out phytochemical tests with qualitative tests and quantitative tests at the Biology Laboratory, Faculty of Mathematics and Natural Sciences, Semarang State University.

This research was conducted after the issuance of ethical clearance obtained from the Health and Medical Research Ethics Commission of the University of Muhammadiyah Semarang with issue number 002/EC/FK/2021 and the researchers met the ethical standards of animal research.

RESULTS

The results of the extraction of *floret* powder of plantains were taken as much as 400 grams mixed with 96% ethanol to produce a thick extract of 40 grams. After doing a qualitative phytochemical test, the content was found in (Table 1), while the quantitative test found that the dominant content of the extract was quercetin as much as 0.4098mg.

The results of the study on the effect of *floret* extract on the gastric histopathological picture of Wistar rats which were then induced by 40% ethanol are shown in (Table 2). Observational data in the form of the average value of damage from each group which is divided into a score of damage to the integrity of the gastric mucosa.⁷ The score of mucosal damage using the Barthel Manja index is a score of 0: no pathological changes, score 1: epithelial desquamation, score 2:

erosion of the epithelial surface, score 3:
 epithelial ulceration.

Table 1. Results of analysis of phytochemical levels of plantain *floret* extract

| No | Test Parameters | Results | Description |
|----|-----------------|---------|---|
| 1 | Saponins | - | No foam was formed which did not disappear for more than 1 minute |
| 2 | Tannin | - | No greenish black color is formed |
| 3 | Alkaloids | + | Form a white precipitate |
| 4 | Phenolic | - | No green - purple color is formed |
| 5 | Terpenoid | + | Red/ pink color is formed |
| 6 | Steroid | + | Blue/green color is formed |
| 7 | Flavonoida | + | Red color is formed |

Table 2. The mean and different test scores for the average gastric mucosal damage.

| Group | Mean ± SD | Kruskal Wallis | Mann Whitney | | | |
|-------|-------------|----------------|--------------|-------|--------|--------|
| | | | K- | P1 | P2 | P3 |
| K- | 1,03 ± 0,26 | 0,02* | 0,022* | 0,19 | 0,046* | 0,003* |
| K+ | 1,46 ± 0,27 | | - | 0,806 | 0,935 | 0,04* |
| P1 | 1,40 ± 0,56 | | - | - | 1 | 0,141 |
| P2 | 1,46 ± 0,32 | | - | - | - | 0,056 |
| P3 | 1,83 ± 0,26 | | - | - | - | - |

Saphiro Wilk's normality test obtained $p < 0.05$, so that the data was not normally distributed and the Levene homogeneity test obtained $p > 0.05$ so that the data was homogeneous. The degree of gastric mucosal damage in the five groups was further analyzed by the Kruskal Wallis test (Table 2). The results of statistical calculations using the Kruskal Wallis test showed significant differences from all groups with a p value of < 0.05 so that

the Mann Whitney test was continued to determine the mean between groups, the degree of damage to C- was significantly different with C+, T2, T3 and C+ significantly different with T3 with p value < 0.05 .

The results of microscopic examination are histopathological descriptions of the gastric mucosa of Wistar rats between groups with a magnification of 100x (Figure 1-5).

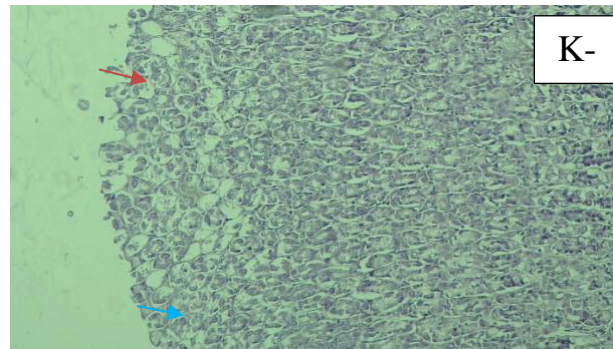


Figure 1. Histopathological description of the stomach of Wistar rats in the negative control group (C-), red arrows indicate epithelial desquamation and blue arrows indicate normal cells. (100x; H&E).

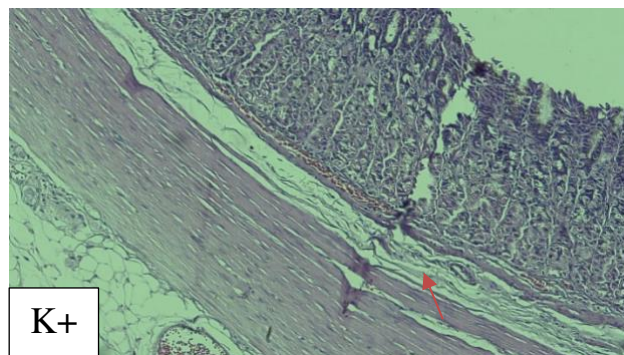


Figure 2. Histopathological description of the stomach of Wistar rats in the positive control group (C+), red arrows indicate epithelial ulceration. (100x; H&E).

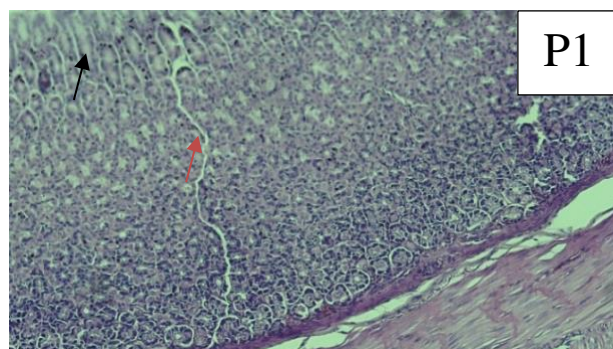


Figure 3. Histopathological description of the stomach of Wistar rats in treatment group 1 (T1), red arrows indicate epithelial erosion, black arrows indicate epithelial desquamation. (100x; H&E).

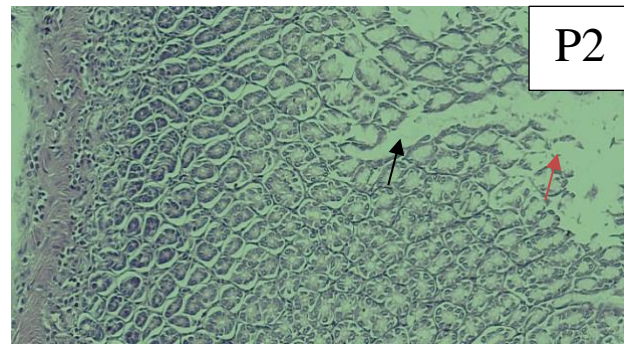


Figure 4. Histopathological description of the stomach of Wistar rats in treatment group 2 (T2), black arrows indicate epithelial erosion and red arrows indicate epithelial desquamation. (100x; H&E).

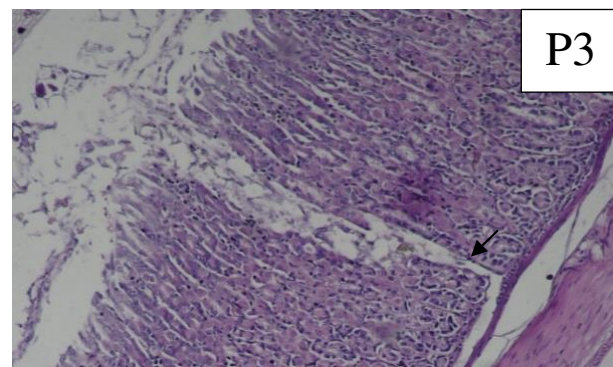


Figure 5. Histopathological description of the stomach of Wistar rats in treatment group 3 (T3), black arrows indicate epithelial ulceration. (100x; H&E).

DISCUSSION

The administration of plantain *floret* extract in this study made a difference in the gastric histopathological picture of Wistar rats given 40% ethanol at a dose of 1.8 ml/200g/day for 30 days. The results of this study showed significant differences in the C+, T2 and T3 groups with the C- group and the C+ with T3 groups. The degree of gastric mucosal damage in the T1 group was not significantly different from that in the C- group.

Comparison of the test of different mean degrees of gastric mucosal damage between the C (-) group and the C (+) group gave significantly different results. The group (C+) found epithelial desquamation, erosion until the damage reached epithelial ulceration. This is in accordance with the theory that the absorption of ethanol in the body causes one of the triggers for an imbalance of ROS and oxidative stress that can lead to cell death. The results of this study are in line with previous

studies that microscopically giving 40% ethanol content for ten days showed gastric histopathological changes in the form of gastric mucosal epithelial erosion. (Keba, Sasputra and Amat, 2019)

The results of the treatment of the plantain *floret* extract in the T1 group at a dose of 140mg/kgBW rats, the T2 group at a dose of 280mg/kgBW rats, in Wistar rats given 40% ethanol, there was no significant difference when compared to the C+ group. The results of the treatment in the T3 group at a dose of 560mg/kgBW rats when compared to the C+ group showed a significant difference. This indicates that groups T1, T2, and T3 are pro-oxidants. Prooxidants occur due to an imbalance between high antioxidant levels while low prooxidants, the body will form prooxidant compounds to balance antioxidant levels, and this will create free radical cells. (Suaniti & Manurung, 2017; Wijaya et.al, 2014) The highest experienced an increase in the amount of gastric mucosal damage, where the gastric mucosal damage in the T3 group exceeded the damage in the C+ group.

The gastroprotective effect of the plantain *floret* extract was shown by histopathological descriptions in the T1 group where normal cells dominated more than the T2 and T3 groups. Based on the phytochemical test, the plantain *floret* extract has active compounds in the form of flavonoids, alkaloids, terpenoids and steroids. The active compounds of flavonoids can provide a gastroprotective effect. The effect of flavonoids on ROS is by neutralizing free radicals and increasing endogenous antioxidants such as SOD

and catalase. The main flavonoid derivative is quercetin. Quercetin is an efficient free radical scavenger, capable of protecting the gastric mucosa from ulceration by reducing histamine secretion from mast cells (Jannah *et al.*, 2015).

The limitations of this study are the lack of dose variation of the plantain *floret* extract to determine the optimal dose and it is necessary to test the toxicity of the plantain *floret* extract using the LD₅₀ value of the hexane and ethyl acetate fractions.

CONCLUSIONS

Administration of plantain *floret* extract with doses of 140mg/kgBW, 280mg/kgBW and 560mg/kgBW rats could not prevent gastric mucosal damage caused by 40% ethanol at a dose of 1.8ml/200gBW rats.

ACKNOWLEDGEMENTS

In completing this scientific work, the author received a lot of support from various parties. As a form of gratitude to Allah SWT, the author would like to express his gratitude to the Faculty of Medicine UNIMUS, dr. Dyah Mustika Nugraheni, Master in Biomedical Sciences, dr. Rina Purnamasari, dr. Afiana Romani, Master in Biomedical Sciences, dr. Noor Yazid AD, Consultant of Anatomical Pathologist and several parties who have helped in conducting this study.

REFERENCES

- Irramah M. 2017. Pengaruh uncaria gambir roxb terhadap ulkus gaster dan kadar malondialdehid hewan coba

- yang diinduksi etanol. *Maj Kedokt Andalas* 40: 1.
- Jannah AI, Zuraida R. 2015. Banana (*Musa paradisiaca*) as antiulcerogenic in non steroid anti inflammation drug (NSAID) induced gastric ulcer. Fakultas Kedokteran, Universitas Lampung. *Majority* 4: 3-7.
- Keba DS, Sasputra IN, Amat ALS. 2019. Efek pemberian minuman sopi dibandingkan alkohol jenis lainnya terhadap gambaran histopatologi gaster tikus putih. *Cendana Med J* 7: 112-117.
- Kumar V; Cotran R; Robbins S. 2007. *Robbins Basic Pathology 7th Ed.* EGC: Jakarta.
- Purbaningsih E. 2020. Analisis faktor gaya hidup yang berhubungan dengan risiko kejadian gastritis berulang. *Syntax Idea - Sekol Tinggi Ilmu Kesehat* 2: 1-9.
- Suaniti NM, Manurung M UN. 2017. Efek penambahan antioksidan ekstrak metanol kulit buah manggis (*Garcinia mangostana L.*) terhadap perubahan kadar FFA, bilangan asam dan bilangan peroksida biodiesel. *Journal of Chemistry* 11(1): 49-55.
- Wijaya MS; Lisdian; Setiati N. 2014. Pemberian ekstrak benalu mangga terhadap perubahan histologis hepar tikus yang diinduksi kodein. *Biosaintifika J Biol Biol Educ* 6(2): 80-86.
- World Health Organization. 2018. The global status report on alcohol and health. World Health Organization.
- Yu C, Mei XT, Zheng YP, Xu DH. 2014. Gastroprotective effect of taurine zinc solid dispersions against absolute ethanol-induced gastric lesions is mediated by enhancement of antioxidant activity and endogenous PGE₂ production and attenuation of NO production. *Eur J Pharmacol* 740: 329-336.