

## Bleeding outcomes and musculoskeletal function in adolescents having severe hemophilia A: a case series

Fitri Primacakti, Marcel Prasetyo, Sri Novia Fauzia, Raisa Cecilia Sarita, Novie Amelia Chozie

As an emerging country, Indonesia is still in the process of implementing prophylaxis as a standard of care for managing hemophilia with limited real-world evidence in Indonesian patients. This case series details the effects of tertiary prophylaxis with an intermediate dose of factor VIII concentrate on bleeding outcomes and musculoskeletal function in three Indonesian adolescents suffering from severe haemophilia A and associated arthropathy. [Paediatr Indones. 2025;65:268-72; DOI: <https://doi.org/10.14238/pi65.3.2025.268-72> ].

**Keywords:** hemophilia; prophylactic therapy; arthropathy; intermediate dose; factor VIII

Prophylactic administration of replacement therapy with factor VIII (FVIII) products is the standard of care for managing hemophilia.<sup>1</sup> Prophylactic therapy is given at regular intervals to prevent bleeding, as opposed to ‘episodic’ therapy, which is administered in response to a bleeding episode. The World Federation of Hemophilia (WFH) strongly recommends the use of prophylaxis over episodic therapy at any age to reduce hemarthrosis and slow down the progression of hemophilic arthropathy.<sup>2</sup> However, according to the 2020 WFH Annual Global Survey, Indonesia has not reported any data on patients receiving a prophylactic regimen. As an emerging country, Indonesia is still in the process of implementing prophylaxis as a standard of care in daily practice, with many constraints to overcome. To date, only a single study from Indonesia using low-dose prophylaxis has been published.<sup>2,3</sup> The outcomes

of this study were consistent with the majority of previous studies in other demographics, showing the benefits of low-dose prophylaxis in reducing morbidity and preserving joint health compared to episodic therapy.<sup>4,5</sup>

These case series report the administration of tertiary prophylaxis using an intermediate concentrate dose on bleeding outcomes and musculoskeletal function in three Indonesian adolescents with severe hemophilia A and associated arthropathy.

### The cases

Three previously treated patients (PTPs), with documented target joints, who had been treated with episodic treatment were followed up at a tertiary referral hospital in Jakarta, Indonesia. The patients were given an intermediate dose of Beriate® plasma-derived (PD) FVIII concentrate with a dose of 25 IU/kg, two times a week. The parents of all three patients

---

From the Department of Child Health, Faculty of Medicine Universitas Indonesia/Dr. Cipto Mangunkusumo Hospital, Jakarta, Indonesia.

**Corresponding author:** Fitri Primacakti. Department of Child Health, Faculty of Medicine Universitas Indonesia/Dr. Cipto Mangunkusumo Hospital. Jl. Salemba Raya No. 6, Jakarta Pusat 10430, Indonesia. Email: [bund4zia@gmail.com](mailto:bund4zia@gmail.com).

Submitted February 17, 2023. Accepted July 1, 2025.

provided informed consent for publication their cases. We assessed each patient's annualized bleeding rate (ABR), annualized joint bleeding rate (AJBR), *Hemophilia Joint Health Score* (HJHS), *Hemophilia Early Arthropathy Score* (HEAD-US) before starting the prophylaxis, then six months and one year after starting the prophylaxis. Additionally, we used the *Pediatric Quality of Life* (PedsQL) questionnaire to evaluate the patients' quality of life before and after the prophylaxis. All three patients were diagnosed with severe hemophilia A, with FVIII levels below 1%. None of the patients had a history of inhibitors. We also screened for inhibitor development throughout the study. Based on body mass index (BMI), patient 1 and 3 had had grade 1 obesity, while patient 2 had normal weight.

### Case 1

A 13-year-old boy was diagnosed with severe hemophilia A at 6 months of age. Hemophilia was suspected in infancy, when trauma experienced while crawling resulted in a swollen knee that did not improve. At 6-month-old, he had joint bleeding and was treated with PD concentrate, followed by recombinant concentrate and cryoprecipitates for episodic treatment. After switching to an intermediate dose regimen, he experienced two instances of breakthrough joint bleeding, one spontaneous and another following trauma.

**Figure 1** shows the outcomes of prophylaxis. The ABR and AJBR declined during the one-year follow up. Joint ultrasound before prophylaxis confirmed hemophilic arthropathy with severe hypertrophic synovium in both ankles, irregular cartilage in both knees and the right ankle, and an osteochondral defect in the left ankle. After one year of prophylaxis, there was progression of damage in the right knee and both ankles as shown by increased HEAD-US score (from 17 to 20), while HJHS evaluation showed improvement. **Figure 2** showed that the patient had low quality of life in school function before prophylaxis. However, this function improved after prophylaxis along with physical, emotional, and social improvement. No adverse events were recorded, but the patient was diagnosed with mild coronavirus disease at the end of the prophylaxis period.

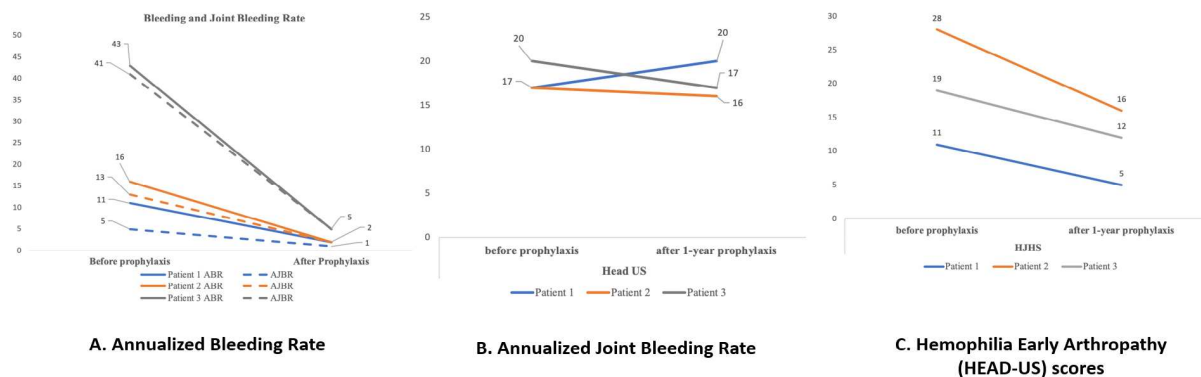
### Case 2

A 15-year-old boy was diagnosed with severe hemophilia A at 6 months of age. The first clinical symptom reported was multiple bruises on the extremities. His uncle was known to have hemophilia A. After the patient was diagnosed with hemophilia A, cryoprecipitate was administered as the first treatment, followed by PD and recombinant concentrates. He had a documented target joint on the right elbow, and the range of movement of his arm was limited. Spontaneous breakthrough bleeding occurred on the right ankle and right elbow. During prophylaxis, the patient was hospitalized twice with gastritis and coronavirus disease. The ABR and AJBR reduced during prophylaxis, HJHS and HEAD-US score improved, but there was no significant improvement in HEAD-US: from 17 to 16 (**Figure 1**), which confirmed severe hemophilic arthropathy on the right elbow and both ankles with mild cartilage erosion on the left elbow joint and both knees. Inhibitor remained negative. Quality of life assessment did not show significant improvement in physical, emotional, or school aspects (**Figure 2**).

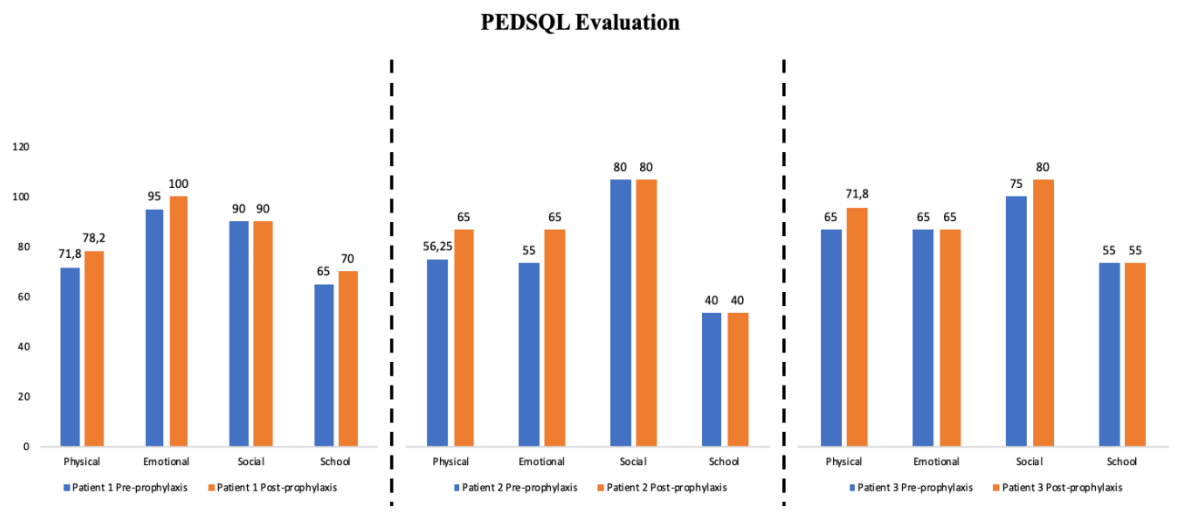
### Case 3

A 15-year-old boy was diagnosed with severe hemophilia at 2 years of age. The diagnosis was made after the patient underwent a motor accident, which resulted in ongoing bleeding of both hands. He experienced multiple bruises on his extremities during infancy; however, his parents never consulted a doctor, leaving the condition undiagnosed despite a family history of severe hemophilia A.

During the first month of prophylaxis, he experienced repeated breakthrough bleeding on the right ankle. As a result, he received episodic therapy (15 IU/kg) every 12 hours. Typically, the breakthrough bleeding episodes stopped after administration of the episodic dose, following which the prophylaxis regimen was continued. Joint bleeding was recorded 5 times during prophylaxis episodes. One episode of traumatic bleeding occurred after the patient increased the frequency of his swimming sessions, whereas the other episodes were spontaneous. The prophylaxis dose and frequency were not increased for this patient because breakthrough bleeding occurred no more than three times every three months. However, after one year



**Figure 1.** All components of evaluation during the study. (A) annualized bleeding rate (ABR) and annualized joint bleeding rate (AJBR) from the three patients before and after one-year intermediate prophylaxis. The data of ABR and AJBR before prophylaxis was obtained from our centre’s database before the patients proceeded with the study. (B) HEAD-US scores before prophylaxis and after one year of prophylaxis, (C) HJHS before prophylaxis and after one year of prophylaxis.



**Figure 2.** Quality of life of the three patients measured by *The Paediatric Quality of Life Inventory* (PedsQL) measurement consist of physical, emotional, social, and school function.

prophylaxis, the ABR and AJBR was significantly reduced 90% as shown in **Figure 1**. Inhibitor was not detected throughout the year.

All bleeding episodes involved the right ankle joint. Due to several episodes of pain in the right ankle joint despite the administration of episodic therapy, in the second month of prophylaxis, right ankle ultrasound was conducted to confirm for any new bleeding episode. The results showed no intraarticular

effusion or bleeding in the joint. The HEAD-US of the right ankle showed mild subchondral bone deformity, more than 50% irregular cartilage, and severe prominent synovial hypertrophy of right ankle. After one year of prophylaxis, his HJHS score improved from 28 to 16 and his HEAD-US score improved from 20 to 17 (**Figure 1**). This patient had low quality of life in physical, emotional, and school functions before prophylaxis. His quality of life in physical aspects

improved after prophylaxis, but no such improvement was seen in other aspects (Figure 2).

## Discussion

In our case series, we administered tertiary prophylaxis to three PTPs, resulting in a significant reduction in the ABR and AJBR using an intermediate dose regimen (25 IU/kg) twice weekly. These three patients had previously only received clotting factor concentrate (CFC) in the event of a bleed, using either PD or recombinant concentrate. Due to inadequate treatment, all of them developed a target joint. All three patients were participants in our first low-dose prophylaxis study in our center in 2017.<sup>3</sup> The first and third patient received a prophylaxis regimen of 10 IU/kg twice weekly, whereas patient 2 received an episodic regimen during the low-dose prophylaxis study. In this case series, we tried to escalate the dose of prophylaxis using an intermediate dose to evaluate the occurrence of breakthrough bleeding.

All patients had similar characteristics; they were adolescents with severe hemophilia A who had been first diagnosed no later than age 2 years. They had received several types of treatment, from PD to recombinant concentrate, and no history of inhibitors was recorded. Patients 1 and 3 were categorized as having grade 1 obesity when they started the prophylaxis, which may explain the higher risk of developing a target joint on primary weight-bearing joints such as the knee and ankle.

The intermediate dose regimen is known to reduce AJBRs by approximately 90% to less than 1 per year.<sup>6</sup> A meta-analysis evaluating 6 randomized clinical trials globally showed that, compared to episodic treatment, mean ABR was lower in those who used low-dose, intermediate-dose and high-dose prophylaxis, with significant differences between these subgroups.<sup>7</sup> Our finding in line with previous study that revealed intermediate dose prophylaxis was reduced significantly numbers of the bleeding including the ABRs and AJBRs.

The use of intermediate tertiary prophylaxis in all three patients did not improve the anatomical structure of the joints, compared to episodic therapy, as indicated by their HEAD-US and HJHS scores. The baseline scores of all patients likely reflected

the pre-existing condition of the documented target joints before the implementation of prophylaxis. The HEAD-US score decreased in patient 2 and 3, but not significantly, while it increased in patient 1. This may be due to the fact that HEAD-US evaluates the condition of joint in real-time during the examination, and patient 1 had a recent breakthrough bleeding just 2 weeks before the HEAD-US examination at the end of prophylaxis study. Despite episodic treatment for the recent bleeding, this condition may have affected the scoring. Moreover, a prospective multicenter study in Turkey also showed that despite prophylaxis, HEAD-US scores during a one-year follow-up significantly increased.<sup>8</sup> A previous study also showed results consistent with ours, suggesting that while prophylaxis may slow down the progression upon onset of arthropathy, the degenerative process persisted, especially in older children.<sup>9</sup> Furthermore, when comparing the results of these three patients to a previous low-dose prophylaxis study in our center, the result was similar. Patient 1's HEAD US scores changed from 22 to 21 after one year in the clinical trial and from 19 to 12 in patient 3 after low-dose prophylaxis.<sup>3</sup> Even though the HEAD-US may not change significantly, the HJHS was found to be reduced and may help improve the musculoskeletal function. In our center, there was a study on the correlation between HEAD-US and HJHS which indicated that HEAD-US can provide additional value in the anatomical evaluation of the joint and could be complementary to HJHS in assessing the joint status in hemophilic arthropathy.<sup>10</sup>

There was an improvement of QoL of all subjects after prophylaxis, however these improvements were not significantly in patient 2 and 3, particularly in emotional aspects. Further evaluation has to be done to identify this problem. All subjects have low QoL in the school function. The prophylaxis was given during COVID-19 period, thus the school function could not be evaluated precisely since the study was conducted online from home.

The three cases of Indonesian adolescents with severe hemophilia A leading to joint arthropathy reported here demonstrated reduced AJBR upon treatment using an intermediate dose of twice-weekly, 25 IU/kg of PD FVIII concentrate. Although there was no improvement in anatomical structure, the prophylactic treatment improved joint function and

led to better clinical outcomes compared to episodic FVIII treatment. Our cases suggest that prophylactic FVIII treatment is more effective for adolescents with severe hemophilia A in Indonesia.

### Acknowledgments

The authors would like to thank the study participants and their families to participate in this study and Ns. Lestari, who helped administer the FVIII concentrates throughout the study. The authors also thank CSL Behring and Dexa Medica pharmaceutical company for providing the FVIII concentrate. Dr Pratishtha Chaudhari from *WriterMD Ltd* provided medical writing support.

### Footnote

The 6 months data of this case series was presented as online poster at WFH 2022 World Congress [https://www.postersessiononline.eu/173580348\\_eu/congresos/WFH2022/aula/-PO\\_30\\_WFH2022.pdf](https://www.postersessiononline.eu/173580348_eu/congresos/WFH2022/aula/-PO_30_WFH2022.pdf). The above manuscript includes one-year data of the cases.

### References

1. Manco-Johnson MJ, Abshire TC, Shapiro AD, Riske B, Hacker MR, Kilcoyne R, et al. Prophylaxis versus episodic treatment to prevent joint disease in boys with severe hemophilia. *N Engl J Med*. 2007;357:535-44. DOI: <https://doi.org/10.1056/NEJMoa067659>
2. Srivastava A, Santagostino E, Dougall A, Kitchen S, Sutherland M, Pipe SW, et al. WFH Guidelines for the Management of Hemophilia. 3<sup>rd</sup> edition. *Haemophilia*. 2020;26:1-158. DOI: <https://doi.org/10.1111/hae.14308>
3. Chozie NA, Primacakti F, Gatot D, Setiabudhy RD, Tulaar ABM, Prasetyo M. Comparison of the efficacy and safety of 12-month low-dose factor VIII tertiary prophylaxis vs on-demand treatment in severe haemophilia A children. *Haemophilia*. 2019;25:633-9. DOI: <https://doi.org/10.1111/hae.13770>
4. Verma SP, Dutta TK, Mahadevan S, Nalini P, Basu D, Biswal N, et al. A randomized study of very low-dose factor VIII prophylaxis in severe haemophilia - A success story from a resource limited country. *Haemophilia*. 2016;22:342-8. DOI: <https://doi.org/10.1111/hae.12838>
5. Wu RH, Wu XY, Zhang NN, Zhao L, Zhang JS, Zhen YZ, et al. Long-term low-dose secondary prophylaxis for severe and moderate hemophilia children with arthropathy in China: a single-center observation study]. *Zhonghua Xue Ye Xue Za Zhi*. 2013;34:632-4. DOI: <https://doi.org/10.3760/cm.a.j.issn.0253-2727.2013.07.018>
6. Teitel JM, Carcao M, Lillicrap D, Mulder K, Rivard GE, St-Louis J, et al. Orthopaedic surgery in haemophilia patients with inhibitors: a practical guide to haemostatic, surgical and rehabilitative care. *Haemophilia*. 2009;15:227-39. DOI: <https://doi.org/10.1111/j.1365-2516.2008.01840.x>
7. Delgado-Flores CJ, García-Gomero D, Salvador-Salvador S, Montes-Alvis J, Herrera-Cunti C, Taype-Rondan A. Effects of replacement therapies with clotting factors in patients with hemophilia: A systematic review and metaanalysis. *PLoS ONE*. 2022;17:e0262273. DOI: <https://doi.org/10.1371/journal.pone.0262273>
8. Kavaklı K, Özbek SS, Antmen AB, Şahin F, Aytaç ŞS, Küpesiz A, et al. Impact of the HEAD-US Scoring System for observing the protective effect of prophylaxis in hemophilia patients: a prospective, multicenter, observational study. *Turk J Haematol*. 2021;38:101-10. DOI: <https://doi.org/10.4274/tjh.galenos.2021.2020.0717>
9. Warren BB, Thornhill D, Stein J, Fadell M, Ingram JD, Funk S, et al. Young adult outcomes of childhood prophylaxis for severe hemophilia A: results of the Joint Outcome Continuation Study. *Blood Adv*. 2020;4:2451-9. DOI: <https://doi.org/10.1182/bloodadvances.2019001311>
10. Prasetyo M, Moniqa R, Tulaar A, Prihartono J, Setiawan SI. Correlation between Hemophilia Early Arthropathy Detection with Ultrasound (HEAD-US) score and Hemophilia Joint Health Score (HJHS) in patients with hemophilic arthropathy. *PLoS One*. 2021;16:1-8. DOI: <https://doi.org/10.1371/journal.pone.0248952>