

Diagnostic challenges in 46, XY disorder of sex development due to 5-alpha-reductase type 2 deficiency: a case report

Ni Kadek Risa Astria^{1*}, I Made Arimbawa², I Made Darma Yuda²

¹Pediatric Residency Program, Department of Child Health, Faculty of Medicine, Universitas Udayana / Prof. Dr. I.G.N.G. Ngoerah General Hospital

²Department of Child Health, Medical Faculty, Universitas Udayana/Prof. dr. I.G.N.G. Ngoerah General Hospital

*Corresponding to:

Ni Kadek Risa Astria; Pediatric Residency Program, Department of Child Health, Faculty of Medicine, Universitas Udayana / Prof. Dr. I.G.N.G. Ngoerah General Hospital;
risaastria95@gmail.com

Received: 2026-02-08

Accepted: 2026-03-29

Published: 2026-04-17

ABSTRACT

Backgrounds: Disorders of sex development (DSD) represent congenital conditions characterized by atypical chromosomal, gonadal, or anatomical sex differentiation. Among 46,XY DSD, 5-alpha-reductase type 2 deficiency (5-ARD) is a rare autosomal recessive disorder caused by impaired conversion of testosterone to dihydrotestosterone (DHT), resulting in undervirilization at birth. Early recognition is often challenging, particularly in resource-limited settings, leading to delayed diagnosis until virilization becomes apparent during childhood or puberty.

Case Presentation: We report the case of an 8-year-old child raised as male who presented with ambiguous genitalia and absent testes. The parents noted genital atypia since birth, but financial barriers delayed medical evaluation until age two. The patient demonstrated normal growth and developmental milestones. Physical examination revealed male-type external genitalia with a glans penis, perineal urethral opening, non-palpable testes, and Prader stage 4–5 virilization. Abdominal ultrasonography showed no scrotal or inguinal testes and the absence of a uterus. Diagnostic laparoscopy revealed a fibrotic right testis, while the left testis could not be identified. Cytogenetic analysis demonstrated a 46, XY karyotype. Hormonal evaluation showed markedly low baseline DHT (0.4 nmol/L) with a disproportionately low increase after β -hCG stimulation despite a significant rise in testosterone (44 to 488 ng/dL), confirming impaired conversion to DHT consistent with 5-ARD. A multidisciplinary team concluded that further management would include DHT therapy, staged genitourinary reconstruction, psychological support, and legal proceedings for sex assignment correction, as the patient was registered female at birth.

Conclusion: This case underscores the importance of early clinical recognition and timely, coordinated diagnostic evaluation in suspected 5-ARD, particularly in resource-limited settings. Prompt identification facilitates appropriate multidisciplinary management and may improve both clinical and psychosocial outcomes.

Keywords: *ambiguous genitalia; case report; 5-alpha-reductase deficiency; disorder of sex development; 46,XY DSD.*

Cite this Article: Astria, N.K.R., Arimbawa, I.M., Yuda, I.M.D. 2026. Diagnostic challenges in 46, XY disorder of sex development due to 5-alpha-reductase type 2 deficiency: a case report. *IJBS* 20(1): 23-28. DOI: [10.15562/ijbs.v20i1.668](https://doi.org/10.15562/ijbs.v20i1.668)

INTRODUCTION

Disorders of sex development (DSD) comprise a heterogeneous group of congenital conditions characterized by atypical development of chromosomal, gonadal, or anatomical sex. Classified by the Lawson Wilkins Pediatric Endocrine Society and the European Society for Paediatric Endocrinology into sex chromosomal DSD, 46, XX DSD, and 46, XY DSD, these conditions collectively occur in approximately 1 in 4,500–5,500 live births. Among them, 46, XY DSD arises from impaired androgen

production or action, frequently resulting in undervirilization of individuals with a male karyotype.¹

One important but rare cause of 46, XY DSD is 5-alpha reductase type 2 deficiency (5-ARD), an autosomal recessive disorder caused by mutations in the SRD5A2 gene, which encodes the enzyme responsible for converting testosterone (T) into the more potent androgen dihydrotestosterone (DHT). DHT plays a crucial role in the differentiation of external male genitalia and prostate development in utero; thus, deficiency leads to a spectrum of phenotypes ranging from

female-appearing external genitalia to varying degrees of undervirilization at birth. Despite this, Wolffian structures typically differentiate normally because their development depends primarily on testosterone rather than DHT.²

A detailed history is essential to uncover any relevant familial patterns, including genital or urologic abnormalities, particularly prior occurrences of ambiguous genitalia. It is important to determine whether consanguinity is present, as this increases the probability of autosomal recessive disorders. Additional key points include

histories of amenorrhea, infertility, or premature menopause. Maternal factors should also be explored, such as previous spontaneous miscarriages, stillbirths, or unexplained neonatal deaths that may reflect an unrecognized adrenal crisis, as well as exposure to medications during pregnancy that could cause fetal virilization. Furthermore, maternal clinical signs, especially manifestations of androgen excess such as hirsutism or virilization, may indicate an underlying endocrine disorder contributing to the presentation.³

Clinically, affected individuals often present in infancy with ambiguous genitalia, micropenis, hypospadias, inguinal masses, or labioscrotal fusion. However, in cases where genitalia appear typically female at birth, diagnosis may be delayed until puberty, when rising testosterone levels lead to spontaneous virilization, including voice deepening, phallic enlargement, and increased muscle mass.⁴ This unexpected pubertal transition can trigger significant psychosocial distress, prompting re-evaluation of sex assignment and gender identity. Biochemical evaluation typically reveals normal or elevated testosterone levels, reduced DHT, and an increased T/DHT ratio, while definitive diagnosis relies on genetic confirmation of SRD5A2 mutations.⁵

Management of 5-ARD is complex and requires a multidisciplinary approach, integrating pediatric endocrinology, urology, psychology, genetics, psychiatry, and ethics. Decisions regarding sex assignment, timing of surgical intervention, and long-term follow-up must consider phenotypic presentation, anticipated pubertal changes, fertility potential, and the evolving gender identity of the patient. As evidenced in several studies, early diagnosis and coordinated care are essential for optimizing psychosocial and functional outcomes.⁶

However, despite existing knowledge, there remains a significant gap in the literature regarding the real-world diagnostic challenges and delays in low-resource settings, particularly in developing countries such as Indonesia, where socioeconomic barriers, limited access to specialized care, and cultural considerations may complicate early

identification and management of DSD. Delayed diagnosis may lead to prolonged uncertainty in sex assignment, suboptimal clinical outcomes, and increased psychosocial burden for both patients and families.

Therefore, this case report aims to highlight the diagnostic challenges, the impact of socioeconomic constraints on delayed presentation, and the complexity of multidisciplinary management of 5-ARD within the Indonesian healthcare context, emphasizing the importance of early recognition and coordinated evaluation to improve patient outcomes.

CASE DESCRIPTION

An 8-year-old child raised as male was referred for evaluation of ambiguous genitalia and non-palpable testes. At birth, the patient was assigned female based on external genital appearance. Progressive clitoral enlargement during early childhood resulted in a phallic structure, while urination remained through a perineal urethral opening. Financial constraints delayed medical evaluation until the age of two years.

The patient had no significant past medical history and demonstrated

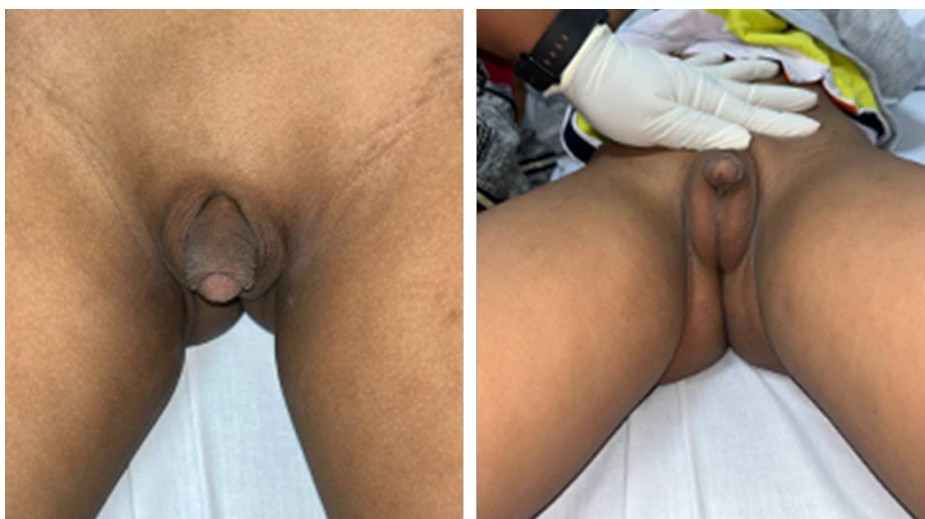

Figure 1. Physical characteristics of the patient illustrate the male type of body contour.

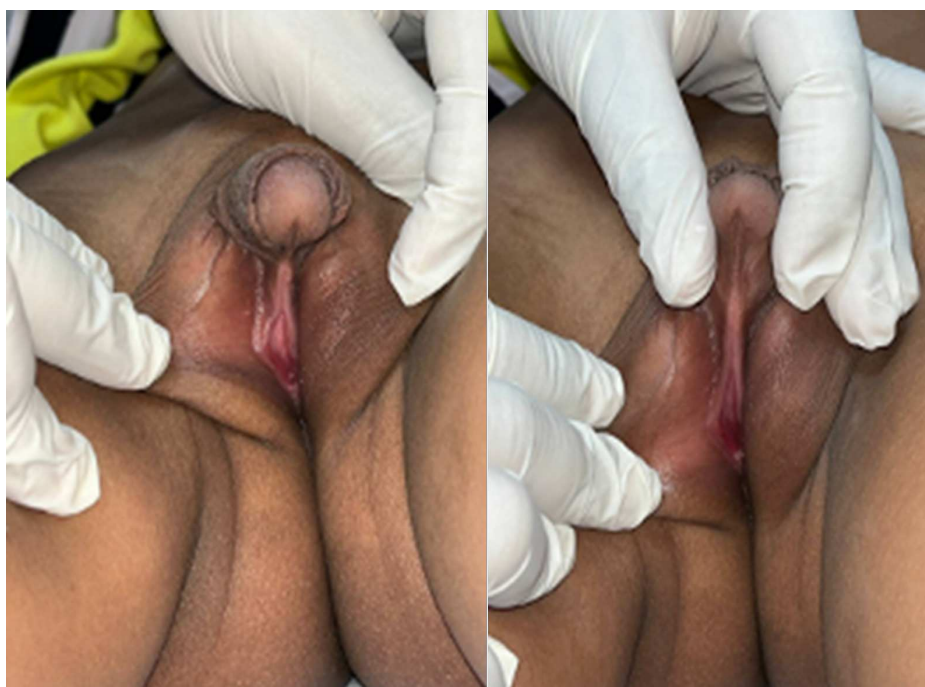

Figure 2. Clinical photograph showing external genitalia

normal growth and developmental milestones. On examination, the patient was in stable condition with normal vital signs and appropriate anthropometric measurements, indicating good nutritional status. Systemic examination was unremarkable. Genital examination revealed male-type external genitalia with a phallic structure and visible glans penis, perineal urethral opening (hypospadias), and bilaterally non-palpable testes, without hyperpigmentation. These findings were consistent with Prader stage 4–5 virilization (Figures 1 and 2)

Abdominal ultrasonography performed in July 2023 revealed the absence of testicular structures in the scrotal and inguinal regions, with no visualization of a uterus. The presence of intra-abdominal testes could not be confirmed. Diagnostic laparoscopy in December 2023 identified a fibrotic right testis, while the left testis was not visualized. A cervix-like structure with a patent lumen was also observed. Subsequently, β -hCG stimulation testing with serial hormonal assessment was performed in 2024. Cytogenetic analysis demonstrated a normal male karyotype (46,XY), with no structural or numerical chromosomal abnormalities, confirming the diagnosis of 46,XY DSD (Figure 3).

Hormonal evaluation showed normal 17-hydroxyprogesterone (1.17) and markedly low dihydrotestosterone (DHT) (0.4 nmol/L). Baseline testosterone prior to β -hCG stimulation was 44 ng/dL, which increased to 488 ng/dL post-stimulation, while DHT rose only minimally (5 to 14 ng/dL). This discordant response, reflected by an elevated testosterone-to-DHT ratio, is consistent with impaired conversion of testosterone to DHT, confirming 5- α -reductase deficiency.

A multidisciplinary team meeting was conducted in May 2025 to determine further management. The patient was approaching puberty and had developed a male gender identity. However, the prognosis for fertility was considered poor, and postoperative penile function was expected to be limited. The agreed management plan included topical DHT (Andractim) therapy for 4–5 months, followed by staged genitourinary reconstruction (urethroplasty and orthoplasty), along with psychological




Figure 3. Cytogenetic report

support. The urology team noted that the right testis was fibrotic and the left testis was not identifiable, further reducing fertility potential. Access to DHT therapy remains a challenge, as the medication is not available domestically and requires special authorization for importation. Psychiatric evaluation identified mild social difficulties, and ongoing counselling for the patient and family was recommended. Growth and development assessments were within normal limits. From a legal perspective, correction of sex assignment requires a formal court decision, as the patient was registered female at birth. The process is currently ongoing, supported by a multidisciplinary medical report.

DISCUSSION

Individuals who exhibit congenital variations in the development of chromosomal, gonadal, or anatomical sex are categorized as having a Disorder of Sex Development (DSD). These conditions frequently manifest with atypical or ambiguous genitalia. Historically, the term *intersex* was applied, with cases further classified into male pseudohermaphroditism, female pseudohermaphroditism, or true hermaphroditism. However, following the 2006 consensus statement, a revised terminology was adopted, replacing *intersex* with *Disorder of Sex Development* and reorganizing the classification into three major groups: 46, XX DSD, 46, XY DSD, and sex chromosome DSD.^{7,8} Sexual

differentiation is regulated by a complex interaction of genetic and hormonal factors; however, detailed embryological mechanisms are beyond the scope of this report. In the context of this case, impaired androgen metabolism, particularly reduced conversion of testosterone to dihydrotestosterone (DHT), plays a central role in the development of undervirilized external genitalia in individuals with a 46,XY karyotype.^{9,10}

A comprehensive diagnostic workup, including clinical assessment, hormonal evaluation, radiologic imaging, and chromosomal analysis, is essential for identifying cases of DSD. Among the various manifestations, ambiguous genitalia represent the most frequent clinical presentation. The incidence of genital ambiguity differs between regions and is notably influenced by the prevalence of consanguineous marriages within a population. Research from countries with high rates of consanguinity demonstrates a greater occurrence of ambiguous genitalia, with reported incidences of approximately 1 in 2,500 live births in Saudi Arabia and 1 in 3,000 in Egypt.¹¹ External genital ambiguity may be identified at birth or present later, particularly in cases where genitalia appear typically female initially but virilization occurs at puberty.¹²

In high-resource settings, early evaluation is typically performed shortly after birth. However, in resource-limited settings, delayed diagnosis remains a significant challenge due to socioeconomic barriers, limited access to specialized care, and sociocultural

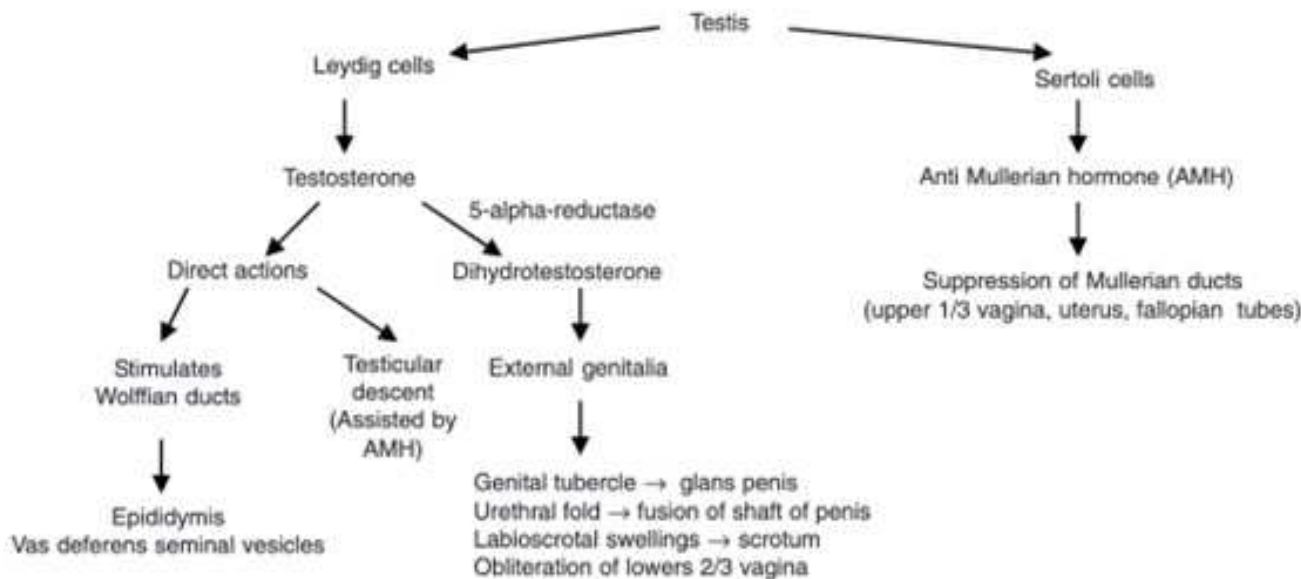


Figure 4. The process of sexual differentiation.¹⁰

factors.¹³ This was evident in the present case, where early signs of genital atypia were recognized but formal evaluation was delayed, contributing to late diagnosis and its associated clinical and psychosocial implications.

Clinically, this patient presented with Prader stage 4–5 virilization, characterized by a phallic structure, perineal urethral opening, and non-palpable testes, consistent with severe undervirilization in 46,XY DSD. The patient’s male gender identity and progression toward puberty further supported the need for timely diagnostic clarification and management.

Traditionally, the diagnosis of 5 α -reductase type 2 deficiency relies on biochemical evaluation, particularly the testosterone-to-dihydrotestosterone (T/DHT) ratio following β -hCG stimulation. In normal individuals, both testosterone and DHT increase proportionally after stimulation. In contrast, patients with 5-ARD exhibit a marked increase in testosterone with a disproportionately low rise in DHT, resulting in an elevated T/DHT ratio. This biochemical pattern helps differentiate 5-ARD from other causes of 46,XY DSD, such as androgen insensitivity syndrome, where DHT levels are typically normal.¹⁵ In this case, testosterone increased substantially following β -hCG stimulation (44 to 488 ng/dL), while DHT showed only a minimal rise (5 to 14 ng/

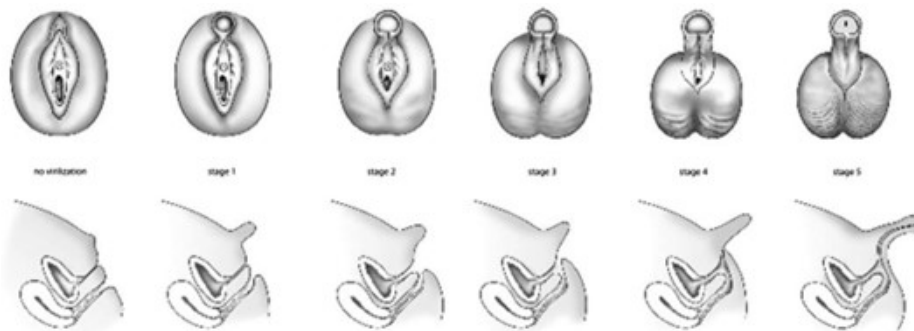


Figure 5. Prader Staging and virilization of the external genitalia.¹⁴

dL), demonstrating a clear discordance consistent with impaired enzymatic conversion. These findings strongly support the diagnosis of 5-ARD. However, it is important to note that the T/DHT ratio has variable sensitivity and specificity and may be inconclusive in partial enzyme deficiency, limiting its role as a standalone diagnostic tool.¹⁵ A key limitation of this case is the absence of molecular genetic testing to confirm mutations in the SRD5A2 gene. This reflects a common challenge in resource-limited settings, where access to advanced diagnostic modalities remains restricted. The lack of genetic confirmation may affect diagnostic certainty and limit genotype-phenotype correlation, which can be important for prognostication and family counselling.

The SRD5A2 gene encodes the 5 α -reductase type 2 enzyme responsible for converting testosterone to DHT. Mutations in this gene result in varying degrees of enzymatic dysfunction, leading to a spectrum of phenotypic presentations depending on residual enzyme activity. Management of 5-ARD is complex and requires a multidisciplinary approach. Historically, many patients were assigned female at birth; however, studies indicate that a significant proportion transition to male gender identity during puberty. In this case, the patient was raised as male and demonstrated male gender identification, which guided clinical decision-making.¹⁶ Delayed presentation in this patient significantly affected management options, particularly fertility

preservation, as early orchidopexy was not performed. The presence of a fibrotic testis and non-identifiable contralateral gonad further suggests a poor fertility prognosis.

At present, no standardized guidelines exist for the management of children with 5 α -reductase deficiency. Because these patients often present with ambiguous genitalia, many were traditionally assigned a female gender at birth; however, evidence now indicates that more than 60% of those raised as female later transition to a male gender identity during puberty.¹⁷ In early infancy, the condition can be clinically challenging to differentiate from androgen insensitivity syndrome, and the testosterone-to-DHT ratio may be inconclusive, particularly in individuals with partial enzyme activity, highlighting the importance of definitive molecular testing to support timely clinical decisions. Although external genital virilization is impaired, fetal androgen exposure to the brain remains intact, which is believed to contribute to the higher prevalence of gender dysphoria in this population.¹⁸ Research suggests that increased gray matter volume in brain regions typically associated with males correlates with elevated fetal testosterone levels. These permanent neurodevelopmental effects occur through direct testosterone action during prenatal life, separate from DHT-dependent genital masculinization. With the rise in testicular testosterone production during puberty, these prenatally established neural pathways are thought to become functionally active, potentially explaining the higher frequency of female-to-male gender transition during adolescence.¹⁹ In this case, the patient was raised as a male, given a masculine name, and registered as male. His peers are not aware of his condition and have been recognized as male since younger age. Following detailed counselling and examination, a team of pediatric endocrinologists, pediatric urologists, gynecologists, psychiatrists, radiologists, and a forensic physician, the patient planned to undergo surgical interventions include urethroplasty, cordectomy, and orthoplasty, with possible excision of any remaining vestibulum by the urogynaecology team. Given that orchidopexy should ideally be performed

before one year of age, the patient is now almost certainly infertile.

A decline in quality of life among children with DSD is largely linked to psychosocial difficulties, including gender dysphoria, parental or familial rejection, shame, and social withdrawal. Study from Raza J et al emphasizes that caring for children with DSD presents significant mental health and psychosocial challenges. Mismatch between assigned sex and physical characteristics can hinder psychosocial adjustment and lead to considerable emotional distress, further shaped by variations in family education, socioeconomic circumstances, religious beliefs, and differences in access to specialized healthcare. An international survey also noted that only 41% of centers have adequate expertise in DSD care, underscoring the need for routine psychosocial assessment in all pediatric DSD cases.¹³

Management of patients with DSD encompasses not only clinical and hormonal considerations but also complex legal and ethical challenges, particularly in countries with rigid binary sex-registration systems such as Indonesia. At birth, every individual must be registered as either male or female, leaving no legal space for variations of sex characteristics, which may result in misclassification and later difficulties when patients seek correction of their legal documents. Many patients with DSD experience obstacles in obtaining legal gender recognition, as court approval is required to change sex markers, often demanding extensive medical testimonies and expert evidence. This process can be emotionally taxing and financially burdensome for families. Ethically, early surgical interventions performed without the patient's consent, traditionally aimed at "normalizing" genital appearance, raise concerns regarding bodily autonomy, the risk of irreversible harm, and the long-term psychological impact.^{20,21}

International human rights frameworks increasingly advocate delaying non-urgent genital surgeries until the individual is mature enough to participate in decision-making. In Indonesia, stigma and limited understanding of intersex variations further complicate these issues, exposing patients and families to

discrimination in healthcare, education, and society. Therefore, ethically sound management requires a multidisciplinary approach grounded in informed consent, psychosocial support, and respect for bodily integrity. At the same time, legal reforms are needed to ensure accessible gender recognition procedures and protection from discrimination for individuals with DSD.^{20,21} In this case, from a legal perspective, because the patient was registered as female at birth, a court ruling is required to authorize a change in legal sex, supported by expert documentation from the hospital. Consequently, further medical treatment will await the legal decision. DHT procurement is in progress, and continued psychosocial support is crucial, with realistic expectations regarding future fertility and sexual function.

CONCLUSION

This case highlights a 46,XY disorder of sex development due to 5-alpha-reductase type 2 deficiency (5-ARD), characterized by ambiguous genitalia at birth, delayed diagnosis, and progressive virilization. The diagnosis was established through clinical findings, cytogenetic confirmation, and a characteristic hormonal profile demonstrating impaired conversion of testosterone to dihydrotestosterone.

Delayed evaluation due to socioeconomic constraints contributed to late diagnosis, limiting fertility potential and complicating management. This case underscores the importance of early recognition and timely diagnostic evaluation in suspected DSD to optimize clinical and psychosocial outcomes. Management requires a multidisciplinary approach, including hormonal therapy, surgical planning, psychological support, and legal consideration for sex reassignment. In resource-limited settings, barriers such as restricted access to therapy and legal processes may further delay definitive management. Overall, this report emphasizes the need for improved awareness, early referral systems, and coordinated care to enhance outcomes in patients with DSD, particularly in developing healthcare settings.

CONSENT FOR PUBLICATION

Written informed consent for publication of the clinical information and accompanying images was obtained from the patient's parent. All efforts were made to protect the patient's identity, and no identifying information is included in this manuscript.

AUTHOR CONTRIBUTIONS

All authors made substantial contributions to the conception and design of the study. Data collection, analysis, and interpretation were performed collaboratively. The manuscript was drafted and critically revised for important intellectual content by the authors, and all authors approved the final version of the manuscript prior to submission.

FUNDING

This research received no external funding and was conducted without financial support from any public, commercial, or not-for-profit funding agencies.

CONFLICT OF INTEREST

The authors declare that there is no conflict of interest regarding the publication of this manuscript.

USE OF AI-GENERATED ASSISTANCE

Artificial intelligence-based tools were used to assist with language editing and the improvement of manuscript clarity.

The authors carefully reviewed and validated all AI-assisted content and assume full responsibility for the accuracy and integrity of the manuscript.

REFERENCES

- Susilo AFP, Tjandraprawira KD, Bayu P, Bayuaji H. Disorders of sex development (DSD) 46,XY due to type 2 5-alpha reductase deficiency in three siblings: case report from a low-resource setting. *Ann Med Surg (Lond)*. 2022;82:104577. doi:10.3843/GLOWM.10350.
- Zhu Y, Imperato-McGinley J. Male sexual differentiation disorder and 5 α -reductase-2 deficiency. *Glob Libr Women's Med*. 2008. doi:10.3843/GLOWM.10350.
- Guerrero-Fernández J, Azcona San Julián C, Barreiro Conde J, Bermúdez de la Vega JA, Carcavilla Urquí A, Castaño González LA, et al. Management guidelines for disorders/differences of sex development (DSD). *n Pediatr (Engl Ed)*. 2018;89(5):315.e1–315.e19.
- Noroozi Asl S, Ibrahim R, Bagheri S, Lotfi M. 5-alpha reductase deficiency: an important cause of 46,XY DSD—report of three cases within a family. *Clin Case Rep*. 2023;11:e7269. doi:10.1002/ccr3.7269.
- Anggareni KT, Arimbawa IM, Yuda IMD. Defisiensi 5-alpha-reduktase: sebuah laporan kasus jarang. *Medicina (Bali)*. 2023;54(3):186–190. doi:10.15562/medicina.v54i3.1287.
- Bose S, Das K, George B, Raman V, Shubha AM, Mahadevappa K, et al. 46,XY disorder of sex development due to 5 α (SRD5A2) deficiency: experience from a multidisciplinary pediatric gender clinic. *J Pediatr Urol*. 2022;18(4):492.e1–492.e8.
- Lee PA, Houk CP, Ahmed SF, Hughes IA. Consensus statement on management of intersex disorders. *Pediatrics*. 2006;118(2):488–500.
- Hughes IA, Houk C, Ahmed SF, Lee PA. Consensus statement on management of intersex disorders. *Arch Dis Child*. 2006;91(7):554–563.
- Tanagho EA, McAninch JW, editors. *Smith's General Urology*. 17th ed. New York: McGraw-Hill Medical; 2008.
- Jong DM, Pulungan AB, Tridjaja B. 5-alpha-reductase deficiency: a case report. *Paediatr Indones*. 2003;43(11):234–240.
- Bashamboo A, McElreavey K. Consanguinity and disorders of sex development. *Hum Hered*. 2014;77(1–4):108–117.
- Vasundhera C, Jyotsna VP, Kandasamy D, Gupta N. Clinical, hormonal and radiological profile of 46,XY disorders of sexual development. *Indian J Endocrinol Metab*. 2016;20:300–307.
- Raza J, Zaidi SZ, Warne GL. Management of disorders of sex development with a focus on development of the child and adolescent through the pubertal years. *Best Pract Res Clin Endocrinol Metab*. 2019;33(3):101297.
- Allen L. Disorders of sexual development. *Obstet Gynecol Clin North Am*. 2009;36(1):25–45.
- Kumar G, Barboza-Meca JJ. 5-alpha-reductase deficiency. In: *StatPearls [Internet]*. Treasure Island (FL): StatPearls Publishing; 2025. Available from: <https://www.ncbi.nlm.nih.gov/books/NBK539904/>
- Balagamage C, Igbokwe R, Cole T. The diagnostic value of stimulated androgen ratios in 5-alpha reductase type 2 (SRD5A2) deficiency: a case series and review of the literature. *J Pediatr Endocrinol Metab*. 2025;38(9):922–930. doi:10.1515/jpem-2025-0195.
- McGee LM, Lin-Brandt M, Woods K, Seidman CA. Pubertal suppression and surgical management of a patient with 5-alpha reductase deficiency. *Urology*. 2022;165:e29–e31.
- Konishi A, Ida S, Matsui F, Etani Y, Kawai M. Male assignment in 5-reductase type 2 deficiency with female external genitalia. *Pediatr Int*. 2021;63(5):592–594.
- Wall E, Jayadev V. 5 α -reductase deficiency: a rare cause of ambiguous genitalia and gender dysphoria. *JCEM Case Rep*. 2024;2(11):luae191. doi:10.1210/jcemcr/luae191.
- Dan E, Rizqy R. Intersex justice in Indonesia: a country report on the situation of intersex rights in Indonesia. *Taiwan: Intersex Asia*; 2024.
- Tamarit J, García-Acero M, Ación P, Ación MI. Differences of sex development: common presentations and evaluation in children. *Children (Basel)*. 2022;11:110.



This work is licensed under a Creative Commons Attribution