

Case Report

SPECIALTY COLLABORATION IN MANAGING SCHOOL AGE CHILD WITH NASOFRONTAL MENINGOENCEPHALOCELE: A CASE REPORT

Yunia Tasya Salsabila¹, Sweety Pribadi², Lutfi Hendriansyah^{1,3}, Graciella Novian Triana Wahjoe Pramono^{1,2}

1. Faculty of Medicine, Pelita Harapan University, Karawaci, Indonesia

2. Division of Plastic Reconstructive and Aesthetic Surgery, Surgery Department, Siloam Hospital Lippo Village, Karawaci, Indonesia

3. Neurosurgery Department, Siloam Hospital Lippo Village, Karawaci, Indonesia

ABSTRACT

Introduction : Meningoencephalocele is one form of neural tube defect that forms a sac containing brain tissue, meninges, and cerebrospinal fluid (CSF). It can cause structural deformities and many other clinical symptoms that come after. Many medical consultations are needed for the case. The collaboration between neurosurgeon and plastic surgeon plays a significant role in managing this case.

Case Report : A case of a 10-year old boy with an apple-size lump in his nasofrontal region, nasal congestion, and central visual field disturbance. The patient has not undergone an examination or surgery in a long time because he lives in a rural area. Radiological results show herniation of brain tissue, meninges, and CSF protruding through the defect in the frontal bone of the cranium that suggest meningoencephalocele as a diagnosis.

Discussion : The definitive management for this case is through surgery. Selecting a surgical technique for meningoencephalocele is essential for optimizing the outcomes and minimizing the risks. The Chula technique approach was chosen for the implementation of this surgery. In this case, we describe the modified Chula technique with stages adjusted according to the patient's condition. Plastic surgery complements many aspects of reconstruction and restores aesthetic subunits. Managing this case was a challenge until the recovery period. The surgery was successfully performed, and patient went home without any serious complications.

Summary: Caution is necessary in handling surgery and involves aesthetic creativity within it. Long-term monitoring is necessary for post-operative results since many clinical aspects and social developments must be regularly evaluated.

Key Words: *Meningoencephalocele; Chula technique; Plastic surgery; Neurosurgery*

Pendahuluan: Meningoensefalokel adalah salah satu bentuk cacat tabung saraf yang membentuk kantung berisi jaringan otak, meninges, dan cairan serebrospinal (CSF). Kondisi ini dapat menyebabkan deformitas struktural dan berbagai gejala klinis lainnya yang muncul setelahnya. Penanganan kasus ini memerlukan banyak konsultasi medis. Kolaborasi antara ahli bedah saraf dan ahli bedah plastik memainkan peran penting dalam manajemen kasus ini.

Laporan Kasus: Seorang anak laki-laki berusia 10 tahun dengan benjolan seukuran apel di daerah nasofrontal, hidung tersumbat, dan gangguan lapangan pandang sentral. Pasien belum menjalani pemeriksaan atau operasi dalam waktu lama karena tinggal di daerah pedesaan. Hasil radiologi menunjukkan herniasi jaringan otak, meninges, dan CSF yang menonjol melalui defek pada tulang frontal kranium, yang mengarahkan pada diagnosis meningoensefalokel.

Diskusi: Penanganan definitif untuk kasus ini adalah melalui pembedahan. Pemilihan teknik pembedahan untuk meningoensefalokel sangat penting untuk mengoptimalkan hasil dan meminimalkan risiko. Pendekatan teknik Chula dipilih untuk pelaksanaan pembedahan ini. Dalam kasus ini, kami mendeskripsikan teknik Chula yang dimodifikasi dengan tahapan yang disesuaikan dengan kondisi pasien. Bedah plastik melengkapi banyak aspek rekonstruksi dan memulihkan subunit estetika. Menangani kasus ini menjadi tantangan hingga masa pemulihan. Pembedahan berhasil dilakukan, dan pasien dipulangkan tanpa komplikasi serius.

Kesimpulan: Kehati-hatian diperlukan dalam penanganan pembedahan yang melibatkan kreativitas estetika. Pemantauan jangka panjang diperlukan untuk mengevaluasi hasil pascaoperasi, karena banyak aspek klinis dan perkembangan sosial yang harus dipantau secara rutin.

Kata Kunci: *Meningoensefalokel; Teknik Chula; Bedah plastik; Bedah saraf*

Received: 07-11-2024, Revised: 13-12-2024, Accepted: 31-12-2024

Conflicts of Interest Statement:

The author(s) listed in this manuscript declare the absence of any conflict of interest on the subject matter or materials discussed.

INTRODUCTION

Meningoencephalocele is one form of neural tube defect (NTD). The exact causes and mechanisms of this disorder are not yet fully understood. However, most cases are congenital.^{1,2} Some others are due to secondary causes such as tumors, trauma, or iatrogenic injury.^{1,2} Other factors include genetics, infections such as TORCH (toxoplasmosis, rubella, cytomegalovirus, herpes simplex virus), a family history of NTDs, consanguineous marriages, and several other syndromes that may be related including Walker-Warburg syndrome, Meckel-Gruber syndrome, Fraser syndrome, Roberts syndrome, Knobloch syndrome, and amniotic band syndrome.^{1,2,3} The consumption of folic acid during pregnancy is also mentioned, but it is not entirely clear.^{1,2,3}

A clinical sign is a lump covered by skin, located along the midline in the anterior or posterior region of the head. In the anterior region, it is usually associated with the glabella, medial orbit, or nasal bridge.^{1,2} It can cause facial deformities depending on the size. Other clinical manifestations include disturbances in the visual field, hypertelorism, nasal obstruction, snoring, rhinorrhea, spasticity, CSF leakage, or meningitis. Hydrocephalus can occur in 40% to 60% of cases of posterior encephalocele.^{2,3} Seizures, although uncommon, but it can occur. Evaluation to support this diagnosis can be done with prenatal ultrasound, maternal DNA chromosome screening, and radiological features including magnetic resonance imaging (MRI) or computed tomography (CT) scan of the head.^{1,2,3}

The main goal of treating this condition is to repair the bone defect. The consideration for surgery is based on the age, etiology, location, size, midface abnormality, and the potential complications.^{1,4} The scars as a result of surgical intervention must also be considered from an aesthetic perspective, especially if the location of the anomaly is in the facial area. Craniofacial reconstruction is necessary, especially if there are any related deformities.^{1,4,5} Implementation of the treatment becomes a challenge in itself until the recovery period. The collaboration between neurosurgeon and plastic surgeon plays a significant role in managing this case. Plastic surgery complements many aspects of reconstruction and restores aesthetic subunits.^{1,5}

Below, we present a case with a diagnosis of meningoencephalocele and the treatment provided.

CASE REPORT

A 10-year-old boy came to the neurosurgery clinic with a complaint of a lump in the area of his nose. The lump has been present since birth, initially the size only as a marble, but it has started to grow larger over the past 5 years. Another complaint of the airways started to obstructed as the lump grew larger. Also the central field of vision narrowed obscured by the lump. The patient has not undergone an examination or surgery in a long time because he lives in a rural area. Medical history and family history are clear. Growth and development history are good. There are no barriers in memory and cognition. Maternal history has insufficient data.

On physical examination, an apple-size lump, approximately 10 cm x 10 cm x 11 cm is palpable in the frontonasal region, mobile with well-defined borders, and soft in consistency. Both visus are good, but the central field of vision is obstructed by a lump. There are no neurological deficits, and other examinations are within normal limits.

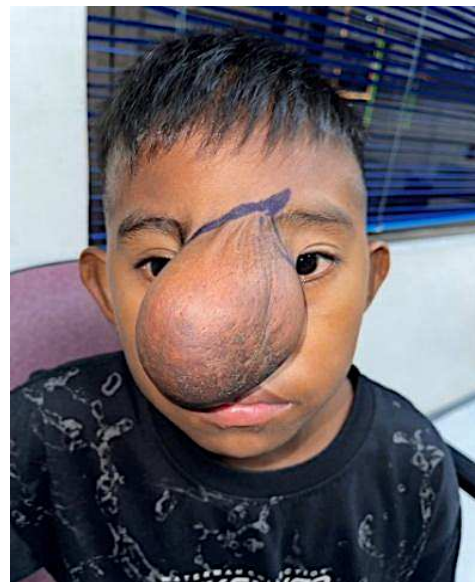

Figure 1. An image of the patient's clinical appearance from the front view.

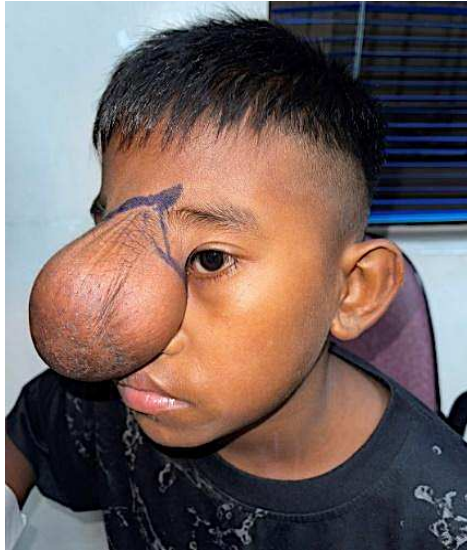

Figure 2. An image of the patient's clinical appearance from the left side.

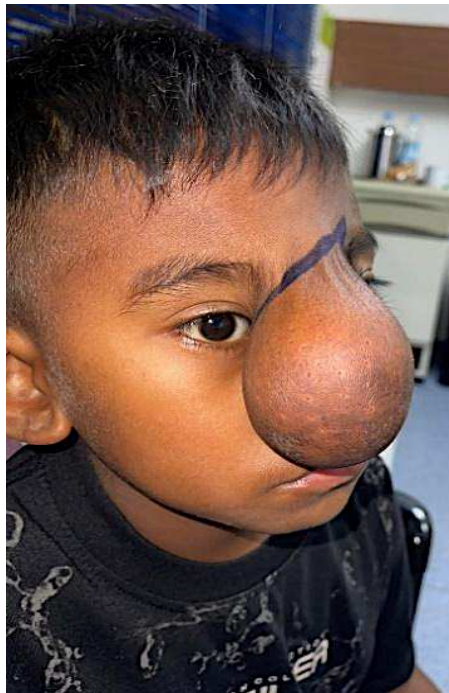

Figure 3. An image of the patient's clinical appearance from the right side.

The patient was then referred for supporting examinations including a complete blood count, liver function tests, kidney function tests, electrolytes, and bleeding coagulation tests. A head CT-Scan radiological examination has been conducted earlier at another hospital.

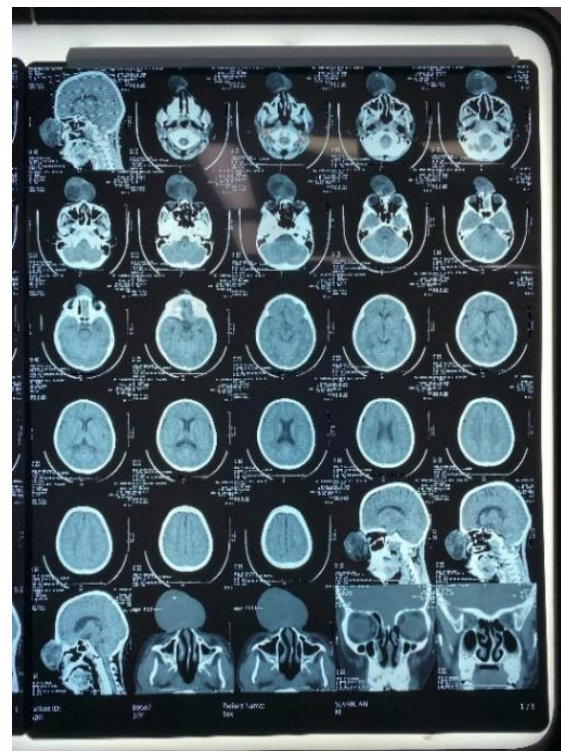
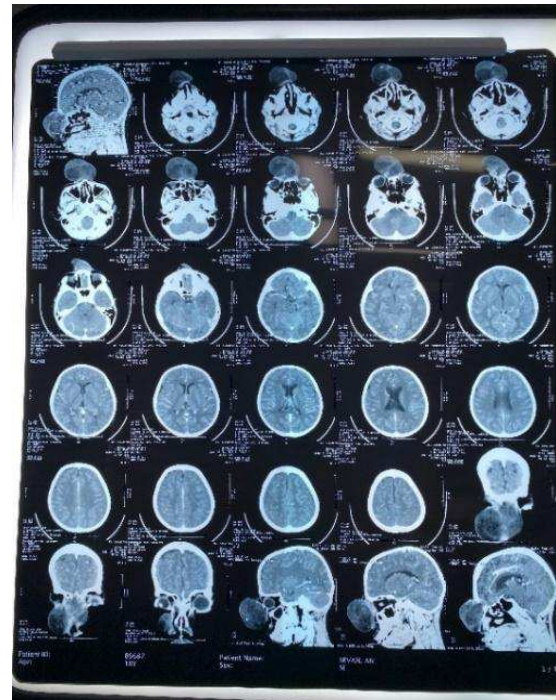


Figure 4 and 5. CT-Scan image show herniation brain tissue, meninges, and CSF protruding through the defect in the frontal bone of the cranium.

The patient's current diagnosis is meningoencephalocele. Resection of meningoencephalocele was performed by a neurosurgeon in collaboration with a plastic

surgeon. On the day of the surgery, the procedure was performed in 4.5 hours.

A few days after the operation, the patient reported any complaint about his sense of smell. He is unable to describe this complaint more clearly. The sense of smell is perceived to be more sensitive when detecting certain aromas. As a result of this, the patient admits to having a decreased appetite and feeling nauseous. The current suspect for the patient is experiencing dysosmia. He was then observed and underwent treatment for almost a week after the surgery. The patient was given antibiotics cefixime 200 mg twice a day oral, omeprazole 20 mg once a day oral, and multivitamins curcuma plus 10 ml once a day oral. Gentamicin ointment was also applied topically for postoperative wound. After a week, the symptoms of dysosmia are still present but with intermittent intensity. The patient's condition has improved, and their appetite is slowly returning. Patient's breathing is good and there is no obstruction in the airway. Patients are advised to continue receiving aroma stimulation and to be motivated to have a good food intake.

One year after the surgery. The patient is making good improvement. He is engaging in normal activities. Social, memory and cognition in schooling are good. The complaint of dysosmia is no longer present. The area of the patient's nose and face is healing well, there is a good regeneration of new tissue. The resulting scar is an acceptable type of scar, which is not a pathological scar that has significance for facial aesthetics.

DISCUSSION

Meningoencephalocele is one form of neural tube defect (NTD).¹ The neural tube defect is an abnormality that occurs due to the failure of the separation process of the ectoderm layer from the neuroectoderm, which occurs after the neural folds closure phase.^{1,2} Normally, the paraxial mesoderm will mediate the separation of these two layers and form the skull and meninges.^{1,2,3} Due to the defect, the paraxial mesoderm is unable to fulfill its process, resulting in the inadequate formation of the skull and meninges.^{1,2,3} Several other theories also mention other origin problems, such as incomplete closure of the cranial neuropore, or abnormal gene signaling from the neural tube.^{1,2,3} This defect will create a sac containing brain tissue, or meninges, or cerebrospinal fluid (CSF) formed outside through the defect.^{1,2,3,4} It is called meningocele if

the sac contains a protrusion of meninges and CSF.^{1,2,3,4} If it contains brain tissue, it is called encephalocele.^{1,2,3,4}

Hence, the primary objective of treating this condition is to repair the bone defect through surgery.⁴ It's important to consider what kind of surgery technique approach will be chosen.^{4,5} Meningoencephalocele can be excised using a closed surgery or open craniotomy.^{4,5,6} Each technique has its own style and level of complexity. This also relies on how the patient's condition. As a physician, we prefer to choose techniques which easier, minimally invasive, and with lower risk of complications.^{4,5,6}

In this patient, the Chula technique was used as a surgical approach. Chula technique is safer, more effective, has a high recovery rate, and offers good aesthetic outcomes.^{4,5} This technique is frequently selected and applied, particularly in frontoethmoidal encephalocele cases.^{4,5} Some references also mention that there is no mortality in this technique.^{4,7} This technique is more commonly chosen while open craniotomy is no longer necessary.^{4,7} Based on its history, the Chula technique is a flagship technique that is mostly used at King Chulalongkorn Memorial Hospital in Bangkok, Thailand.⁵ Named Chula to commemorate the king who founded the university and the local hospital foundation.⁵ It is known that the incidence rate of sincipital meningoencephalocele is higher in Southeast Asia compared to Western countries (especially Thailand, Cambodia, Burma, Rusia, and some regions in India).^{4,5,7}

There is an age consideration for this Chula technique.^{5,7} it is advisable to perform the operation when the patient is older than 3 months, while on this patient is already 10 years old.^{4,5,7} This technique is performed based on the nasal-coronal approach principle to remove mass herniation, repair dural and bone defects, reconstruct the medial orbital wall, the nasofrontal area and its surroundings, and restore aesthetic subunits for facial appearance in a single stage.^{4,5,8} It is not necessary to do an open craniotomy during any of these stages.^{4,5,8}

Step A (Nasal Approach) : Before the surgery, the plastic surgeon sketches the 'lazy-S' shape incision design on the patient's nose with skin surgical marker, as shown in figures 1 to 3. The first incision that will be made by the neurosurgeon is expected to follow the design that has been created, so the reconstruction of the skin tissue will be easier later on. The patient

received general anesthesia and was placed in a supine position for the intraoperative procedure. Draping is done in an aseptic, antiseptic, and sterile manner. Then a nasal incision is made in the skin. Continued with separate the skin tissue from the herniated mass by undermining dissection. The dissection process is carried out slowly. To prevent the dissection from entering the orbital tissue too deeply, this portion needs to be done carefully. Next, the excision begins from the neck of the cele area. After the herniated mass was removed, bleeding control of the wound was performed and the dura area was secured.

Step B (Closure of Bone Defect) : A skull defect measuring 1.5 cm was observed. Bone defects must be closed to prevent the future recurrence. A periosteum flap covering the duramater was used to seal the defect, this flap was sutured primarily with an overlap technique. Once the dura mater and periosteum were confirmed to be well stitched, the surgery continued by a plastic surgeon.

Step C (Nasal Augmentation) : Plastic surgeon continues the stages of the surgery. The initial stage begins with identifying the condition of the tissues that were intervened in the previous step. Nasal augmentation is carried out to improve the possibility of a flat nose after the intervention. This stage is performed using soft tissue remnants in the surrounding area of the intervention.

Step D (Medial Canthopexy) : Standard medial canthopexy is performed at this stage. The medial canthus is sutured with polypropylene and fixed to prevent deviation from its anatomical position.

Step E (Nasal Soft Tissue) : Undermining of the skin flap was performed, continued with stitching the muscle tissue. On the inside, absorbable poliglaktin 5.0 is used, while on the outside, non-absorbable polypropylene 5.0 is applied. Redesign is carried out to adjust the tissues that will be reconstructed. Because of the expansion effect, the skin covering the mass, shows signs of degeneration such as hyperpigmentation and hyperkeratosis. So the degenerated skin, excess and unused tissues should be removed as completely as possible. After excess skin and unused tissues are discarded, the process then continued by stitching the subcutis area with poliglaktin 5.0 and cutis area with polypropylene 6.0 according to the design that has been created. At the end of the procedure, the wound area is covered with a sterile strip and gauze.

The implementation of the Chula technique in this case has modified several steps from the general guidelines popularized by Charan Mahatumarat and colleagues.⁵ This is adjusted according to the patient's abnormal condition. In the guidelines, the general sequence of steps starts with the nasal approach, followed by the cranial approach, closure of the bone defect, nasal augmentation, medial canthopexy, and final nasal soft tissue approach.^{5,7,8}

The first step of the nasal approach has been carried out correctly. The 'lazy-S' shape incision is intended to relieve skin tension lines and match the local area's natural contour lines.^{5,7,8} Dissection and excision of the mass were also performed carefully to prevent damage to other anatomical areas.^{4,5} The aim of this stage is to remove as much damaged skin as possible.^{4,5}

The second step of the cranial approach involves creating a flap with a standard coronal incision, typically using a T-shaped bone segment osteotomy.⁵ Usually, the outer cortex of the frontal bones in the glabellar area and superior orbital rims will be cut.⁵ However, in this case, bone segment osteotomy was not performed because the defect in the patient was small, only 1.5 cm, so it could still be directly closed with a live flap from the surrounding tissue. According to references, osteotomy from several areas such as the pericranium and others becomes an option if repairing a dural defect with direct closure is not feasible.^{5,7,8} Since the defect can typically be covered enough, mesh or wire is also not used in this instance. The use of media such as wire is also feared will disrupt the development of tissues and bones, since the patient is still in their growth age.^{4,5,7}

The third step of nasal augmentation is performed in this case. In the guidelines, nasal augmentation is usually performed using a bone segment resected from the T-shaped bone osteotomy from the previous step.⁵ Another option is to use implant media.⁵ Since we want to make sure that there won't be a recurrence defect in the future, the implant in this case has not yet been used. This prevents the removal of the implant if a recurrence occurs. However, if the long-term prognosis is good, then the patient want to use implants for aesthetic purposes, it is permitted.^{5,9}

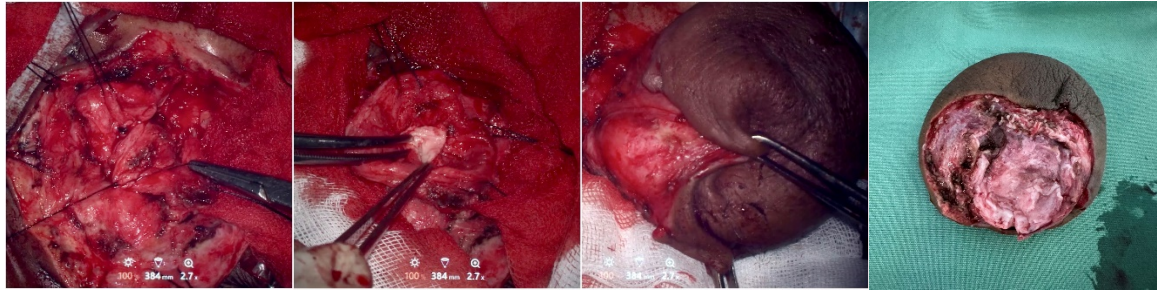


Figure 6-8. The process of cele resection. Figure 9. Meningoencephalocele that has been removed.

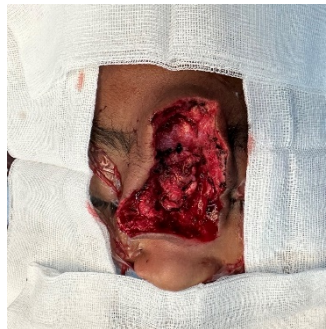

Figure 10. Defect area.

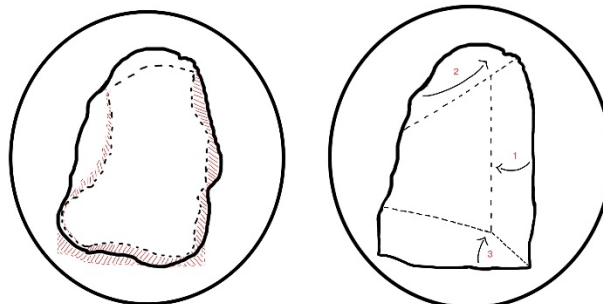


Figure 11. The skin tissue that has been removed for redesign is represented by the shaded area.

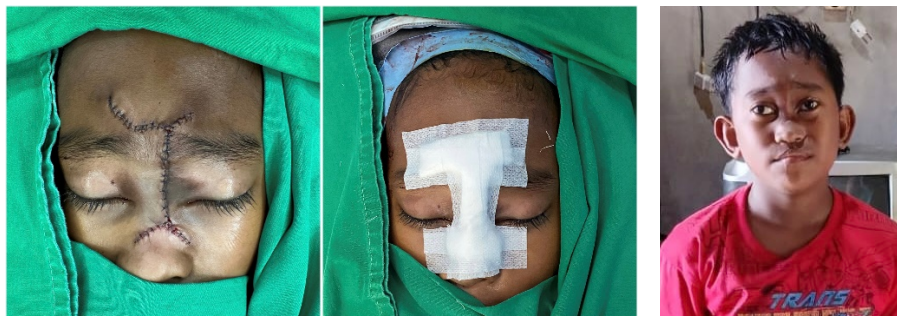

Figure 12-13. After the reconstruction by a plastic surgeon. Figure 14. One year after the surgery was performed. There are no visible pathological scars on the facial area.

Another step is canthopexy and the nasal soft tissue approach, which in this case is performed according to general guidelines.⁵ Postoperative follow-up focuses on neurological signs and symptoms, recurrence, aesthetic

outcomes, functional problems, and social life.^{5,7,8} A good evaluation must be conducted regularly and takes a considerable amount of time, especially when considering the potential for bone defect recurrence. It is necessary to assess

whether the closure of the defect has been adequately performed. The follow-up focus should be evaluated at least within 6 months to 1 year after the surgery.^{5,7,8} This aligns with the physiology of tissue repair and bone regeneration as well.^{1,5,10} As mentioned in the result section above, the follow-up outcome for this patient is good.

In general theory, the exact causes of dysosmia are not yet clear. The nearest option in this case is a transient inflammatory response. The patient's complaints also only lasted a short time. Ideally, for comprehensive management of patients with meningoencephalocele, examinations such as ENT, visual field testing, and others should be conducted. However, the supporting examinations that can be assessed for this patient are limited due to insurance coverage and the patient's administrative matters at our private hospital. Some of the examinations conducted are more crucial for definitive management.

SUMMARY

Caution is necessary in handling surgery and involves aesthetic creativity within it. Long-term monitoring is necessary for post-operative results since many clinical aspects and social developments must be regularly evaluated.

Correspondence regarding this article should be addressed to:

Yunia Tasya Salsabila . Faculty of Medicine, Pelita Harapan University, Karawaci, 15810, Indonesia.
E-Mail: yuniatasya25@gmail.com

ACKNOWLEDGEMENT

We thank all the hospital staff, especially operating room team, the nursing team, and others at Siloam Hospital Lippo Village who were involved in patient care so well.

REFERENCES

1. Matos Cruz AJ, De Jesus O. Encephalocele. [Updated 2023 Sep 4]. In: StatPearls [Internet]. Treasure Island (FL): StatPearls Publishing; 2024 Jan-. Available from: <https://www.ncbi.nlm.nih.gov/books/NBK562168/>
2. Levene MI, Chervenak FA. Fetal and Neonatal Neurology and Neurosurgery. Elsevier Health Sciences, 2009. p. 233-852
3. Armstrong D, Halliday W, Hawkings C, Takashima S. Pediatric Neuropathology: A Text-Atlas. Springer Science & Business Media, 2008. p. 16-17
4. Buchanan EP. Pediatric Craniofacial Surgery: State of the Craft. Clinics in Plastic Surgery. Elsevier Health Sciences [Internet]. 2019 Apr; 46 (2): 185-198. Available from: [http://dx.doi.org/10.1016/s0094-1298\(19\)30003-3](http://dx.doi.org/10.1016/s0094-1298(19)30003-3)
5. Mahatumarat C, Rojvachiranonda N, Taecholarn C. Frontoethmoidal Encephalomeningocele: Surgical Correction by the Chula Technique. Plastic & Reconstructive Surgery [homepage on the Internet] 2003;111(2):556-565. Available from: <https://doi.org/10.1097/01.prs.0000040523.57406.94>
6. Suryaningtyas, W., Sabudi, I.P.A.W. & Parenrengi, M.A. The extracranial versus intracranial approach In frontoethmoidal encephalocele corrective surgery: a meta-analysis. *Neurosurg Rev* 45, 125-137 (2022). <https://doi.org/10.1007/s10143-021-01582-6>
7. Lumintang LM, Nirvana IW, Sanjaya H, Hamid AR. Three Years Follow-Up of Single-Stage Correction with Modified Chula Technique for Frontoethmoidal Encephalomeningocele: The Advantage of The Teamwork Approach (A Case Report). Jurnal Plastik Rekonstruksi [homepage on the Internet] 2021;8(2):76-83. Available from: <https://doi.org/10.14228/jprjournal.v8i2.324>
8. Jeyaraj P. Management of the frontoethmoidal encephalomeningocele. *Annals of Maxillofacial Surgery* [Internet] 2018;8(1):56. Available from: https://doi.org/10.4103/ams.ams_11_18
9. Holm C, Thu M, Hans A, et al. Extracranial Correction of Frontoethmoidal Meningoencephaloceles: Feasibility and Outcome in 52 Consecutive Cases. *Plastic & Reconstructive Surgery* [Internet] 2008;121(6):386e-395e. Available from:

<https://doi.org/10.1097/prs.0b013e318170a78b>

10. Hoz SS, Al Ramadan AH, Pople I, Mohammed N, Hamouda WO, El Damaty A, et al., editors. Pediatric Neurosurgery (Internet]. Springer Nature Switzerlan; 2023. Available from: <http://dx.doi.org/10.1007/978-3-031-49573-1>