

## Anesthesia Management for Epilepsy Surgery with Total Intravenous Anesthesia: A Case Report

Riyadh Firdaus, Clarissa Emiko Talitaputri

Department of Anesthesiology and Intensive Care, Faculty of Medicine Universitas Indonesia, Cipto Mangunkusumo General Hospital, Jakarta, Indonesia

Received: Octobre 03, 2024; Accepted: February 12, 2025; Publish: February 22, 2024

Correspondence: riyadh.firdaus@ui.ac.id

### Abstract

**Background:** Epilepsy is a neurological disorder characterized by recurrent seizures, affecting many aspects of life. Approximately 30–40% of patients do not respond to antiepileptic medications, making surgery a crucial option. While only 10–30% of these patients qualify for surgical intervention, procedures like temporal lobectomy are becoming more common. Anesthetic management is essential for intraoperative mapping of the epileptogenic focus. This case report discusses anesthetic strategies in elective epilepsy surgery. **Case:** A 55-year-old man with recurrent seizures was scheduled to undergo temporal lobectomy with amygdala-hippocampectomy. The patient was classified as American Society of Anesthesiologists (ASA) class 2 without sign of increased intracranial pressure and there was no plan to use intraoperative functional monitoring or intraoperative electroencephalogram by the surgeon, as the epileptogenic focus could be identified through previous functional magnetic resonance imaging (fMRI). The patient underwent general anesthesia with total intravenous anesthesia (TIVA) using a combination of propofol, remifentanyl, and rocuronium. Depth of anesthesia was monitored using the Bispectral Index (BIS). There were no significant hemodynamic fluctuations intraoperatively, except for bradycardia during manipulation of the limbic system. The patient was extubated at the end of the operation and there were no seizures during postoperative monitoring. **Conclusion:** In epilepsy surgery, it is important to understand if intraoperative electrocorticography is planned, the impact of anesthetic drugs on epilepsy, brain protection management, hemodynamics, and early neurological function assessment postoperatively. The use of TIVA, along with adequate monitoring of the depth of anesthesia, is safe and beneficial for assessing neurological function early.

**Keywords:** Anesthesia management, epilepsy surgery, general anesthesia, total intravenous anesthesia

J. neuroanestesi Indones 2025;14(1): 41–6

### Introduction

Epilepsy is a condition characterized by neurological dysfunction with manifestations of focal or generalized seizure episodes. This condition can cause disturbances in social, economic, and intellectual aspects, as well as general health status. Although there are many antiepileptic drug options currently available, approximately 30–40% of epilepsy cases do not respond to medical treatment. Epilepsy surgery is one of the treatments for patients with seizures resistant to antiepileptic drugs. However, only about 10–30% of patients

with seizures refractory to pharmacological treatment are suitable candidates for epilepsy surgery, and only 1% of these patients will undergo the procedure.<sup>1</sup> To optimize surgical outcomes for individuals with epilepsy, it is imperative to select appropriate anesthetic agents and meticulously time and manage antiepileptic drugs. Maintaining antiepileptic drug at therapeutic concentrations throughout the perioperative phase is essential because abrupt cessation of these medications can precipitate an increase in seizure frequency or intensity.<sup>2</sup> In Indonesia, epilepsy surgery began in July 1999,

doi: <https://doi.org/10.24244/jni.v14i1.649>

ISSN (Print): 2088-9674 ISSN (Online): 2460-2302

This is an open access article under the CC-BY-NC-SA licensed: <https://creativecommons.org/licenses/by-nc-sa/4.0/>

JNI is accredited as Sinta 2 Journal: <https://sinta.kemdikbud.go.id/journals/profile/796>

Riyadh Firdaus, Clarissa Emiko Talitaputri Copyright ©2025

How to cite: Firdaus R, et al, " Anesthesia Management for Epilepsy Surgery with Total Intravenous Anesthesia: A Case Report".

and there has been an increase in cases performed each year. In this procedure, resection of the epileptogenic focus can be performed to reduce the risk of seizures through neuromodulation. While many alternative surgical techniques, such as vagus nerve stimulation and thalamic deep brain stimulation, are currently being used, surgery involving resection of seizure foci—such as temporal lobectomy via craniotomy—is still the most frequently performed procedure.<sup>1</sup> Thus, in this case, selecting appropriate anesthetic management is essential, considering that the operator will often need intraoperative mapping to identify the epileptogenic focus and normal tissue during surgery. There are various anesthetic agents available, and in this case, the anesthesiologist needs a sufficient understanding of the drugs to be used, particularly regarding their proconvulsant and anticonvulsant effects, as well as their interactions with the antiepileptic drugs taken by the patient.<sup>1,4</sup> A good understanding and communication with surgeons and neurologists are required in preparing the patient's anesthesia management to achieve optimal intraoperative outcomes. Therefore, we report the anesthetic management of a patient undergoing elective epilepsy surgery

## Case

### History

The patient in this case is a 55-year-old male presenting with a primary complaint of recurrent seizures that began two months prior to his admission to the hospital. The patient experienced his first seizure two months ago, characterized as tonic-clonic in nature, lasting approximately five minutes. The seizures recurred, and the patient reported experiencing headaches in the postictal phase. He is currently on medication consisting of levetiracetam (750 mg twice daily), phenytoin (100 mg three times daily), and dexamethasone (3 mg twice daily).

### Anesthesia Management

The patient was classified as American Society of Anesthesiologists (ASA) Class 2 with a left temporal tumor suspected to be a low-grade glioma, and no airway complications. General

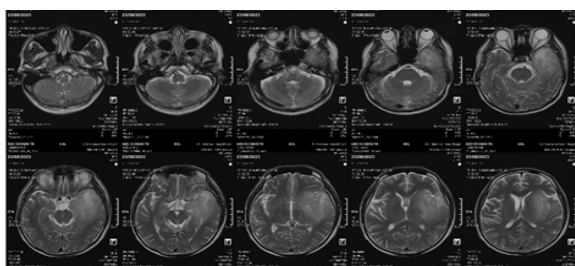
## Supporting Examination

**Table 1 . Supporting Examination**

Laboratory examination	Hemoglobin 14.1 g/dL, Hematocrite 40.9%, Leukocyte 16.430/ $\mu$ L, Thrombocyte 219.000/ $\mu$ L Natrium 141 mEq/L, Potassium 3.5 mEq/L, Chloride 104 mEq/L PT 9.9/11.9 APTT 29.1/33.3 AST 18 U/L, ALT 33 U/L Glucose 156 mg/dL
Chest Xray	Within normal limit
MRI brain with contrast	Defined lesion in the left temporal area to the left insula area with extensive vasogenic edema in the left temporal, from ganglia, showing minimal enhancement and mass effect causing blurring of the cortical - white matter boundaries. Left cephalic, suggestive of tumor mass (suspicious low grade glioma DD lymphoma). The lesion appears to be pressing on the left lateral ventricle but without midline deviation. Bilateral maxillary sinusitis.

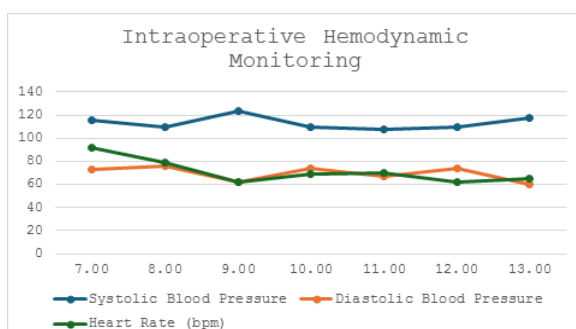
anesthesia was planned, including endotracheal intubation, administration of local anesthesia via scalp block prior to Mayfield frame installation, and insertion of an arterial line to facilitate invasive intraoperative hemodynamic monitoring. Before induction, it was ensured that the intravenous access was patent and that standard monitoring, including Bispectral Index (BIS), was installed on the patient. Preoxygenation was carried out for 5 minutes, followed by the administration of 80 mg of lidocaine and 150 mcg of fentanyl. A sedative agent, propofol, was then titrated, with a total of 100 mg administered. Afterward, 40 mg of rocuronium was given, and ventilation was continued for up to 3 minutes before intubation with an endotracheal tube (ETT) No. 7.5. The patient then underwent a scalp block with 0.375% ropivacaine. Two 18G intravenous accesses were established, and an arterial line was inserted after induction. Subsequently, the

Mayfield pin was installed in collaboration with the operator before placing the patient in the reverse trendelenburg position (Figure 1). Intraoperative Anesthesia

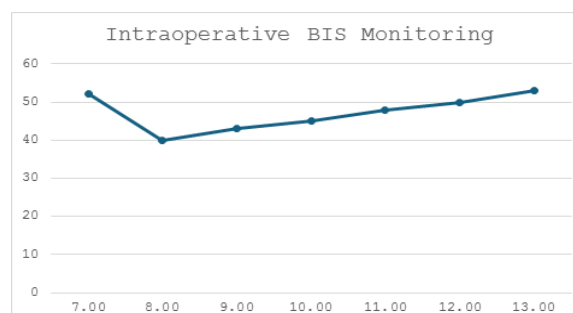


**Figure 1. MRI brain with contrast show epileptogenic tumor, suspected low grade glioma with differential diagnosis lymphoma**

During intraoperative maintenance, anesthesia was administered using target-controlled infusion (TCI) propofol (Schneider model) at a concentration of 2-5.5 mcg/ml and TCI Remifentanyl (Minto model) at a concentration of 2-4 mcg/ml. The BIS value was monitored to remain within the range of 40-60, while the end-tidal carbon dioxide (EtCO<sub>2</sub>) was maintained between 30-35 mmHg. There were two episodes of bradycardia during the procedure, with the pulse rate decreasing to 30-40 beats per minute during manipulation of the amygdala and hippocampus, which improved once the manipulation was ceased. Overall, the patient's condition remained stable, with no significant hemodynamic changes observed intraoperatively (Figure 1). At the end of the procedure, after the removal of the Mayfield pin, the patient's airway secretions were suctioned. Propofol and remifentanyl were then discontinued after the Mayfield pin was taken off. Once the patient began to breathe spontaneously, extubation occurred with remifentanyl reduced



**Figure 1. Intraoperative Hemodynamic Monitoring**



**Figure 2. Depth of Anesthesia monitoring using BIS Intraoperative**

to 1 mcg/ml. The time from discontinuation of medication to the patient waking up and being able to follow commands was approximately 10 minutes. The total duration of anesthesia for the patient was 400 minutes. Total blood loss was 100 ml, and 2000 ml of crystalloid fluid was administered. Throughout the intraoperative period, the patient's condition remained stable, with a urine output of 3.8 ml/kg body weight per hour.

### Postoperative Management

The patient was then monitored further in the high care unit (HCU) after surgery. There were no seizures during the operation, and the patient reported no complaints of nausea or vomiting. The patient exhibited good orientation and had no memory problems. While in the HCU, the patient's condition remained stable, allowing for transfer to the ward on the first postoperative day. The patient was discharged from the hospital on the third postoperative day.

### Discussion

Epilepsy surgery can be performed under general anesthesia or under local anesthesia with sedation. The primary objective of epilepsy surgery is to resect the epileptogenic focus or interrupt the electrical pathways responsible for seizures. In this case, the surgery involved temporal lobectomy and amygdalohippocampectomy, but other techniques may also be employed, including excision of the extratemporal cortex, hemispherectomy, corpus callosotomy, vagal nerve stimulation, and electrical stimulation of the centromedian thalamus.<sup>1,7</sup> Resection of the epileptogenic focus may sometimes

require cortical mapping or intraoperative electrocorticography (ECoG) evaluation, especially in cases of temporal lobe epilepsy. If this is performed, it generally necessitates adjustments in the depth of anesthesia by an anesthesiologist to facilitate pharmacostimulation for identifying the epileptogenic focus. However, in this case, the location of the epileptogenic focus was determined preoperatively using magnetic resonance imaging (MRI) and electroencephalogram (EEG) diagnostic modalities, so this step was not necessary. In this patient, the anterior temporal lobe was resected along with the amygdala and a portion of the hippocampus. This procedure can significantly reduce seizure activity compared to standard therapy. It is important to communicate to patients and their families the potential for memory impairment, which can occur in 25% of cases.<sup>1,4,6</sup>

The patient underwent general anesthesia using total intravenous anesthesia (TIVA), along with central venous access and intra-arterial access. Close monitoring of the patient's hemodynamics was conducted using both standard non-invasive and invasive monitoring techniques. Additionally, the depth of anesthesia was assessed using processed EEG, specifically the Bispectral Index (BIS). Considering the changes in neuronal transmission associated with anesthetic agents, it is clear that the drugs used in anesthesia can significantly affect the central nervous system, exhibiting both anticonvulsant and proconvulsant effects. The mechanisms underlying these effects are still contradictory and not yet fully understood. The ratio of excitatory to inhibitory neurons alters with the depth of anesthesia; as anesthesia deepens, alpha waves in the EEG are replaced by beta wave activity, which progressively transitions to low-frequency theta and delta waves of high amplitude.<sup>6,7</sup> In the anesthetic management of patients undergoing epilepsy surgery, it is essential to focus on providing brain protection, maintaining intracranial pressure, and avoiding increases in intracranial pressure. Additionally, it is important to manage refractory seizures should they occur intraoperatively and to strive for a rapid postoperative recovery, enabling early

assessment of the patient's neurological status.<sup>7</sup>

#### Preoperative Management

Patients with epilepsy typically take antiepileptic drugs prior to surgery, making it crucial to document the medications the patient is using and advise them to continue taking these drugs up to the day of the surgery, unless intraoperative ECoG is planned. In this case, there was no intention to use ECoG, so the antiepileptic drugs were continued. However, patients on antiepileptic medications must be monitored for potential side effects, including dysnatremia, thrombocytopenia, leukopenia, and liver function disorders due to long-term use. Therefore, during preoperative preparation, the patient should undergo a comprehensive evaluation that includes a complete hematological examination, assessment of kidney and liver function, and electrolyte levels.

Antiepileptic drugs also function by blocking sodium channels in cells, which can lead to dysnatremia and may be associated with electrocardiography (ECG) abnormalities, such as Brugada-type ST segment changes and J waves. Consequently, a preoperative ECG should be performed. In this case, the patient was using the routine antiepileptic drugs Levetiracetam and Phenytoin, both of which act on sodium channels; however, the ECG and electrolyte examinations did not reveal any abnormalities. Given the patient's history of refractory seizures, we recommend that the patient continue using their antiepileptic drugs until just before surgery.<sup>1,5,7,8</sup>

#### Intraoperative Management

During intraoperative surgery, it is crucial to maintain adequate cerebral perfusion pressure (CPP) and avoid increasing intracranial pressure throughout the procedure. In this case, the surgery was performed under general anesthesia using total intravenous anesthesia (TIVA) with propofol and remifentanyl. Propofol possesses antiepileptic effects due to its inhibition of GABA-mediated chloride channels at both pre and post synaptic levels. We opted for TIVA and avoided inhalational anesthetic agents, as some inhalants, particularly under hypocapnic conditions, can trigger seizures

(for example, enflurane). Although sevoflurane could be used with caution, concentrations above 1.5 MAC and hypocapnic conditions should be avoided due to the dose-dependent risk of non-specific seizure activation associated with this agent. We also established large peripheral venous access and inserted arterial lines for invasive hemodynamic monitoring; central venous catheter (CVC) insertion was generally not required. During patient positioning, it is important to ensure that there is no excessive head rotation, which could obstruct cerebral venous drainage through the jugular vein.<sup>1,4,6</sup>

Induction in patients was carried out using propofol sedation, which has an anticonvulsant effect. The patient was also administered the opioid analgesic fentanyl (150 mcg) and lidocaine (80 mg). In these patients, long-term use of antiepileptic drugs can lead to resistance to muscle relaxants, necessitating a higher dose. The use of medications such as phenytoin and carbamazepine is associated with resistance to the effects of non-depolarizing neuromuscular blockers, such as rocuronium and vecuronium, although the resistance effect is lower with atracurium. However, caution must be exercised when using atracurium in patients with epilepsy due to the presence of laudanosine metabolites, which have the potential to be epileptogenic.<sup>4,7</sup>

The procedure for installing Mayfield pins involves a sufficiently large nociceptive stimulus; therefore, it is essential to ensure that the patient is at an adequate depth of anesthesia. Alternatively, an opioid bolus and a regional block, such as a scalp block, may be administered before placing the pins on the patient.<sup>4,7</sup> Intraoperatively, the patient received remifentanyl as an analgesic. Alfentanil, fentanyl, sufentanil, and remifentanyl are all opioids with a short duration of action and minimal effects on the cortex when administered via continuous infusion. The use of fentanyl has been associated with epileptiform electrical activity in non-ictal subcortical tissue; however, its epileptogenic properties appear to manifest at relatively high doses, ranging from 17 to 25 mcg/kg body weight. Remifentanyl can increase spike wave activity in the interictal focus when a bolus

of 1 mcg/kg body weight is used, potentially facilitating the identification of the ictal cortex location.<sup>4,7,9</sup> In epilepsy surgery, intraoperative ECoG or intraoperative functional monitoring can generally be utilized. In cases that require intraoperative monitoring, it is crucial to consider the drugs used during anesthesia. However, in this case, the location of the epileptiform focus was determined by the operator using functional Magnetic Resonance Imaging (fMRI), so the patient did not undergo intraoperative monitoring.<sup>1,4</sup> One of the key concerns during surgery for patients with epilepsy is the occurrence of intraoperative seizures. Several risk factors for these seizures include young age, new seizure activity occurring before surgery, lesions in the frontal and parietal areas, and the presence of oligodendroglioma tumors as the underlying cause of epilepsy. In epileptic patients under general anesthesia, clinical manifestations may include tachycardia, hypercarbia, pupil dilation, and muscle rigidity. If processed EEG monitoring, such as intraoperative BIS, is utilized, fluctuations in the BIS values can be observed during a seizure by closely monitoring the display.

#### Postoperative Management

Patients with epilepsy, particularly those who have been taking antiepileptic drugs regularly, generally experience a slower emergence time compared to non-epileptic patients. This is especially true for patients receiving Phenytoin intraoperatively, as delayed emergence may occur. In this case, no additional antiepileptic drugs were administered during the operation, and after discontinuing remifentanyl and propofol, the patient began to awaken within 10 minutes. The patient was subsequently extubated in the operating room and monitored further in the HCU. Postoperatively, the patient's neurological status was assessed. One potential complication is postoperative seizures, along with intracranial bleeding, which can occur in a small number of patients. Therefore, it is essential to closely monitor neurological status and to avoid coughing and postoperative systemic hypertension. Additionally, neurological complications that may arise following temporal lobe resection surgery

include memory impairment and visual field deficits. As such, it is important to closely monitor hemodynamic conditions and neurological status in the HCU. During the first 24 hours in the HCU, the patient's monitoring did not reveal any new neurological deficits or postoperative seizures. The patient was then transferred to a regular ward after 24 hours in the HCU and was discharged home after 2 days of treatment in the ward.

### Conclusion

In epilepsy surgery involving the resection of the epileptogenic focus, it is important to consider whether intraoperative electrocorticography will be used, the effects of anesthetic drugs on epilepsy, brain protection strategies, the management of hemodynamics, and the prevention of increased intracranial pressure. Additionally, ensuring rapid postoperative recovery is essential for the early assessment of neurological function. The use of total intravenous anesthesia (TIVA), along with adequate monitoring of anesthesia depth, is safe and beneficial for early neurological evaluation.

### Abbreviations

ASA, American Society of Anesthesiologists (ASA); BIS, Bispectral Index; ETT, endotracheal tube; TCI target controlled infusion; EtCO<sub>2</sub>, end-tidal carbon dioxide; HCU, high care unit; ECoG, electrocorticography; MRI, magnetic resonance imaging; EEG, electroencephalogram; TIVA, total intravenous anesthesia; CVC, central venous catheter; SSEPs, somatosensory evoked potentials; MEPs, motor evoked potentials; fMRI, functional Magnetic Resonance Imaging.

### Acknowledgments

We thank the neurosurgery team and nursing staff for their invaluable support and collaboration during the patient's care.

### Disclosure

The authors report no conflicts of interest in this work.

### References

1. Schubert A, Lotto M. Awake craniotomy, epilepsy, minimally invasive, and robotic surgery. In: Cottrell JE, Young WL. Eds, Cottrell and Young's Neuroanesthesia. 6th ed. 2010, 296–316. Doi: <https://doi.org/10.1016/B978-0-323-05908-4.10022-3>
2. Perks A, Cheema S, Mohanraj R. Anaesthesia and epilepsy. *Br J Anaesth.* 2012; 108(4), 562–71. Doi: 10.1093/bja/aes027
3. Gupta N. Anesthesia for Epilepsy Surgery. 2017, 285–307. Doi: <https://doi.org/10.1016/B978-0-12-805299-0.00016-6>
4. Shetty A, Pardeshi S, Shah VM, Kulkarni A. Anesthesia consideration in epilepsy surgery. *Int J Surg.* 2016; 36(Pt B): 454–59. Doi: 10.1016/j.ijssu.2015.07.006
5. Larkin CM, O'Brien DF, Maheswari D. Anesthesia for epilepsy surgery. *BJA Educ.* 2019. 19(12): 383–89. Doi: 10.1016/j.bjae.2019.08.001
6. Perks A, Cheema S, Mohanraj R. Anesthesia and epilepsy. *Br J Anaesth.* 2012;108(4): 562–71. Doi: 10.1093/bja/aes027
7. Bajwa SJS, Jindai R. Epilepsy and nonepilepsy surgery: recent advancement in anesthesia management. *Anesth Essays Res.* 2013; 7(1): 10–7. Doi: 10.4103/0259-1162.113978
8. Bhagat H, Dash HH. Anaesthesiologist's role in the management of an epileptic patient. *Indian J Anaesth.* 2006;50(1):20–26.
9. Maranhao MV, Gomes EA, de Carvalho PE. Epilepsy and anesthesia. *Rev Bras Anesthesiol.* 2011;61(2):232–41. Doi: 10.1016/S0034-7094(11)70028-9
10. Power KN, Flaatten H, Gilhus NE, Engelsen BA. Propofol treatment in adult refractory status epilepticus. Mortality risk and outcome. *Epilepsy Res.* 2011;94(1):53–60. Doi: 10.1016/res.2011.01.006