

Response of narrowband ultraviolet-B phototherapy in pityriasis lichenoides-like mycosis fungoides: a case report

Silvia Rakhmadani¹, Kirantri Larasati¹, Ardisa Pramudita¹, Paranita Ferronika², Flandiana Yogianti¹, Arief Budiyo^{1*}

¹Department of Dermatology and Venereology, Faculty of Medicine, Public Health, and Nursing, Universitas Gadjah Mada/Dr. Sardjito Hospital, ²Department of Pathological Anatomy, Faculty of Medicine, Public Health, and Nursing, Universitas Gadjah Mada/Dr. Sardjito General Hospital, Yogyakarta, Indonesia

<https://doi.org/10.22146/inajbcs.v58i2.27461>

ABSTRACT

Submitted: 2025-12-28
Accepted : 2026-03-26

Mycosis fungoides (MF) is a cutaneous T-cell lymphoma that often mimics other dermatological conditions, particularly in early stages. One rare subtype is pityriasis lichenoides-like mycosis fungoides (PL-like MF), which clinically resembles pityriasis lichenoides but demonstrates the histopathological features of MF, sometimes with overlapping characteristics. The management of MF varies according to disease stage, with skin-directed therapies, including narrowband ultraviolet B (NB-UVB) phototherapy, frequently used in early stages. A case is reported of a 28-year-old woman who presented with papules and erythematous patches on the trunk, arms, and legs that had worsened over two years. Histopathological examination of the skin biopsy confirmed PL-like MF. Initial treatment with topical corticosteroids for two months resulted in suboptimal improvement. The patient subsequently underwent 37 sessions of NB-UVB phototherapy with a cumulative dose of 58,764 mJ/cm². Pityriasis lichenoides-like MF is a rare variant of MF that poses diagnostic challenges. The management of MF is tailored to the disease stages. In early stages, skin-directed therapies (SDTs) are preferred, whereas in advanced or refractory MF, systemic therapy combined with SDTs is required. Narrowband UVB phototherapy is considered a safe and effective therapeutic option for early-stage MF, with mechanisms involving immunomodulation and induction of apoptosis in atypical lymphocytes. In this case, the patient demonstrated 87% clinical improvement following NB-UVB therapy, consistent with reports. Long-term follow-up is necessary to assess sustained remission and potential relapse.

ABSTRAK

Mycosis fungoides (MF) adalah jenis limfoma sel T kulit yang seringkali meniru berbagai penyakit kulit lainnya, terutama pada stadium awal. Salah satu sub tipe langka adalah *pityriasis lichenoides-like mycosis fungoides* (PL-like MF), yang menyerupai pitiriasis likenoides secara klinis namun memiliki karakteristik histopatologi MF, kadang dengan gambaran yang tumpang tindih. Penatalaksanaan MF bervariasi tergantung pada stadium, dengan terapi *skin-directed*, termasuk fototerapi *narrowband ultraviolet B* (NB-UVB), sering digunakan pada stadium awal. Sebuah kasus dilaporkan dari seorang wanita 28 tahun yang mengeluhkan bintil dan bercak kemerahan pada badan, lengan, dan tungkai yang memburuk selama dua tahun. Pasien dilakukan biopsi kulit dengan hasil PL-like MF. Setelah dilakukan terapi kortikosteroid topikal selama 2 bulan tidak ada perbaikan optimal, pasien kemudian menjalani fototerapi NB-UVB sebanyak 37 sesi dengan dosis kumulatif 58.764 mJ/cm². *Pityriasis lichenoides-like* MF merupakan varian MF langka yang sulit didiagnosis. Tatalaksana MF disesuaikan dengan stadium penyakitnya. Pada stadium awal, terapi menggunakan *skin directed therapies* (SDTs). Untuk stadium lanjut atau MF refrakter, diperlukan terapi sistemik yang dikombinasikan dengan SDTs. Fototerapi NB-UVB adalah pilihan terapi yang aman dan efektif untuk MF stadium awal dengan mekanisme yang melibatkan imunomodulasi dan induksi apoptosis sel limfosit atipikal. Dalam kasus ini, pasien menunjukkan perbaikan klinis sebesar 87% setelah terapi NB-UVB, sesuai dengan laporan yang ada. Pemantauan jangka panjang diperlukan untuk menilai remisi berkelanjutan dan potensi kekambuhan.

Keywords:

Mycosis fungoides;
Pityriasis lichenoides-like mycosis fungoides;
Phototherapy;
Narrowband ultraviolet B;
Skin-directed therapy

INTRODUCTION

Mycosis fungoides (MF), the most common variant of cutaneous T-cell lymphoma (CTCL), is characterized by cutaneous infiltration of atypical T cells that subsequently lead to lesion formation.^{1,2} Early lesions typically appear as persistent erythematous patches that may remain for years before progressing to plaques, nodules, erythroderma, or tumors.¹ This disease is known as the “great imitator” because of its broad clinical spectrum and nonspecific histopathological features, particularly in early stages when it can resemble other dermatologic conditions such as pityriasis lichenoides.² One rare subtype of MF is pityriasis lichenoides-like mycosis fungoides (PL-like MF), which shows clinical features similar to pityriasis lichenoides. This subtype is not only rare but also presents significant diagnostic and therapeutic challenges.¹

The total incidence of CTCL is 10.2 per one million individuals. Mycosis fungoides constitutes more than half of these cases, with an incidence of 5.6 per one million. Men are affected more often than women, reflected by an IRR of 1.6. The incidence rate escalates with age, reaching a peak in persons older than 70 years.³ The incidence of PL-like MF remains uncertain due to its rarity and diagnostic difficulty.² The etiology of MF remains unclear, but several hypotheses have been proposed, including the role of genetic, environmental, and immunological factors.⁴

The management of MF is stage dependent. Early-stage disease is primarily treated with skin-directed therapies (SDTs), including topical corticosteroids, phototherapy, topical chemotherapy or retinoids, and radiotherapy, aiming to control lesions while minimizing adverse effects. Advanced or refractory cases require systemic therapy, alone or combined with SDTs.^{5,6} Phototherapy is frequently used as a mainstay of treatment in patients with MF and often results in remission with variable duration. Narrowband ultraviolet-B (NB-UVB) has become the

preferred modality for early-stage MF, including PL-like MF, due to its favorable safety profile, lower carcinogenic risk compared with PUVA, and greater convenience without the need for photosensitizers.^{6,7} Although PL-like MF is uncommon and only a limited number of cases have been reported, Amin *et al.*,⁸ described significant improvement after NB-UVB administered three times weekly combined with 0.05% betamethasone valerate once daily, with response after 30 sessions. This article aimed to report a case of PL-like MF initially treated with topical corticosteroids without adequate response, followed by NB-UVB phototherapy to achieve more optimal clinical improvement. Assessment was conducted using the number of skin lesions and the Dermatology Life Quality Index (DLQI) as clinical indicators to describe the main problem and the objective of this case report.

CASE

A 28-year-old woman presented to the Dermatology and Venereology Outpatient Clinic of Dr. Sardjito General Hospital, Yogyakarta, Indonesia, with complaints of erythematous papules and patches on the abdomen, back, arms, and legs. Two years before her visit, she first noticed papules and erythematous patches on the abdomen, accompanied by pruritus that worsened with sweating, without pain or fever. The lesions gradually increased in number, involving the abdomen and spreading to the back, arms, and legs. She initially sought treatment from a general practitioner, was diagnosed with an allergic reaction, and received cetirizine and topical hydrocortisone; however, her complaints persisted.

One-year before presentation, the patient consumed herbal medicine four times a week for the pruritus. She reported temporary improvement of the erythematous patches, which recurred upon discontinuation of the herbal remedy. One month before presenting to Dr. Sardjito General Hospital, she consulted a dermatologist

and was diagnosed with atopic dermatitis and guttate psoriasis. Her complaints persisted, and then she was referred to a regional hospital with a diagnosis of pityriasis lichenoides chronica versus pityriasis rosea. One week before her current presentation, pruritus had subsided, but the papules and erythematous patches remained, prompting referral to Dr. Sardjito General Hospital. At the time of presentation, the patient still complained of papules and erythematous patches on the abdomen, arms, and legs.

Her past medical history was unremarkable for similar lesions, hypertension, diabetes mellitus, or malignancy, but she reported a history of allergic rhinitis and varicella. There was no family history of similar conditions. Previous treatments included methylprednisolone, desoximetasone ointment, acyclovir, and lansoprazole. The patient also reported a history of COVID-19 and influenza vaccinations before the appearance of the erythematous patches. The patient's general condition was good with normal vital signs result. No lymphadenopathy was observed. Dermatovenereological examination revealed multiple papules, macules, erythematous patches, and plaques of varying sizes and irregular shapes, accompanied by scaling, located on the trunk, upper, and lower extremities. Diascopy yielded negative results (FIGURE 1). The differential diagnoses included pityriasis lichenoides chronica, pityriasis lichenoides et varioliformis acuta, guttate psoriasis, and mycosis fungoides. A skin biopsy was subsequently performed.

Histopathological examination revealed the epidermis with lamellar orthokeratosis, parakeratosis, focal hypogranulosis, moderate spongiosis, irregular acanthosis, apoptotic keratinocytes, basal cell vacuolization, exocytosis of lymphocytes and neutrophils. The dermal papillae appeared edematous with erythrocyte extravasation, and a dense, diffuse inflammatory infiltrate consisted of lymphocytes, histiocytes, and neutrophils. In one high-power

field, infiltration of lymphoid cells into the epidermis was observed. Immunohistochemical examination showed CD3 staining in almost all lymphoid cell infiltrates, including those infiltrating the epidermis. In the foci with lymphoid infiltration into the epidermis, the CD4-to-CD8 ratio was higher (approximately 4:1), whereas in other areas the proportions of CD4 and CD8 were relatively balanced. CD30 staining was observed only in a few lymphoid cells (FIGURE 2). Laboratory examination was within normal ranges. Based on the clinical, laboratory, histopathological, and immunohistochemical examinations, the patient was diagnosed with pityriasis lichenoides-like mycosis fungoides.

The patient was treated with cetirizine 10 mg once daily, and a compounded topical preparation consisting of desoximetasone ointment and oleum cocos applied twice daily. After two months of treatment, the patient returned for follow-up, reporting persistent erythematous patches. Vital signs were within normal limits. Dermatovenereological examination revealed multiple erythematous papules, macules, patches, and plaques of varying sizes, irregular shapes, and multiple distributions on the trunk, upper, and lower extremities. As the lesions did not respond adequately to topical corticosteroid therapy, whole-body NB-UVB phototherapy was initiated with an initial dose of 500 mJ/cm² at a frequency of twice weekly. To date, the patient has undergone 37 sessions of NB-UVB phototherapy with a cumulative dose of 58,764 mJ/cm². The patient reported that most of the papules and erythematous patches had resolved following phototherapy. Dermatovenereological examination revealed multiple erythematous papules, macules, and patches, some with hyperpigmentation, of varying sizes and irregular shapes, showing approximately 87% improvement. The patient's DLQI score improved from 12 at baseline to 3 after 37 sessions of phototherapy. (FIGURE 3) (TABLE 1).

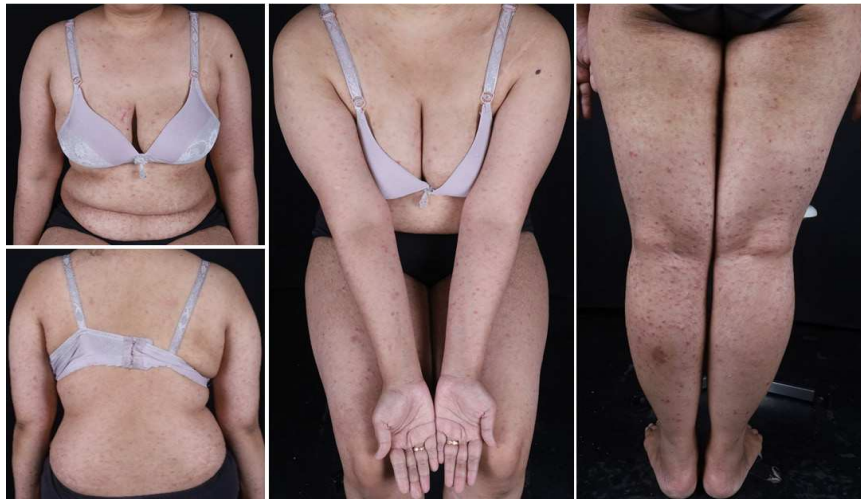

FIGURE 1. Clinical presentation of the patient at the first visit to the Dermatology and Venereology Outpatient Clinic, Dr. Sardjito General Hospital. Multiple erythematous papules, macules, patches, and plaques with scaling were observed on the trunk and extremities.

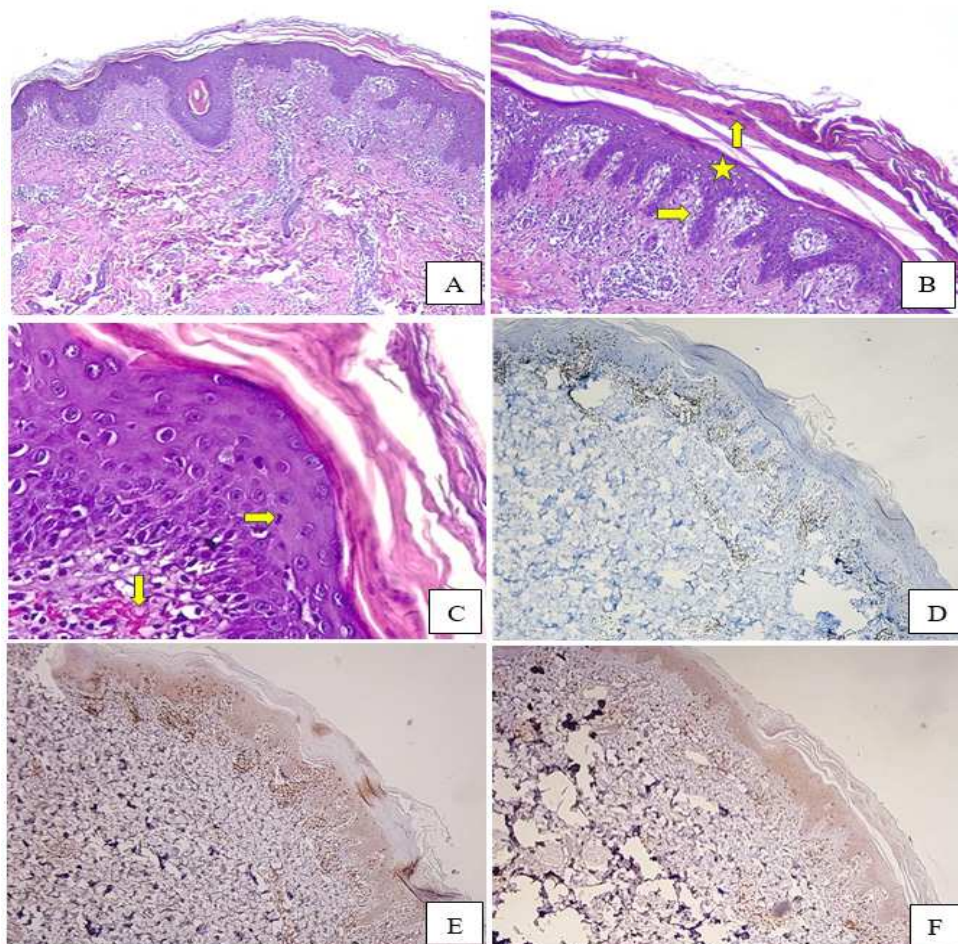


FIGURE 2. (A) Histopathological examination with hematoxylin and eosin (H&E) staining demonstrates an interface dermatitis pattern (H&E, 40x). (B) The epidermis shows parakeratosis (↑), spongiosis (*), and basal cell vacuolization (→) (H&E, 100x). (C) Lymphocytic exocytosis is observed in the epidermis (→), and erythrocyte extravasation is noted in the dermis (↓) (H&E, 400x). (D) CD3 immunohistochemical staining shows strong membranous positivity in nearly all infiltrating lymphoid cells. (E) CD4 immunohistochemical staining demonstrates strong membranous positivity in the majority of infiltrating lymphoid cells. (F) CD8 immunohistochemical staining also shows strong membranous positivity, with a CD4:CD8 ratio of approximately 4:1 among the infiltrating lymphoid cells.

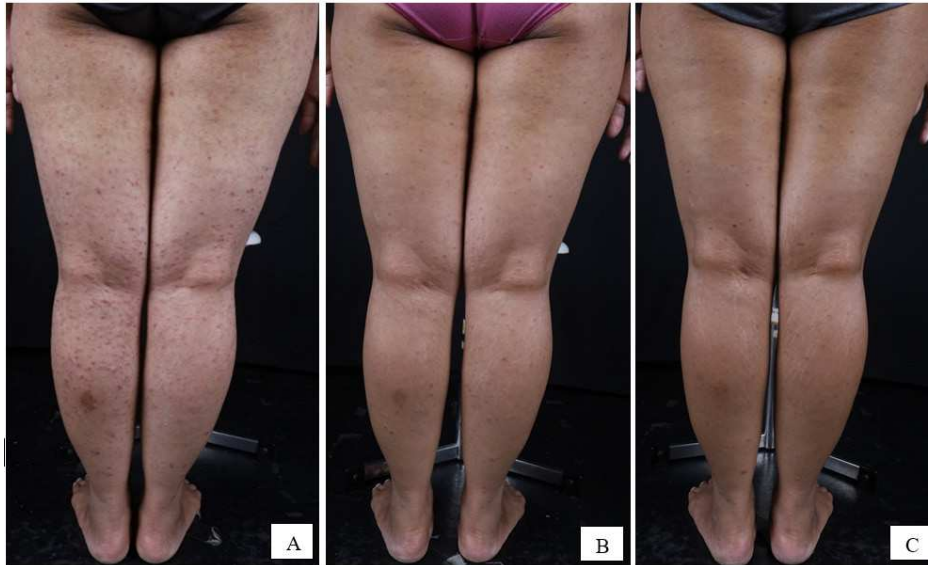

FIGURE 3. (A) Clinical presentation of the lower extremities before NB-UVB phototherapy, (B) after 18 sessions of NB-UVB phototherapy, and (C) after 37 sessions of NB-UVB phototherapy.

TABLE 1. Clinical response during NB-UVB phototherapy

Clinical Indicator	Baseline	After 18 sessions	After 37 sessions
Number of lesions (papule, patch and plaque erythema)	525	205 (61%)	69 (87%)
DLQI	12	9	3

NB-UVB: Narrow band- Ultraviolet B; DLQI: dermatology life quality index

DISCUSSION

Primary cutaneous lymphoma is an extranodal non-Hodgkin lymphoma characterized by clonal lymphocytic proliferation, with approximately 65% arising from T cells (cutaneous T-cell lymphoma, CTCL), 25% from B cells, and the remainder from natural killer cells.^{4,9} Mycosis fungoides is the most common CTCL variant, first described by Jean-Louis-Marc Alibert, with terminology referring to the mushroom-like appearance of advanced tumors. MF typically presents after the age of 50 and shows a male predominance.¹⁰ Clinically, MF is classified based on disease progression and prognosis into early stages (stages IA, IB, and IIA)

and advanced stages (stages IIB, III, and IV). Early-stage MF manifests as patches or thin plaques, often pruritic or asymptomatic, predominantly on sun-protected areas, and is frequently misdiagnosed as dermatitis or psoriasis. Despite its indolent onset, progression to tumor-stage disease or erythroderma may occur.^{1,10,11}

Several clinicopathologic variants of MF have been recognized, including PL-like MF, a rare subtype that clinically mimics pityriasis lichenoides while demonstrating histopathologic features consistent with MF, occasionally with overlapping characteristics. Lesions typically consist of multiple erythematous scaly papules and may result in widespread of hypopigmentation in

darker skin types, contributing to diagnostic delay and undertreatment.^{2,8} In the present case, the patient exhibited papules, macules, patches, and thin plaques distributed over the trunk and extremities, particularly in sun-protected areas, accompanied by pruritus without lymphadenopathy or visceral involvement. Histopathologic and immunohistochemical findings supported a diagnosis of PL-like MF, representing an early stage of MF. Given persistent lesions after two months of topical corticosteroid therapy, phototherapy was selected as the most appropriate treatment option.

Phototherapy is the standard treatment for early-stage MF that cannot be controlled with topical therapy. It generally yields a high rate of complete remission, although the duration of response varies. Phototherapy can be administered using narrowband ultraviolet B (NB-UVB), broadband ultraviolet B (BB-UVB), or psoralen plus ultraviolet A (PUVA) photochemotherapy, while more recently, modalities such as UVA1 and excimer laser have also been introduced.^{6,7} Ultraviolet B therapy is recommended for MF with patch or thin plaque lesions, whereas UVA is preferred for thicker plaque lesions.^{6,12}

Broadband UVB (290–320 nm) is now rarely used and has largely been replaced by narrowband UVB (311–312 nm) due to its superior efficacy and lower risk of erythema.⁶ Psoralen Ultraviolet-A (PUVA) is effective for thicker plaques or MF refractory to UVB because its longer wavelength allows deeper dermal penetration; however, psoralen administration (oral or topical) may cause nausea, headache, phototoxicity, and an increased cumulative risk of skin cancers, including melanoma. Ultraviolet-A1 (340–400 nm) penetrates more deeply into the dermis than UVB or conventional UVA and has demonstrated efficacy in advanced-stage MF with plaques, nodules, and erythroderma in

a case series of 13 patients, although its availability is limited and it carries a risk of photocarcinogenesis.^{6,7} The 308-nm excimer laser has also been shown to be safe and potentially effective for early-stage MF with localized lesions or in difficult-to-treat anatomical sites, though its role in MF management is not yet well established, and its availability remains limited.⁶

NB-UVB is considered safer and more practical than other treatment modalities. In this case, the patient presented with widespread erythematous papules, macules, patches, and plaques with overlying scale, involving the trunk and all four extremities. These lesions corresponded to early-stage MF with extensive skin involvement; therefore, whole-body NB-UVB with an initial dose of 500 mJ/cm² was chosen. The dosage of NB-UVB phototherapy was administered according to the protocol used at Dr. Sardjito Hospital, with a 10% increase in NB-UVB dose every three sessions. To date, several reports have demonstrated that NB-UVB phototherapy is effective for early-stage MF, including PL-like MF.¹ A review of patients with patch and plaque-stage MF treated with NB-UVB without systemic therapy showed a mean complete remission (CR) rate of 84% (ranging from 54% to 90%), with most patients receiving three sessions per week. NB-UVB therapy is more effective for patch-stage MF and in patients with lighter skin types (Fitzpatrick I–III).¹³

The exact mechanism of NB-UVB phototherapy in MF remains not fully understood, though it is thought to involve changes in cell cycle kinetics, alterations in cytokine expression, and immunomodulation. Several studies have reported that NB-UVB increases IL-2, IL-6, and TNF- α expression in human keratinocytes while reducing the allo-activating and antigen-presenting capacity of Langerhans cells. Furthermore, NB-UVB may suppress the neoplastic proliferation of clonal T cells

and function as an immunoregulatory agent. NB-UVB therapy may also directly induce apoptosis in atypical lymphocytes confined to the epidermis and papillary dermis.^{1,14} Side effects of NB-UVB include erythema, edema, blistering, pruritus, and herpes simplex reactivation, though these typically resolve within days. Despite concerns about photoaging and carcinogenic risk, no evidence has substantiated these risks. NB-UVB is also considered safer than PUVA.¹⁴

The therapeutic outcomes of NB-UVB in MF are categorized into complete, partial, and no response. A complete response corresponds to more than 95% clearance of lesions, a partial response to 50–95% clearance, and a no response to less than 50% clearance.¹⁴ In this case, the patient achieved 87% clinical improvement after 37 phototherapy sessions with a cumulative dose of 58,764 mJ/cm², corresponding to a partial response, without any acute adverse effects during therapy. This clinical improvement was accompanied by a marked improvement in quality of life, reflected by a reduction in the DLQI score from 12 at the baseline to 3 after 37 treatment sessions. Similar outcomes were observed in the study by Amin *et al.*,⁸ where a patient with PL-like MF managed with NB-UVB therapy thrice weekly, in combination with 0.05% betamethasone valerate cream applied once daily, achieved substantial improvement after completing 30 sessions of phototherapy. Furthermore, Park *et al.*,¹⁵ reported favorable therapeutic outcomes of NB-UVB in PL-like MF, with complete remission achieved in the majority of patients (73%), although a smaller proportion (17%) experienced recurrence following treatment.

CONCLUSION

Pityriasis lichenoides-like mycosis fungoides is a very rare variant of MF

characterized by cutaneous lesions resembling pityriasis lichenoides but demonstrating histopathological findings consistent with MF. In this case report, we describe a patient with PL-like MF who was treated with whole-body NB-UVB phototherapy and showed a favorable clinical response of 87% improvement after 37 sessions with a cumulative dose of 58,764 mJ/cm². Long-term follow-up is warranted to assess sustained clinical improvement and the potential for relapse.

ACKNOWLEDGMENT

The authors wish to thank the patient for their cooperation and consent to publish this case report. We also acknowledge the medical staff at Dr Sardjito General Hospital for their invaluable support in patient care and data collection.

REFERENCES

1. Jang MS, Kang DY, Park JB, Kim JH, Park KA, Rim H, *et al.* Pityriasis lichenoides-like mycosis fungoides: clinical and histologic features and response to phototherapy. *Ann Dermatol* 2016; 28(5):540-47. <https://doi.org/10.5021/ad.2016.28.5.540>
2. Hodak E, Laish IA. Variants of mycosis fungoides - UpToDate. UpToDate [Internet]. 2024 Apr 14. <https://www.uptodate.com/contents/variants-of-mycosis-fungoides/>
3. Larocca C, Kupper T. Mycosis fungoides and Sézary Syndrome. *Hematol Oncol Clin North Am* 2019; 33(1):103-20. <https://doi.org/10.1016/j.hoc.2018.09.001>
4. Vaidya T, Badri T. Mycosis fungoides. In: StatPearls [Internet]. Treasure Island (FL): StatPearls Publishing; 2024 [cited 2024 Oct 3]. <http://www.ncbi.nlm.nih.gov/books/NBK519572/> PubMed PMID: 30137856.

5. Stuver R, Geller S. Advances in the treatment of mycoses fungoides and Sézary syndrome: a narrative update in skin-directed therapies and immune-based treatments. *Front Immunol* 2023; 14:1284045. <https://doi.org/10.3389/fimmu.2023.1284045>
6. Lovgren ML, Scarisbrick JJ. Update on skin directed therapies in mycosis fungoides. *Chin Clin Oncol* 2019; 8(1):7. <https://doi.org/10.21037/cco.2018.11.03>
7. Kamijo H, Miyagaki T. mycosis fungoides and Sézary Syndrome: Updates and Review of Current Therapy. *Curr Treat Options Oncol* 2021; 22(2):10. <https://doi.org/10.1007/s11864-020-00809-w>
8. Mohd Amin SN, Muhamad R, Wan Abdullah WNH, Mohd Zulkifli M, Bakrin IH, Tangam T. A case report of pityriasis lichenoides-like mycosis fungoides in children: a challenging diagnosis. *Korean J Fam Med* 2021; 42(4):334-8. <https://doi.org/10.4082/kjfm.20.0036>
9. Sokołowska-Wojdyło M, Olek-Hrab K, Ruckemann-Dziurdzińska K. Primary cutaneous lymphomas: diagnosis and treatment. *Adv Dermatol Allergol* 2015; 32(5):368-83. <https://doi.org/10.5114/pdia.2015.54749>
10. Roy S, Ghosh K, Mandal PK, Das S. Mycosis fungoides: the great masquerader – a trilogy of case reports. *Asian Pac J Cancer Care* 2024; 9(1):157-60. <https://doi.org/10.31557/apjcc.2024.9.1.157-160>
11. Bagot M, Stadler R. Cutaneous Lymphoma. In: Fitzpatrick's Dermatology. 9th ed. Mc Graw Hill Education; 2019. p. 2074–107. (119).
12. Latzka J, Assaf C, Bagot M, Cozzio A, Dummer R, Guenova E, *et al.* EORTC consensus recommendations for the treatment of mycosis fungoides/ Sézary syndrome – Update 2023. *Eur J Cancer* 2023; 195:113343. <https://doi.org/10.1016/j.ejca.2023.113343>
13. Olsen EA, Hodak E, Anderson T, Carter JB, Henderson M, Cooper K, *et al.* Guidelines for phototherapy of mycosis fungoides and Sézary syndrome: A consensus statement of the United States Cutaneous Lymphoma Consortium. *J Am Acad Dermatol* 2016; 74(1):27-58. <https://doi.org/10.1016/j.jaad.2015.09.033>
14. Jang MS, Baek JW, Park JB, Kang DY, Kang JS, Suh KS, *et al.* Narrowband ultraviolet B phototherapy of early stage mycosis fungoides in Korean patients. *Ann Dermatol* 2011; 23(4):474-80. <https://doi.org/10.5021/ad.2011.23.4.474>
15. Park L, Green C, Giansiracusa DM, Hirt P, Ricotti C, Kerdel F. Pityriasis Lichenoides Like Mycosis Fungoides: A Case Report. *Cureus* 2023; 15(3):e36665. <https://doi.org/10.7759/cureus.36665>