

A Case Report on Cholestatic Jaundice Secondary to Adverse Effect of *Phaleria macrocarpa* (Mahkota Dewa)

Muhammad F. A. Rahim¹, Alvin O. Payus²

¹ Department of Internal Medicine, Universiti Kebangsaan Malaysia Medical Centre (UKMMC), Kuala Lumpur, Malaysia.

² Faculty of Medicine and Health Science, Universiti Malaysia Sabah (UMS), Kota Kinabalu, Sabah, Malaysia.

Corresponding Author:

Alvin Oliver Payus, MRCP, Faculty of Medicine and Health Science, Universiti Malaysia Sabah (UMS), Jalan UMS, 88400, Kota Kinabalu, Sabah, Malaysia. email: dralvinpayus@ums.edu.my.

ABSTRAK

Cedera hati kolestatik yang diinduksi obat dapat menimbulkan kesulitan diagnostik yang merupakan daftar panjang penyebab potensial berkaitan dengan ketidak-lengkapan resep atau obat yang dijual bebas, seperti obat herbal dan obat *Phaleria macrocarpa*, atau lebih dikenal sebagai 'Mahkota Dewa' oleh penduduk lokal di Asia Tenggara. Ekstrak tanaman obat ini telah semakin digunakan untuk pengobatan tradisional berbagai penyakit. Kami melaporkan kasus seorang pria muda yang tidak memiliki penyakit medis mengalami pola kerusakan hati kolestatik yang disebabkan oleh konsumsi kronis *Phaleria macrocarpa*. Tujuan dari laporan kasus ini adalah untuk membagikan efek samping yang tidak umum dari penggunaan produk tradisional ini, mungkin pernah dilaporkan sebagai efek yang tidak diketahui.

Keywords: drug induced cholestatic liver injury, kolestasis, *Phaleria macrocarpa*, Asia.

ABSTRACT

Drug induced cholestatic liver injury can posed a great diagnostic difficulty as a result of its long non-exhaustive list of potential offending causes which can be either prescribed or over-the-counter medications, such as medicinal herbs and remedies. *Phaleria macrocarpa*, or more commonly known as the 'God's crown' by the local people of South East Asia, is not listed as one of the causes. This medicinal plant extract has been increasingly used for traditional treatment for various ailments. Here, we report a case of a young man who has no known medical illness presented with cholestatic pattern of liver injury which caused by chronic ingestion of *Phaleria macrocarpa*. The objective of this case report is to share the uncommon side effect of taking this traditional product which may have been under-reported due to the unknown effect.

Keywords: drug induced cholestatic liver injury, cholestasis, *Phaleria macrocarpa*, Asia.

INTRODUCTION

'Mahkota Dewa' which literally translated as the 'God's Crown' is the other name for *Phaleria macrocarpa* in South East Asia. It has been increasingly used as a traditional medicinal product for various conditions for the past few years.¹ Most literatures available tried to explore

the potential benefit of the product,² but very few that study the adverse effect of taking it for long term. Here, we report a rather uncommon or may have been under-reported adverse effect of the *Phaleria macrocarpa* extract product which causes cholestatic jaundice. To the best of our knowledge, this is the first article that reported a

case of a cholestatic jaundice that occur as a side effect of taking *Phaleria macrocarpa*.

CASE ILLUSTRATION

A 35-year old man who works as a car mechanic and has no known medical illness was referred for further evaluation of progressively deepening jaundice and on and off body pruritus with corresponding abnormal liver enzymes over period of one month. He denied any fever, abdominal pain, vomiting nor altered bowel habit. He abhors alcohol consumption and does not smoke cigarette. He also was not taking any regular prescribed or over-the-counter medications. There was no significant history to suggest metabolic syndrome. On further questioning, the patient actually has been taking the extract of *Phaleria macrocarpa* over period of one year in the form of premixed coffee. He mentioned that the intention of this ingestion was merely for supplementary purpose as he was told that the product is liver protective. On examination, he has lean body built with the body mass index of 22, and appears overtly jaundice. Otherwise, he was not pale and there were no signs of acute liver failure nor any stigmata of chronic liver disease. His abdomen was soft and not tender, and there was no palpable mass nor organomegaly. Examination of the iris reveal no Kayser–Fleischer rings seen, and there was no cerebellar sign found as well. Initial blood investigations were taken at that time and shows his liver function was in cholestatic pattern with predominant conjugated hyperbilirubinemia (Table 1).

Table 1 showed hyperbilirubinemia with apparent cholestatic pattern of liver injury as evidence of raised alkaline phosphatase. Apart from a mildly raised total white count, all other parameters from full blood count and renal function are within normal ranges.

Aetiologic work-up for various infective causes of cholestasis like viral hepatitis, Cytomegalovirus, HIV and Epstein–Barr virus were negative. Autoimmune profiles were also screened and came back negative. Later he was subjected to ultrasound with doppler scan of the abdomen which show normal liver size and echogenicity and no biliary tree dilatation

Table 1. The initial blood investigation.

Blood parameters	Result	Normal Range
Haemoglobin	13.7 g/dL	12 – 18 g/dL
Platelet	375 x 10 ⁹ /L	150 – 400 x 10 ⁹ /L
White blood cell	12.9 x 10 ⁹ /L	4.0 – 11.0 x 10 ⁹ /L
Albumin	32 g/L	35 – 50 g/L
Alkaline Phosphatase	270 U/L	50 – 150 U/L
Alanine Transaminase	56 U/L	5 – 35 U/L
Total bilirubin	472 µmol/L	0 – 13 µmol/L
Creatinine	83 µmol/L	60 – 120 µmol/L
Sodium	135 mmol/L	135 – 150 mmol/L
Potassium	3.6 mmol/L	3.5 – 5.0 mmol/L
Urea	3.2 mmol/L	1.7 – 8.0 mmol/L

(Figure 1 and 2). He also did a complimentary endoscopic hepatobiliary ultrasound and a computed tomography imaging of the abdomen which revealed no radiological evidence of biliary obstruction and no corresponding biliary tree dilatation. The liver size and echogenicity were reported as normal. Subsequently, liver biopsy was done and revealed moderate intrahepatic cholestasis with mild hepatocellular injury. The perivenular and centrilobular region exhibit cholestasis with bile plugs in dilated canaliculi, bile in hepatocytes and Kupffer cells. There was occasional steatosis but the absence of hepatocyte ballooning and Mallory–Denk bodies make fatty liver infiltrates less likely. There was no active cirrhosis, no lymphoplasmacytic portal inflammation or no interface hepatitis which is classical of autoimmune hepatitis. All in all, liver biopsy has concluded that intrahepatic cholestasis was suggesting of outflow obstruction, making drug induced liver injury a top diagnostic priority (Figure 3 and 4). As the patient was not taking any regular medications both prescribed and over-the-counter, it was concluded that the cholestatic jaundice was induced by *Phaleria macrocarpa* extract in premixed coffee. He was managed conservatively with regular oral ursodeoxycholic acid 250 mg three times daily and also oral chlorphenamine 4mg as needed for the pruritus. He was discharged well and was follow up in the clinic for regular liver function monitoring, which has been normalized after withdrawal from taking the plant extract.

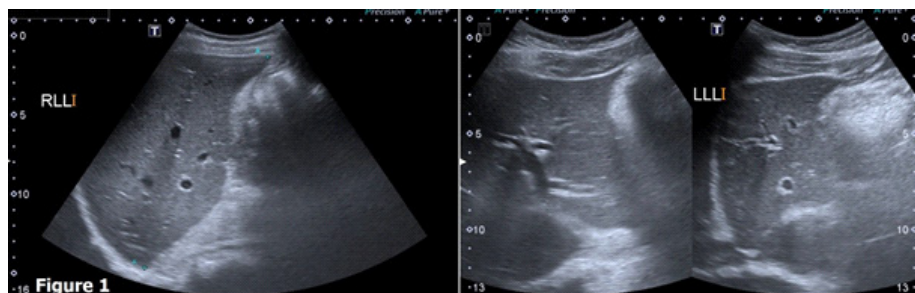


Figure 1. Ultrasound of the hepatobiliary system which shows no focal lesion, and normal liver size and echogenicity in both right and left lobe.

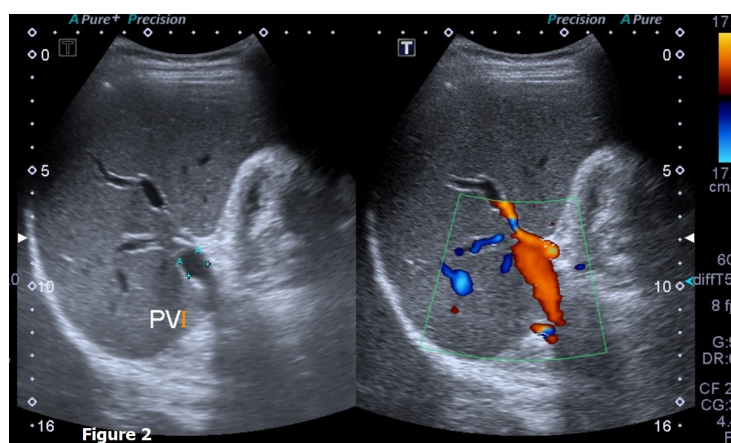


Figure 2. Colour Doppler ultrasound of the portal system which shows patent portal vein with normal Doppler flow.

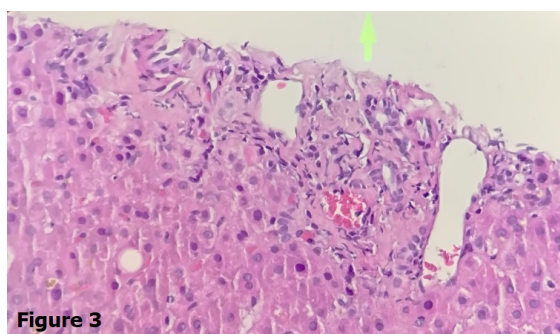


Figure 3. This photomicrograph shows mild inflammation of the portal tracts without evidence of bile duct injury or proliferation and no interface hepatitis.

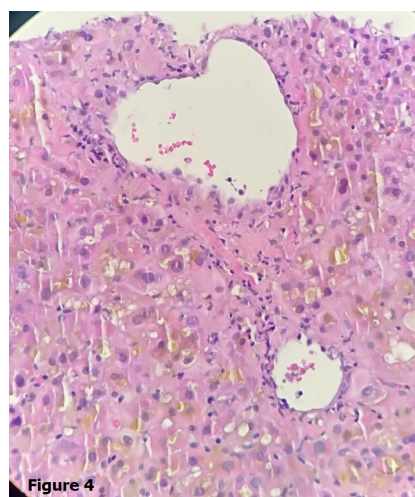


Figure 4. Image showing evident perivenular marked cholestasis, with bile plugs within dilated canaliculi.

DISCUSSION

Phaleria macrocarpa or fondly known as ‘Mahkota Dewa’ in the South East Asia region which literally translated as the God’s crown, is ubiquitous in the region especially in Malaysia and Indonesia. It is a complete tree which encompasses stem, leaves, flowers and the distinctive fiery red fruit, and can grow as high as 18 meters in height.¹ In the recent years, this

plant has become an emerging popular medicinal plant among Malaysian and Indonesian. It is believed that the plant has medicinal properties to treat various ailments such as cancer, impotency, hemorrhoids, diabetes mellitus, just to name a few. Faried et al. said that natural antioxidant

gallic acid extracted from *Phaleria macrocarpa* is believed to be a potential anticancer compound without denying the fact that in depth in vivo studies are needed to support.² On top of that, there are several other literatures have described the extract as being able to lower post-prandial hyperglycemia in animal model.^{3,4} The plant was also said to have a hepatoprotective effect⁵ and was proven in a study on a rat model by Sundari et al.⁶ On the contrary, there is very limited literature that evaluate the nature of the possible adverse effect of the plant extract. One study reported that the extract is believed to cause oral ulcers.⁷ Here, we report a case of a cholestatic jaundice that was induced by taking *Phaleria macrocarpa* extracts in a premixed coffee and has resolved spontaneously upon withdrawal from the supplement. As there is no single test that can directly pinpoint a diagnosis of drug induced liver injury currently, drug history plays a pivotal role in identifying the cause. This is done by simply enquiring the use of both prescribed and over-the counter medications which include vitamin and medicinal plant for remedies and herbal supplements.⁸ In this case report, our patient who was physically fit young man with no known medical illness has only positive history of taking *Phaleria macrocarpa* extract contained premixed coffee. However, a thorough work-up was done in order to rule out other more common causes of cholestatic jaundice, especially other possible drug that may have induced the liver injury, before the conclusion of *Phaleria macrocarpa* as the cause was made.

CONCLUSION

This case report served to share an uncommon case of cholestatic jaundice secondary to *Phaleria macrocarpa*, which may have been under-reported. As the product has been increasingly used in this part of the world, more studies are warranted in order to evaluate the hazardous effect of this plant extracts. However, the authors would like to emphasize systematic and step-wise evaluation should always be undertaken to rule out other more common causes of jaundice and liver injury.

ACKNOWLEDGMENTS

The authors would like to thank the patient for giving his consent and cooperation in relation to the writing of this case report. The author would also like to thank the Director General of Ministry of Health of Malaysia for his permission to publish this article.

CONFLICT OF INTEREST

There are no conflict of interest and financial support for this article.

REFERENCES

1. Altaf R, Asmawi MZ, Dewa A, Sadikun A, Umar MI. Phytochemistry and medicinal properties of *Phaleria macrocarpa* (Scheff.) Boerl. extracts. *Pharmaco Rev.* 2013;7(13):73.
2. Faried A, Kurnia D, Faried LS, Usman N, Miyazaki T, Kato H, Kuwano H. Anticancer effects of gallic acid isolated from Indonesian herbal medicine, *Phaleria macrocarpa* (Scheff.) Boerl, on human cancer cell lines. *Int J Oncol.* 2007;30(3):605-13.
3. Sugiawati S, Kardono L, Bintang M. a-Glucosidase inhibitory activity and hypoglycemic effect of *Phaleria macrocarpa* fruit pericarp extracts by oral administration to rats. *J Appl Sci.* 2006;6:2312-6.
4. Triastuti A, Park HJ, Choi JW. *Phaleria macrocarpa* suppress nephropathy by increasing renal antioxidant enzyme activity in alloxan-induced diabetic rats. *Natural Prod Sci.* 2009;15(3):167-72.
5. Zhang YB, Xu XJ, Liu HM. Chemical constituents from *Mahkota dewa*. *J Asian Natural Prod Res.* 2006;8(1-2):119-23.
6. Sundari N, Soetikno V, Louisa M, Wardhani BW, Tjandrawinata RR. Protective effect of *Phaleria macrocarpa* water extract (Proliverenol) against carbon tetrachloride-induced liver fibrosis in rats: Role of TNF- α and TGF- β 1. *J Toxicol.* 2018;2018.
7. Yosie A, Effendy MA, Sifzizul TM, Habsah M. Antibacterial, radical-scavenging activities and cytotoxicity properties of *Phaleria macrocarpa* (scheff.) Boerl. Leaves in hepg2 cell lines. *Int J Phar Sci Res.* 2011;2(7):1693.
8. Sundaram V, Björnsson ES. Drug-induced cholestasis. *Hepatol Comm.* 2017;1(8):726-35.