



Indonesian Dental Association

Journal of Indonesian Dental Association

<http://jurnal.pdgi.or.id/index.php/jida>  
ISSN: 2621-6183 (Print); ISSN: 2621-6175 (Online)



Literature Review

# Space Regainers in Pediatric Dentistry: A Literature Review

Aina Desmarani<sup>1§</sup>, Rosada Sintya Dwi<sup>2</sup>, Ulfa Yasmin<sup>2</sup>

<sup>1</sup>Undergraduate Dentistry Student, Faculty of Medicine, Sriwijaya University, South Sumatera, Indonesia

<sup>2</sup>Department of Pediatric Dentistry, Faculty of Medicine, Sriwijaya University, South Sumatera, Indonesia

## KEYWORDS

Early loss, Fixed space  
regainers, Primary teeth,  
Removable space regainers,  
Space analysis

## ABSTRACT

**Introduction:** Early loss of primary teeth can cause various problems, especially the loss of space required for permanent teeth eruption that leads to potential malocclusion. Space regainers are appliances that used to regain the space lost in some cases. There are different designs of space regainers, depending on the patient's cases. **Objective:** this article aims to overview fixed and removable appliances, and to better understanding the advantages and disadvantages, as well as the recent advances of space regainers. **Summary:** Space regainers are used in such condition which aims to move teeth that are drifted due to early loss of primary teeth. Fixed and removable space regainers have its own designs and advantages suitable for certain cases. Fixed appliances are favorable in the cases where there is more than 3 mm space lost or bodily movement of tooth is needed. If the space lost is due to mesial tipping and less than 3 mm, removable appliances are used. In the maxilla, removable appliances are frequently used than in the mandible because of its retentive property. Recall period is necessary to check for the appliances and whether the succedaneous teeth erupts into the position.

<sup>§</sup> Corresponding Author  
E-mail address: ainadesma@gmail.com (Aina Desmarani)

DOI: 10.32793/jida.v7i2.1274

**Copyright:** ©2024 Desmarani A, Dwi RS, Yasmin U. This is an open access article distributed under the terms of the Creative Commons Attribution License, which permits unrestricted use, distribution, and reproduction in any medium provided the original author and sources are credited.

## INTRODUCTION

Primary teeth have an important role, especially in muscle and skeletal development, as well as in occlusion, mastication, phonation, and aesthetics. Maintaining the arch of primary teeth is important to obtain the arch required for the eruption of permanent teeth. Premature loss of primary teeth can be described as a condition where tooth loss occurs  $\pm 1$  year before normal exfoliation. This situation can result in loss of space in children with mixed dentition period, resulting in irregular growth of replacement teeth.<sup>1,2</sup>

Early loss of primary teeth has many etiologies, including extensive dental caries, dental trauma, extraction of neonatal tooth and premature root resorption. This condition can cause potential malocclusion, articulation difficulties, bad habits such as anterior or lateral tongue thrusting, disruption of the growth of replacement teeth, and reduce child's self-confidence. Dental treatments when early primary tooth loss occurs can be done with passive space maintainer, space regainer, or combination of both.<sup>1,3-4</sup>

Space maintainer is defined as a fixed or removable device used to maintain space after premature loss of primary teeth. It is important to preserve the space to avoid development of occlusal disharmonies. However, in cases where there is progressive space loss, regaining the space should be considered. A space regainer or active space maintainer is an appliance used to regain the space that lost due to tooth drifting into the space created by premature loss.<sup>5-6</sup>

This literature review article compiled information from several literatures to provide an overview of space analysis methods as well as types of space regainer frequently used in the pediatric dentistry that can be implemented in the patient's cases.

## SPACE GAINERS

### Space Regainers in Pediatric Dentistry

Space regainer is used if there is a space loss due to drifting of teeth toward the space caused by primary tooth loss. Space regainer aims to restore the loss of arch width and perimeter, as well as improve the eruption position of replacement teeth. The total of space that can be obtained is usually 2 mm per quadrant if bilateral, or 3 mm if unilateral. This appliance must be retained until the permanent teeth have completely erupted or the patient's orthodontic treatment plan has been created.<sup>2,6</sup>

Space regainer treatment are indicated in the following conditions: loss of the maxillary or mandibular second primary molar, early loss of one or more primary teeth, permanent first molar ectopic eruption, and loss of space in the arch after the permanent first molar drifting mesially. Space regainers are not indicated if the distance between the permanent teeth that will erupt is sufficient, there are no signs of narrowing of the space, and in cases

when installing a regainer will worsen existing malocclusions such as overbite, class I type III, and class III malocclusion.<sup>2,6-7</sup> Space regainers are classified into removable appliance and fixed appliance.

### Fixed Space Regainers

#### Gerber space regainers

This fixed space regainer can be fabricated in the patient's mouth directly or in the laboratory. An orthodontic band or stainless-steel crown is selected for the abutment tooth and a U assembly is either soldered or welded to the mesial aspect of the band. A U wire is fitted into the tube with coil spring if the appliance is used as a spring-loaded space regainer. Open coil spring is placed between the tube and tube stop, and occlusal rests are added to reduced cantilever effect. While the migrated molar is being pushed back, it is necessary to ensure the anchorage tooth can withstand the displacing force.<sup>4,6,8</sup>

#### Hotz lingual arch

This appliance is indicated in cases where the mandible first permanent molar has drifted mesially rather than premolar drifted distally, and there is sufficient space between first molar and developing second molar in dental radiograph. Lingual arch provides anchorage and a horizontal spur is soldered in contact of premolar or canine perpendicular to the arch wire. A U loop is incorporated in the lingual side and when it is activated once a month, it can aid in molar distalization (Fig. 1a).<sup>2,5</sup>

#### Open coil space regainers

It is also called as Herbst space regainer, and used when the first premolar has erupted into the oral cavity. It uses a molar band that is fitted to the permanent first molar with soldered molar tubes. Stainless-steel wire is selected and bent into a U shape with a reverse bend in the distal aspect of molar. The U shape is aimed toward the first premolar and placed below the convexity of distal first premolar. Spaced coil spring is compressed and band is cemented.<sup>2,5</sup> Pradeep et al. combined NiTi open coil spring for distalization of mandibular permanent first molar with lingual arch as the anchorage (Fig. 1b). It was used in a severe space loss case and the results are exemplary.<sup>9</sup>

#### Lingual arch cross bow

Chalakkal et al. developed this space regainer to distalize mandibular first premolar that erupted prior to the canine. It uses lingual arch as anchorage and the activation via coil spring (Fig. 1c).<sup>5</sup>

### Nickel Titanium (NiTi) wire bonded space regainer

This space regainer is a modified and simple appliance that can be made chairside in single visit. On the buccal side of permanent first molar and premolar, a composite dimple is bonded and a tunnel is made using an explorer into the mesial side of the dimple. NiTi wire 0.016" is bonded to the dimple of first premolar and the other end is put into the tunnel of first molar as an active loop (Fig. 1d). Due to its memory properties the NiTi loop will return to its original shape over time, simultaneously distalizing and uprighting the first molar.<sup>5</sup>

### Double banded space regainer

This space regainer is used in conventional space regaining cases. Molar tubes are welded buccally and palatally to the banded permanent first molar. The primary first molar is also banded and two wires are soldered buccally and palatally, then attached into the molar tubes (Fig. 2a). The activation is done via coil spring that incorporated into the wire between stop anterior and posterior.<sup>5</sup>

### Pendulum appliance

This appliance is used in unilateral asymmetry molar correction or in Class II case. To maximize the efficiency of distalization, this appliance can be used prior to the eruption of second permanent molar. It consists of Nance plate, two pairs of wire on premolar teeth for retention, and one pair of Titanium-Molibdenum alloy wires with coil spring in the molar lingual sheath (Fig. 2b).<sup>10</sup>

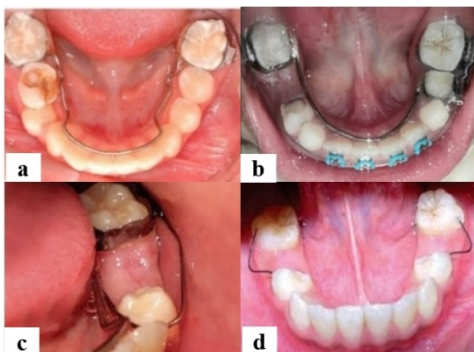

Figure 1. (a) Hotz lingual arch<sup>2</sup>; (b) Open coil with lingual arch<sup>9</sup>; (c) Lingual cross bow<sup>5</sup>; (d) NiTi wire bonded space regainer.<sup>5</sup>

### Distal jet

It is used for molar distalization in the maxillary arch that developed to overcome other appliance's disadvantages. This regainer uses bilateral tubes which are attached to an acrylic Nance button. Each tube is slid over a screw clamp and a coil spring. The wire extends in a bayonet bend from the acrylic into the lingual groove of

molar band (Fig. 2c). The activation is done once a month by sliding the clamp closer to the first permanent molar.<sup>11-12</sup>

### Lip bumper

It is a semi-fixed type of myofunctional appliance uses in the mandible for minimum molar distalization from early primary dentition. Orthodontic bands are fitted to mandibular permanent first molars. A U loop is placed in buccal vestibule either soldered to each molar band or in contact with the molar tube. The lip bumper is placed about 5-6 mm from the anterior teeth thus the pressure from lips function will be transferred to the molars as a distalizing force. Ben Mohimad et al. reported the use of lip bumper in a patient with slight Class III molar relationship which showed desirable results in 9 months (Fig.2d).<sup>10,13-14</sup>

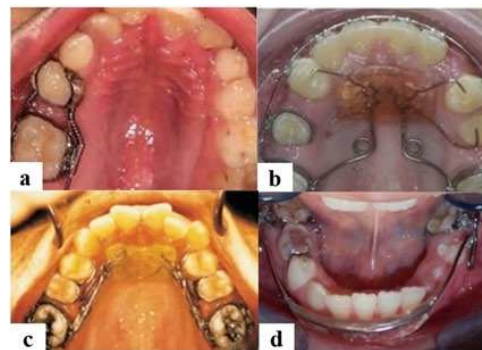


Figure 2. (a) Double banded space regainer<sup>5</sup>; (b) Pendulum appliance<sup>11</sup>; (c) Distal jet<sup>12</sup>; (d) Lip bumper.<sup>14</sup>

### Junaidi space regainer

This recent design in space regainer was developed by Junaidi using a molar band, an orthodontic archwire, and NiTi open coil spring. The wire was inserted into the tube of the molar band, and the open coil spring is placed around the wire before cementation. A ball-like piece of flowable composite is attached to the wire to prevent dislocation. This space regainer can be easily adjusted, with no additional soldering or intraoral impression, making this appliance is simpler in fabrication and can be reduced appointments time to single visit.<sup>15</sup>

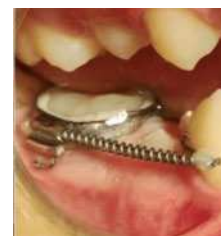

Figure 3. Junaidi space regainer<sup>15</sup>

## Removable Space Regainers

### Free end loop space regainer

It is a maxillary unilateral appliance that uses a labial arch wire for retention and stability, with a back-action loop and acrylic resin base (Fig. 4a). Activation of the free end of wire loop at specific intervals results in tooth movement. Checking and adjusting the regainer is done to preserve the light force on the molar tooth frequently. For the mandible, this appliance uses a shorter wire loop to minimize distortion when the patient inserts it.<sup>2,14</sup>

### Split saddle/split block space regainer

This space regainer consists of a buccolingually split acrylic block as the functional part. A buccal and lingual loop is constructed with wire and activated periodically to move the teeth (Fig. 4b).<sup>14</sup>

### Sling shot space regainer

This space regainer is constructed with elastic between buccal and lingual hooks, using transmitted force to distalize molar tooth (Fig. 4c). The placement of the elastic is done outside of the mouth and the patient can insert the appliance while adjusting the elastic into position.<sup>14</sup>

### Maxillary Cetlin plate

This space regainer is used in a case of one or two maxillary molars distalization. It consists of 0.022 × 0.028 wire covered with acrylic resin as an anterior screen and Adam's clasps on the first molars of primary teeth. A wire with helical loops is incorporated in the palate's acrylic and ended in the mesial aspect of permanent molars (Fig. 4d). Insertion of wire or elastic separator can be done if interproximal room is insufficient for the wire to be fitted.<sup>6</sup>

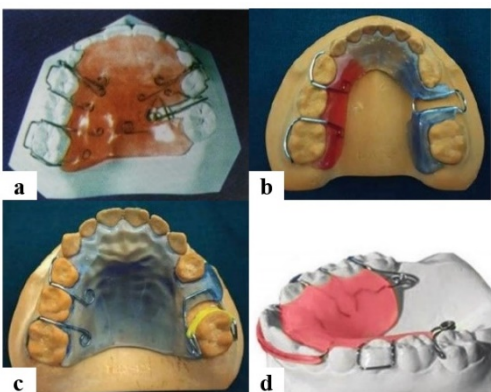


Figure 4. (a) Free end loop<sup>2</sup>; (b) Split saddle<sup>4</sup>; (c) Sling shot<sup>4</sup>; (d) Maxillary Cetlin plate.<sup>6</sup>

### Space regainer with jack screw/expansion screw

This space regainer incorporates an expansion screw between a split acrylic plate. Expansion screw is positioned in relation to the edentulous space perpendicular to the midline (Fig. 5a). It is activated by expanding the plates anteroposteriorly to gain transverse expansion of the arch.<sup>10,16</sup>

### Space regainer with finger/cantilever spring

It consists simple finger springs in acrylic removable appliance, and is retained using Adam's clasp (Fig. 5b). Activation of finger springs can result in molar

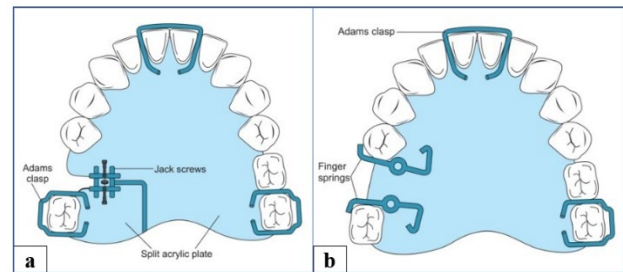


Figure 5. Space regainer with (a) Expansion screw; and (b) Finger springs.<sup>16</sup>

## Anterior Space Regainers

Anterior space regainers are designed for mesiodistal movement of migrated anterior teeth. Finger springs or split labial bows are indicated in these cases, and have to be anchored properly with suitable clasps. The loss of central incisor that leads to mesial migration of adjacent central incisor is regained with finger spring appliance to directing force distally (Fig. 6a). The migration of central incisor and inadequate space for lateral incisor that leads to crowding is regained with single split labial bow appliance (Fig. 6b). In the loss of two central incisors that leads to migration of lateral incisors, two split labial bows appliance is used to retract the lateral incisors for prothesis placement (Fig. 6c).<sup>8</sup>

In 1986, Bayardo developed a form of anterior space regainer that utilizes direct bond procedure. A labial tube is bonded to the enamel surface of central and lateral incisors adjacent to the edentulous space, resulting in space regaining.<sup>5</sup>

## DISCUSSION

There are many types of space regainers which are used for different cases. For mild to moderate (less than 3 mm) space loss due to mesial tipping, removable appliance is recommended.

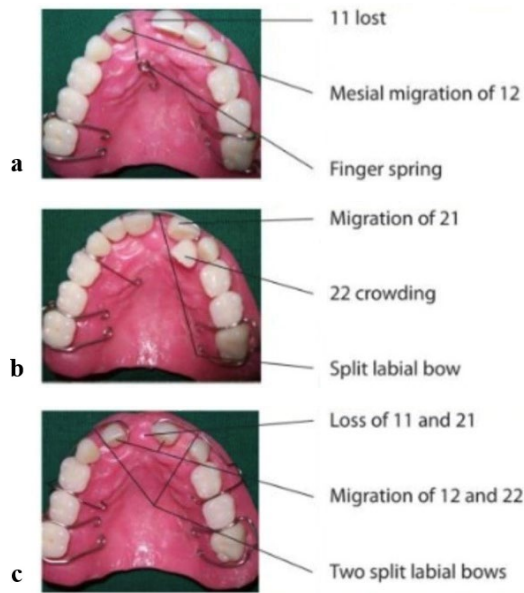


Figure 6. Anterior space regainer designs for (a) central incisor loss, (b) migration of central incisor, and (c) loss of central incisors.<sup>8</sup>

Removable appliances have satisfying results and better control over individual teeth in the maxilla compare to the mandible. Lower removable plates do not have palatal anchorage for support and are more fragile. The acrylic plates are usually small and has limited space for spring construction due to the gingival tissue's tenderness and lingual undercuts. In cases of moderate to severe space loss more than 3 mm or when bodily movement is required, fixed appliances are preferred. It allows better precision and control to the clinician and eliminates the need for patient compliance. Fixed appliances also have shorter average duration of treatment and costs can be minimize especially in single visit case. However, fixed appliances can result in mastication difficulty, whereas removable appliances affect speech and soft tissue irritation.<sup>3-4,9,17</sup>

American Academy of Pediatric Dentistry recommended several conventional space regainers, both

fixed and removable, that have been used generally with favorable results.<sup>18</sup> Most conventional space regainers have stages including taking patient's impression, fabrication, and insertion. Innovations continue to be carried out, so the time required for space regainer manufacturing can be shorten to single visit and chairside care. The use of NiTi-bonded and Junaidi space regainer designs allows for short working time and minimize children discomfort, especially in taking the intraoral impression. In addition, this modification does not require soldering, thus reducing the risk of breaking of soldered joints in the oral cavity.<sup>5,15</sup> The widespread use of computer-aided in oral care also increases the possibility of more sophisticated space management devices. Digital space management can make the treatment more comfortable and reduces anxiety in pediatric patients for intraoral impressions. Several studies have implemented the manufacture of digital space maintainers, but there has been no research for digital space regainers.<sup>19</sup> Thus, in-depth research of digital-aided devices is required in the future to understand the potential of this innovation.

## CONCLUSION

The loss of primary teeth can cause various dental problems, especially the loss of space required for the permanent teeth eruption leading to malocclusion. Space regainers are used in such condition which aims to move teeth that are drifted due to early loss of primary teeth. Fixed and removable space regainers have its own designs and advantages suitable for certain cases. Fixed appliances are favorable in the cases where there is more than 3 mm space lost or bodily movement of tooth is needed. If the space lost is due to mesial tipping and less than 3 mm, removable appliances are used. The modification of space regainers are developed to maximize the benefit and reduces the disadvantages. The use of digital-aided manufacture can also be considered in the future.

## REFERENCES

1. Nadelman P, Magno MB, Pithon MM, Castro ACR, Maia LC. Does the premature loss of primary anterior teeth cause morphological, functional and psychosocial consequences? *Braz Oral Res.* 2021;35:1-11. doi:10.1590/1807-3107bor-2021.vol35.0092
2. Muthu MS, Sivakumar N. *Pediatric Dentistry: Principles and Practice* 3rd ed. New Delhi: Elsevier, 2022; p. 627-37.
3. Enteghad S, Golfeshan F, Sardarian A, Navaei H. A comparison of lower dental arch changes using two types of space regainers: a removable appliance with a distalizing screw and a fixed double-banded appliance. *Int J Dent.* 2022;1-10. doi:10.1155/2022/4699516
4. Dean JA. *McDonald and Avery's Dentistry for the Child and Adolescent* 2nd South Asia ed. New Delhi: Elsevier, 2019; p. 278.
5. Marwah N. *Textbook of pediatric dentistry* 4th ed. New Delhi: Jaypee, 2019; p. 442-5.
6. Premkumar S. *Textbook of Orthodontics.* New Delhi: Elsevier, 2015; p. 43-5.
7. Rachmadani A, Jeffrey. Perawatan space regainer pada premature loss gigi molar sulung rahang atas dan bawah—Laporan kasus. *Oceana Biomed J.* 2020;3(2):21-37. doi:10.30649/obj.v3i2.56
8. Chockolingam PR. *Illustrated paediatric dentistry.* New Delhi: Wolters Kluwer, 2014; p. 459-61.
9. Pradeep S, Srinath SK, Krishnan H, Anu VF. Spring back the lost space: Fixed space regainer for e space loss—A case report. *RJDS.* 2023;15(2):124-7. doi:10.26463/rjds.15\_2\_2
10. Halim H. The application of pendulum as a space regainer in orthodontic treatment. *Open Dent J.* 2021;15:501-4. doi:10.2174/1874210602115010501.
11. Ali F, Soni S, Kaur R. Molar distalization: A review. *Int J Health Sci.* 2021;5(S2):6-22. doi:10.53730/ijhs.v5nS2.5325
12. Sharma S, Yadav V, Choudary N. Molar distalization—A review. *Heal Talk A J Clin Dent.* 2019;1-4. Available from: <https://oaji.net/articles/2020/1143-1583734894.pdf>.
13. Chandak P, Baliga S, Thosar N. Space regainer in pediatric dentistry. *Int Dent Med J Adv Res.* 2015;1:1-5. doi:10.15713/ins.idmjar.11
14. Ben Mohimd H, Benyahia H, Taleb B, Zaoui F. Management of space in the mixed dentition: The use of lip bumper. *Int J Pediatr Res.* 2016;3(6):440-5. doi:10.17511/ijpr.2016.i06.12
15. Dhahir MJ. Junaidi space regainer: A new two-in-one chairside appliance to simplify the space regaining procedure. *Cureus.* 2024;16(10):e72518. Doi:10.7759/cureus.72518
16. Rao JJ. *Quick review series for BDS 4th year* 2nd ed. New Delhi: Elsevier, 2017; p. 159-60.
17. Premkumar S. *Orthodontics: Prep Manual for Undergraduates* 3rd ed. New Delhi: Elsevier, 2016; p. 519-21.
18. American Academy of Pediatric Dentistry. Management of developing dentition and occlusion in pediatric dentistry. The reference manual of pediatric dentistry. Chicago, III.: American Academy of Pediatric Dentistry. 2024:475-93.
19. Nandini S, Senthil EAR, Bolla Deepthi, Pragadesh G, Lakhisa SKV, Priyadharshini S. Space maintainers in paediatric dentistry: Recent insights. *African J of Biol Sci.* 2024;6(6):8341-8. Doi:10.33472/AFJBS.6.6.2024.8341-8348.