



Pediatric Sciences Journal
Published by
Pediatrics Sciences Journal

Necrotizing enterocolitis, sepsis, and diarrhea due to cow's milk allergy in a full-term infant with Hypothyroidism: a case report



Runi Arumndari^{1*}, Asterisa Retno Putri¹, Claudia Natasha Liman¹,
Putu Siska Suryangingsih²

ABSTRACT

Introduction: Necrotizing enterocolitis (NEC) remains one of neonates' most common gastrointestinal diseases. NEC is allegedly to be a multifactorial disease. Some of the predisposing factors are cow's milk formula (CMF) feeding or not being breast-fed from birth, sepsis, and Hypothyroidism.

Case: An 8-day-old full-term baby girl was admitted with an initial diagnosis of sepsis and acute diarrhea due to cow's milk allergy. She had never been breast-fed from birth. She also had a fever, signs of mild-to-moderate dehydration, a C-Reactive Protein (CRP) level at 114, leukocyte 6.280/ul, platelet counts 477.000/ul, and fat on the stool test. She was given Cefotaxime, probiotics, zinc, and a hypoallergenic milk formula. Her condition worsened on the 4th day of hospitalization. She showed abdominal distention, bradypnea, and vomiting. She was then fasting, required a nasal cannula oxygen, and undergone several laboratory examinations showing leukocyte 4.980/ul, platelet count 54.300/ul, and a positive fecal occult blood test. An abdominal x-ray showed an increased bowel gas. She was then diagnosed with grade I NEC, and the antibiotic was changed to Meropenem, added with Metronidazole. She also undergone a thyroid hormone screening, had a TSH level of 6.36 and FT4 1.23, and thus was given Levothyroxine. Her condition improved gradually. After being given Meropenem for 7 days, she was discharged on the 12th day of hospitalization in good condition. Two days later, during the clinic's follow-up, she was in good health, and it was planned that she would do a follow-up examination for thyroid hormones a month later.

Conclusion: Cow's milk allergy can be severe enough to develop sepsis. Meanwhile, both are predisposing factors for NEC. Hypothyroidism can also be a predisposing factor by causing a decrease in intestinal motility, which plays a role in bacterial overgrowth. A study in animals showed that bacteria play an important role in the development of NEC because NEC will not occur in a germ-free environment but can only develop after exposure to microbes. Conservative treatment for NEC includes broad-spectrum antibiotics, bowel rest, and abdominal decompression.

Keywords: cow's milk allergy, Hypothyroidism, necrotizing enterocolitis, neonate, sepsis.

Cite This Article: Arumndari, R., Putri, A.R., Liman, C.N., Suryangingsih, P.S. 2023. Necrotizing enterocolitis, sepsis, and diarrhea due to cow's milk allergy in a full-term infant with Hypothyroidism: a case report. *Pediatrics Sciences Journal* 4(2): 50-53. DOI: 10.51559/pedscij.v4i2.58

¹General Practitioner, Wangaya Regional Public Hospital, Denpasar, Bali;

²Paediatrician, Wangaya Regional Public Hospital, Denpasar, Bali. Mailing address;

*Corresponding to:

Runi Arumndari;
General Practitioner, Wangaya Regional Public Hospital, Denpasar, Bali. Mailing address;
arumndariruni@gmail.com

Received: 2022-09-13

Accepted: 2023-11-10

Published: 2023-12-01

INTRODUCTION

Necrotizing enterocolitis (NEC), a condition in which intestinal tissue dies due to inflammation, is one of the most common gastrointestinal problems in the neonatal intensive care unit (NICU), with high morbidity and mortality rates.^{1,2} It is estimated that 1-3 out of 1000 babies born suffer from NEC, with mortality rates varying between 15% and 30%.³ Newly recovered infants from NEC have an almost 25% chance of developing microcephaly and serious neurodevelopmental delay.²

The pathophysiology of NEC is still not fully understood. The cause is thought to be multifactorial, with factors occurring

both antenatally and postnatally. Antenatal factors may include infection and using antibiotics and/or steroids during pregnancy.^{1,4} Postnatal factors may include immune system dysregulation, rapid introduction and progression of enteral feeding, formula feeding and/or not being breastfed from birth and sepsis.^{1,4,5} Hypothyroidism may also predispose to NEC by causing a decrease in intestinal motility, which then plays a role in the overgrowth of gut bacteria.⁶

The diagnosis and staging of NEC are based on Bell's criteria modified by Kleigman *et al.*, which divides NEC into 5 grades based on clinical, gastrointestinal, and radiologic findings.^{1,4} However,

the clinical symptoms of NEC can be nonspecific, making the diagnosis of NEC challenging. On the other hand, the mortality and morbidity of NEC are high and immediate treatment is required. In this case report, the authors present a case of NEC in a full-term infant with risk factors of cow's milk allergy, sepsis, and Hypothyroidism at Wangaya Regional Public Hospital, Denpasar.

CASE DESCRIPTION

An 8-day-old baby girl came to the emergency room of Wangaya Regional Public Hospital with complaints of liquid stools since 1 day before admission. The

liquid stool was said to be approximately 11 times within 24 hours, initially greenish in color, then yellow in color, and only a little pulp, mucus, and blood were absent. Complaints were accompanied by fever, but the temperature was not measured. There was no cough or cold. The urine color was dark yellow. Previously, 3 days before admission, she had been vomiting. She drank 50-60cc of CMF every 3 hours. She had never been breastfed since birth because her mother was on epilepsy medication with Phenobarbital. Her mother had a history of epilepsy since 4 years ago, and the treatment was declared complete after 2 years. However, complaints re-appeared 6 months ago, and the medication was re-administered.

The patient was born by cesarean section at Ganesha Hospital to a gravida 5 and para 2 mother with gestational age 37 weeks 5 days and premature rupture of membranes. She was born vigorous, with a birth weight of 3250 grams, birth length of 50 cm, head circumference of 34 cm, and chest circumference of 34 cm. She had received Hepatitis B and Polio vaccine. She was discharged in good condition.

Examination at the emergency room of Wangaya Regional Public Hospital showed body weight of 3285 grams and body length of 50 cm. She had a fever with a temperature of 38.3°C, heart rate of 170 beats/min, respiratory rate of 44 times/min, and oxygen saturation of 98% without oxygen support. On physical examination, she looked lethargic, had sunken eyes, was icteric with Kramer 4, had cutis marmorata almost all over the body, and showed decreased skin turgor. A blood test showed leukocytes 6,280/ul, hemoglobin 13.8 g/dl, hematocrit 40.3%, platelet count 477,000/ul, IT ratio 0.06, and CRP 114. The complete stool test showed fat. The CMF was then replaced with a hypoallergenic formula and was given through a nasogastric tube (NGT) 30cc per 3 hours. She was then given intravenous fluids with 10% Dextrose 12 drops/min, equivalent to 87 cc/kg/day. She was also given Cefotaxime 150 mg every 12 hours intravenously (equivalent to 45 mg/kg/day), Paracetamol drop 0.4 ml every 4 hours orally, Zinc syrup 1x10 mg, and Probiotic drop 1x2 drops. She was then admitted to the perinatology room

with an initial diagnosis of acute diarrhea with mild to moderate dehydration and sepsis due to cow's milk allergy.

In the first 3 days of treatment, the patient still had liquid stool for 3 times a day, and her body temperature was still fluctuating with the highest temperature of 38.5°C. Her condition worsened on the 4th day of treatment. She had vomiting with a yellowish color of approximately 10cc. She immediately fasted for a while, but the next day, she experienced another yellowish vomiting 3 times a day. There was a yellowish NGT residual for approximately 30cc. She also had an abdomen distention, bradypnea, and oxygen desaturation to 87%, followed by a minimal chest retraction. She was then given a nasal cannula of oxygen 0.5 liters/min, a change in the antibiotic regimen to Meropenem 130 mg every 12 hours intravenously added by Metronidazole 50 mg every 12 hours intravenously. She underwent a blood culture test, fecal occult blood test (FOBT), and a complete blood test, showing leukocytes 4,980/ul,

hemoglobin 13.5 g/dl, hematocrit 44.1%, platelet count 54,300/ul, positive FOBT, and no growth of specific pathogenic bacteria in the blood culture results. She was also examined for a plain abdominal radiograph showing increased intestinal gas. Thus, she was then diagnosed with grade I NEC.

In addition to NEC, the patient also underwent a thyroid hormones screening and was found to have subclinical Hypothyroidism with TSHs 6.36 and FT4 1.23. There was no facial dysmorphic, macroglossia, hypotonia, or hyperbilirubinemia. The patient was then given Levothyroxine 30 mcg daily (equivalent to 30 mcg/kg/day).

During the hospitalization, she also had a hyponatremia with an initial sodium level of 119 mmol/L. She was given rapid sodium correction with 3% NaCl for 8cc in 2 hours and continued with 3% NaCl 35cc for the remaining 22 hours. A repeat electrolyte examination was performed 24 hours after sodium correction with the results of sodium 126 mmol/L, potassium

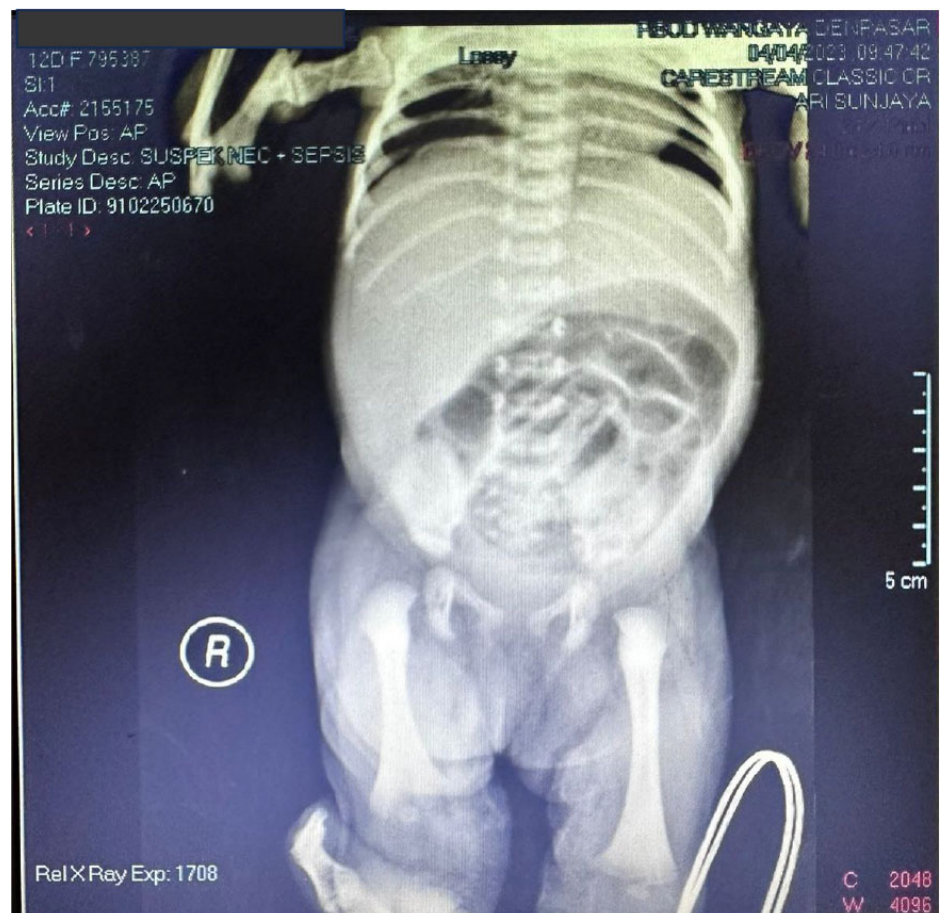


Figure 1. Plain abdominal radiograph on the 5th day of hospitalization.

Table 1. Staging system of NEC with Bell's criteria modified by Kliegman *et al.*¹

Stage	I	Ila	Ilb	IIla	IIlb
Systemic signs	Temperature instability, apnea, bradycardia	Similar to the stage I	Mild acidosis, thrombocytopenia	Respiratory and metabolic acidosis, mechanical ventilation, hypotension, DIC, oliguria	Further deterioration, shock
Intestinal signs	Increased gastric residuals, mild abdominal distention, occult blood in stool	Marked abdominal distention with or without tenderness, absent bowel sounds, grossly bloody stools	Abdominal wall edema and tenderness with or without palpable mass	Worsening wall edema with erythema and induration	Evidence of perforation
Radiographic signs	Normal or mild ileus	Ileus, dilated bowel loops, focal pneumatosis	Extensive pneumatosis with or without portal venous gas	Prominent ascites, fixed bowel loop	Pneumoperitoneum

5.4 mmol/L, and chloride 94 mmol/L. Thus, the 5% Dextrose maintenance fluid was replaced with a commercial isotonic crystalloid fluid containing 50 mEq/L sodium, 20 mEq/L potassium, and 50 mEq/L chloride.

On the 4th day of hospitalization, when the deterioration occurred, an electrolyte examination was repeated and showed hyperkalemia with potassium 6.8 mmol/L, sodium 115 mmol/L, and chloride 83 mmol/L. She was given salbutamol inhalation to reduce her potassium level. Her electrolyte balance was achieved on the 8th day of hospitalization with sodium 137 mmol/L, potassium 3.7 mmol/L, and chloride 104 mmol/L.

The patient gradually showed an improvement. She was able to breathe room air on the 6th day of hospitalization. She was active and crying vigorously on the 7th day of hospitalization. Cutis marmorata was no longer visible. Feces consistency was back to normal on the 8th hospitalization day. She was able to drink orally, starting from 2cc every 2 hours, after the NGT appeared clear and being fasted for 2 days or precisely on the 8th day of hospitalization. Her feeding tolerance improved by days, and the NGT could be removed on the 10th hospitalization day. After administration of Meropenem for 7 days, she underwent a repeated complete blood test and CRP on the 11th day of hospitalization, with the results of leukocytes 8,550/ul, hemoglobin 10 g/dl, hematocrit 28.7%, platelets 177,000/ul, and CRP 98. On the 12th hospitalization day, the patient was discharged in good condition. Three days later, she had a

follow-up at the pediatric and endocrine clinic and was healthy. Levothyroxine was continued until the planned follow-up examination of thyroid hormones.

DISCUSSION

NEC, a condition in which there is an intestinal tissue death due to inflammatory processes, is still one of the most common gastrointestinal problems found in the NICU, with high morbidity and mortality rates. The pathophysiology of NEC is not fully understood. Still, it is suspected that there is immune system dysregulation, changes in intestinal motility, decreased enzyme function, changes in mucus production and composition, decreased innate defense mechanism, the introduction and rapid progress of enteral feeding along with intestinal hypoxia-ischemia-reperfusion, formula feeding, and impaired colonization of the normal gut of the neonate. These factors can trigger an inflammatory response, causing cytokine activation, decreased epidermal growth factor, increased platelet activation factor, and progressive mucosal damage due to free radical production, leading to NEC. In addition, sepsis is also a predisposing factor for NEC.^{1,4,5} An animal study showed that bacteria play an important role in NEC, as NEC will not occur in a germ-free environment but can only develop after exposure to microbes.¹

In this case, the patient first arrived at the emergency room complaining of liquid stools more than 3 times daily, fever, weakness, sunken eyes, decreased skin turgor, icteric appearance, and visible cutis marmorata throughout the body.

From the anamnesis, it was known that the patient was given CMF since birth because the patient's mother was on epilepsy medication. The initial laboratory examination showed leukopenia, increased CRP at 114, fat in the complete stool examination, and bilirubin results within normal limits. Based on the history, physical examination and laboratory findings, the patient was hospitalized with an initial diagnosis of sepsis and acute diarrhea with mild to moderate dehydration suspected to be due to cow's milk allergy. In this patient, cow's milk allergy was severe enough to trigger sepsis, which then became a predisposing factor for NEC.⁷

Clinical symptoms of NEC can be non-specific: abdominal distension and/or tenderness, bloody stools, lethargy, apnea, respiratory distress, or poor perfusion. Erythema of the abdominal wall is a strong predictor of the diagnosis of NEC but is only present in 10% of patients.¹ Symptoms of NEC can progress rapidly, often within hours, from nonspecific symptoms to abdominal discoloration, bowel perforation, and peritonitis, leading to systemic hypotension requiring intensive medical support, surgery, or both.² Laboratory examination may reveal leukocytosis or leukopenia (with left-shifted neutrophils), thrombocytopenia, metabolic acidosis, hypo- or hyperglycemia, and/or electrolyte imbalance. Non-specific radiographic examination may show bowel wall thickening, decreased intestinal gas, and dilated bowel loops.¹ Pathognomonic radiologic findings in NEC are pneumatosis intestinalis, portal

venous gas, or both.^{1,2} Pneumatosis intestinalis is usually found in the right lower quadrant.¹ Diagnosis and staging of NEC are established by Bell's criteria modified by Kleigman et al., which are divided into 5 grades based on clinical, gastrointestinal, and radiologic findings.^{1,4}

In this patient, in the first few days of treatment, she still had diarrhea, fever and even deterioration. She had greenish vomiting, abdominal distension, bradypnea, and oxygen desaturation to 87%, followed by minimal chest retraction. A repeated complete blood test showed leukopenia and thrombocytopenia. FOBT examination also showed a positive result. Based on the systemic and gastrointestinal signs, she underwent a plain abdominal radiograph showing increased intestinal gas. The clinical and radiological findings finally met Bell's criteria for diagnosing grade I NEC. During treatment, she also had electrolyte imbalance, which is also one of the laboratory findings in NEC. In addition, the patient was also screened for thyroid hormone with TSHs 6.36 and FT4 1.23. Thus, she was also diagnosed with subclinical Hypothyroidism and given Levothyroxine. The relationship between Hypothyroidism and NEC is not fully understood, but Hypothyroidism is thought to be a predisposing factor for NEC. In a study of hypothyroid animals, the electrical and mechanical activity of the gastrointestinal tract was found to be decreased. In humans, the frequency of basal electrical rhythms also decreased. In addition, Hypothyroidism has been shown to cause peripheral neuropathy of the gut. This can lead to decreased intestinal motility, ileus, abdominal distension, and impaired mesenteric blood flow. In the presence of feeding, such decreased gut motility can lead to intestinal bacterial overgrowth. This, as mentioned earlier, is one of the predisposing factors for NEC.^{1,6}

Management of NEC can be done conservatively or surgically. Conservative treatment may include abdominal decompression, bowel rest, intravenous antibiotics, and intravenous hyperalimentation.^{2,3} Antibiotics are given as broad-spectrum antibiotics because several studies have been unable to explain

the specific microbiota that causes or induces NEC. Administration of probiotics is also recommended, considering the dysbiosis of the gut microbiota in NEC.¹ There is not enough evidence regarding the recommended antibiotic regimen of choice, but the most commonly reported is intravenous administration of Ampicillin and Gentamicin combined with Metronidazole for 10-14 days.³ In addition to this combination, Amoxicillin/Clavulanic Acid and Amikacin are also commonly used as the first line. Antibiotic administration in suspected NEC cases is also recommended, with the combination of Amoxicillin and Meropenem or Meropenem and Vancomycin being the preferred choice. The common operative procedure is laparotomy.² In this case, she was already given a broad-spectrum antibiotic, Cefotaxime, since the 1st day of treatment, and probiotics were also given. After the patient's condition worsened and was diagnosed with grade I NEC, the antibiotic was replaced with a combination of Meropenem and Metronidazole. The patient's clinical condition slowly improved after administering the combination for 3 days, and the patient could be discharged after 7 days of administration. Two days later, the patient was shown to be in good health during clinic follow-up.

CONCLUSION

NEC is still one of the most common gastrointestinal problems in the NICU, with high morbidity and mortality rates. The course and pathophysiology of the disease are still not fully understood, and the cause is thought to be multifactorial. Diagnosis of NEC can be challenging as clinical symptoms can be non-specific. The combination of clinical symptoms, radiologic findings, and risk factor tracing are important in diagnosing and managing NEC.

DISCLOSURES

Funding

There is no third-party involvement in this case report, it is fully self-funded by the corresponding author.

Conflict of Interest

There is no conflict of interest.

Author Contribution

Runi Arumndari involved in conceiving, designing, literature searching, and data analysis. Asterisa Retno Putri and Claudia Natasha Liman involved in literature searching. Putu Siska Suryaningsih involved in supervising the manuscript. All authors prepare the manuscript and agree for this final version of manuscript to be submitted to this journal.

Consent for publication

Written informed consent was obtained from the patient's family to publish this case report.

REFERENCES

- Hj N, Tg de M, Me van de V, Mp van der S, Jb van G, Bw K, et al. Necrotizing enterocolitis: a clinical review on diagnostic biomarkers and the role of the intestinal microbiota. *Inflamm Bowel Dis*. 2015 Feb;21(2):436-44. doi: [10.1097/MIB.0000000000000184](https://doi.org/10.1097/MIB.0000000000000184).
- Neu J, Walker WA. Necrotizing Enterocolitis. *N Engl J Med*. 2011 Jan 20;364(3):255-64. DOI: [10.1056/NEJMra1005408](https://doi.org/10.1056/NEJMra1005408)
- Gill EM, Jung K, Qvist N, Ellebaek MB. Antibiotics in the medical and surgical treatment of necrotizing enterocolitis. A systematic review. *BMC Pediatr*. 2022 Jan 27;22(1):66. DOI: <https://doi.org/10.1186/s12887-022-03120-9>
- Rose AT, Patel RM. A critical analysis of risk factors for necrotizing enterocolitis. *Semin Fetal Neonatal Med*. 2018 Dec;23(6):374-9. DOI: <https://doi.org/10.1016%2Fj.siny.2018.07.005>
- Gordon PV, Swanson JR, Attridge JT, Clark R. Emerging trends in acquired neonatal intestinal disease: is it time to abandon Bell's criteria? *J Perinatol*. 2007 Nov;27(11):661-71. DOI: <https://doi.org/10.1038/sj.jp.7211782>
- Howarth C, Banerjee J, Eaton S and Aladangady N (2022) Biomarkers of gut injury in neonates – where are we in predicting necrotising enterocolitis?. *Front. Pediatr*. 10:1048322. doi: [10.3389/fped.2022.1048322](https://doi.org/10.3389/fped.2022.1048322)
- Al-Beltagi M, Saeed NK, Bediwy AS, Elbeltagi R. Cow's milk-induced gastrointestinal disorders: From infancy to adulthood. *World J Clin Pediatr*. 2022 Nov 9;11(6):437-54. DOI: <https://doi.org/10.5409/wjcp.v11.i6.437>



This work is licensed under a Creative Commons Attribution