

Adverse Event : Myocardial Injury after Non-Cardiac Surgery (MINS) Post Craniectomy in Critical Care**Doni Fajri, Novita Anggraeni, Nopian Hidayat, Pratama Ananda**

Department of Anesthesiology and Intensive Therapy Faculty of Medicine Riau University, Arifin Achmad Hospital, Riau

Received: February 25, 2025; Accepted: March 07, 2025; Publish: June 21, 2025

correspondence: fajridoni90@gmail.com

Abstract

Intracerebral hemorrhage (ICH) describes the non-traumatic parenchymal hemorrhage caused by the rupture of cerebral vessels, accounting for 20–30% of all strokes. ICH will cause compression on the surrounding brain tissues, eventually giving rise to increased intracranial pressure. Decompressive craniectomy (DC) effectively reduce intracranial pressure. Myocardial injury is defined as an elevation of cardiac troponin levels with or without associated ischemic symptoms. Case a male, 66 years old patient was admitted to the ICU after undergoing Emergency Craniectomy Hematoma Evacuation due to Spontaneous ICH. After 52 hours of treatment, the patient was found to have ventricular tachycardia (VT) on the monitor and restlessness. The patient was also found to have comorbid hypertension. On a 12-Lead ECG we found NSTEMI, and Troponin I level was measured at 453.0 ng/L (positive). This patient was treated with anticoagulants, antiplatelet and statin, with monitoring of the ECG daily. On The 6th day patient was moved to High Care Unit (HCU). Myocardial Injury after Noncardiac Surgery is defined by elevated postoperative cardiac troponin concentrations, with or without accompanying symptoms or signs. It typically occurs within 30 days after surgery. The management of MINS involves the use of anticoagulants and antiplatelet therapy. Anticoagulant therapy should be considered between benefit and risk of re-bleeding post operative. MINS is a rare condition but is associated with an increased risk of 30-day mortality. A multidisciplinary treatment approach and a coordinated team effort are essential for improving the outcomes of patients with this condition.

Keywords: Anticoagulant, craniectomy, ICH, MINS, morbidity-mortality

J. neuroanestesi Indones 2025;14(2): 86–91

Introduction

Myocardial Injury after Non-Cardiac Surgery (MINS) is a condition where heart muscle damage, typically due to ischemia, occurs after a non-cardiac surgical procedure. It is diagnosed by elevated cardiac troponin level, even without ischemic symptom, within 30 days after surgery. MINS associated with increased of mortality and other cardiovascular complication Intracerebral hemorrhage (ICH), also known as hemorrhagic stroke, refers to the non-traumatic parenchymal hemorrhage caused by the rupture

of cerebral vessels, accounting for 20–30% of all strokes. With an acute phase fatality rate of 25–50%, ICH is classified as a high-mortality condition. ICH is now the leading cause of death. It is frequently brought on by high blood pressure along with arteriosclerosis, microaneurysms, or microangiomas.^{1,2} ICH will be resulted in cerebral edema and compression of the surrounding brain tissues, which may ultimately raise intracranial pressure and perhaps induce a brain hernia. Rapid and efficient intracranial pressure reduction, decreased mortality, and improved functional result are all possible with decompressive craniectomy (DC).³ A rise in cardiac troponin levels, with or without accompanying ischemia

doi: <https://doi.org/10.24244/jni.v14i2.664>

ISSN (Print): 2088-9674 ISSN (Online): 2460-2302

This is an open access article under the CC-BY-NC-SA licensed: <https://creativecommons.org/licenses/by-nc-sa/4.0/>JNI is accredited as Sinta 2 Journal: <https://sinta.kemdikbud.go.id/journals/profile/796>

Doni Fajri, Novita Anggraeni, Nopian Hidayat, Pratama Ananda Copyright ©2025

How to cite: Fajri D, et al, "Adverse Event : Myocardial Injury After Non-Cardiac Surgery (Mins) Post Craniectomy In Critical Care".

symptoms, is referred to as myocardial injury.^{4,5} Following non-cardiac surgery, postoperative morbidity and death are increased by myocardial injury.⁵⁻⁸ Myocardial infarction continues to be the leading cause of cardiovascular morbidity and death. There are four possible mechanisms for myocardial injury: rupture of the coronary plaque, mismatch between the oxygen supply and demand in the heart, non-ischemic cardiac conditions like an atrial fibrillation episode, or non-cardiac causes like pulmonary embolism.^{6,9} The range of MINS incidence is 3.5% to 19.1%. In patients with MINS, 30-day death was independently predicted by age greater than 75 years, ST segment elevation or new left bundle branch block, or anterior ischemic ECG abnormalities.^{9,10} Women had a lower incidence of MINS than males did.¹¹

Case

History

A 66-year-old male patient came to emergency unit Arifin Achmad General Hospital, Riau with the main complaint loss of consciousness for three hours prior to admission, severe headache, nausea, and vomiting. The patient had been diagnosed with hypertension since 2018, and was currently taking amlodipine 10 mg, but did not take the medication on a regular schedule. The patient had a cough and fever for five days. There were no other comorbidities.

Physical Examination

The patient weighs 60 kg, height 163 cm, body mass index 22.58 kg/m². During the examination, we discovered that the patient GCS 12 (E3V4M5) pupillary isochore 3 mm/3mm, pupillary reflex +/+. On examination, the patient's respiration was within normal limits, with a respiratory frequency of 18 times per minute, vesicular breath sounds in both lung fields, rhonchi +/+, and wheezing absent, and peripheral oxygen saturation was 99% at NRM 8 LPM. Blood pressure was 165/89 mmHg with hypertension; pulse was 74-79 beats per minute; and heart sounds 1 and 2 were single, regular, with no murmurs or gallops. Urogenital examination was within normal limits, and examination of the extremities revealed that the capillary refill time was less than two seconds.

Supportive Examination

Preoperative laboratory findings included Hb 12.8 gr/dl, PT 14.4 second, INR 1.01 second, APTT 32.1 second, AST 25, and ALT 13. A pre-operative chest X-ray (Figure 1) revealed pneumonia. The

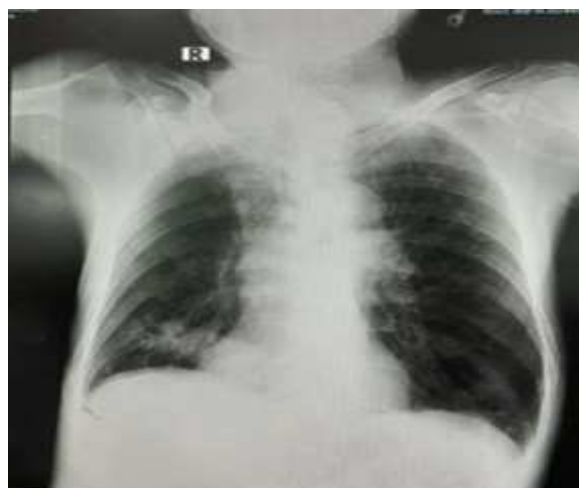

Figure 1. Chest X-Ray

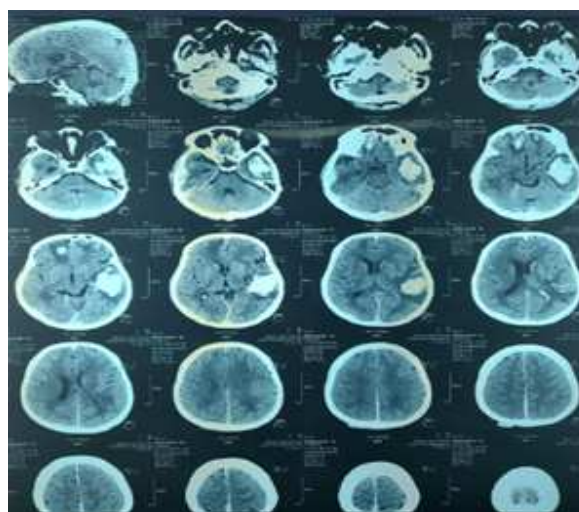


Figure 2. Brain CT Scan

brain CT scan (Figure 2) revealed an intracerebral hematoma. The patient was diagnosed with spontaneous ICH and pneumonia. This patient was scheduled for an Emergency Craniectomy Hematoma Evacuation.

Anesthesia Management

The patient was assigned to the American Society of Anesthesiologists (ASA) Class 3 and was diagnosed with spontaneous ICH and

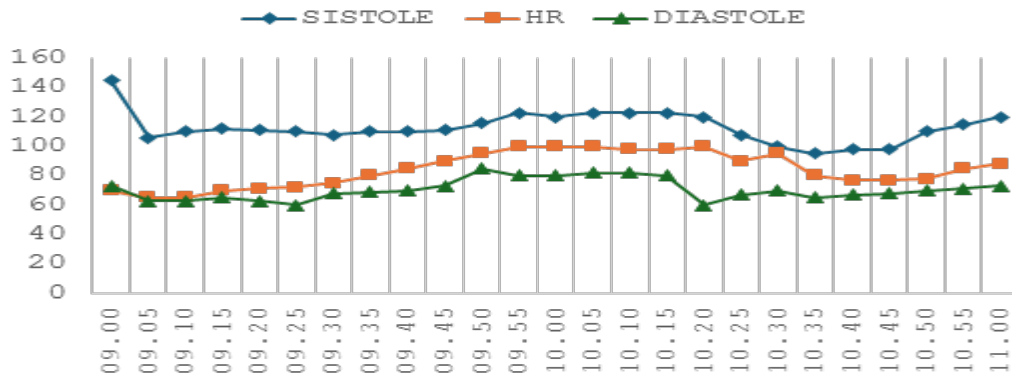


Figure 3. Intraoperative Hemodynamic Monitoring

pneumonia. General anesthesia and endotracheal intubation was planned. Before induction, the intravenous access was verified with a Central Venous Catheter (CVC) and standard monitoring. Preoxygenation lasted 5 minutes, after which 150 mcg of fentanyl was administered. Propofol, a sedative agent, was then titrated to a last dose of 150 mg. After that, 80 mg of lidocaine and 45 mg of rocuronium were administered, and ventilation was maintained for up to 3 minutes before intubation with an endotracheal tube (ETT) No.7.5. During intraoperative maintenance, propofol 50–100 mcg/kgbw/minute and fentanyl 50–100 mcg/hour were used to maintain an endtidal carbon dioxide (EtCO₂) level of 30–35 mmHg. The patient's condition remained stable, and no significant hemodynamic changes were observed intraoperatively (Figure 3). The patient's total anesthesia time was 120 minutes. The total blood loss was 200 mL, and 2000 mL of crystalloid fluid was administered. Throughout the surgery, the patient's condition remained stable, with a urine output of 2.8 ml/kg body weight per hour.

Postoperative Management

A physical examination showed GCS with sedation using propofol 25–50 mcg/kgBW/minute, analgetic with fentanyl 30 mcg/hour, paracetamol 1gr/6 hour, methylprednisolone 125 mg/12 hour, citicoline 100 mg/12 hour, mannitol 125 ml/6 hour, phenytoin 100 mg/8 hour and ceftriaxone 1 gr/ 12 hour. Blood gas analysis pH 7,37 pCO₂ 38 PO₂ 183 BE -2 HCO₃ 22,4 SaO₂ 99% and etCO₂ with 30–35 mmHg.

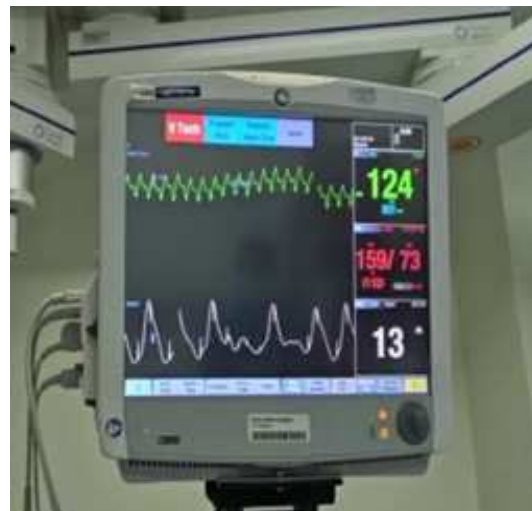

Figure 4. VT on Monitor

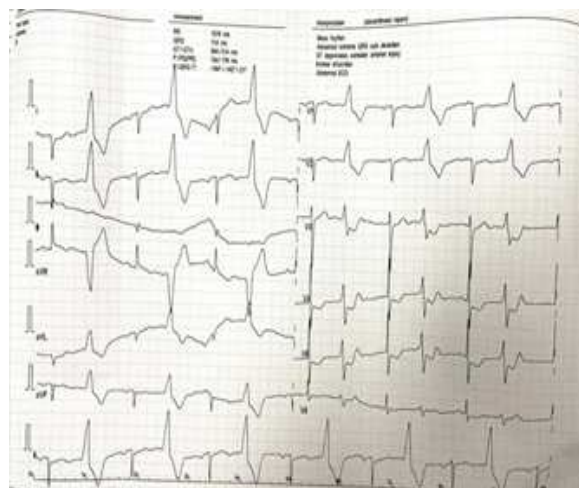


Figure 5. 12 lead ECG

The patient was given a ventilator with tidal volume 6 mL/kgbw, respiratory rate 14 times per minute, and PEEP 5, and gradual weaning

was performed. After 52 hours of treatment, the patient was found to have ventricular tachycardia (VT) (Figure 5) on the monitor and restlessness. We performed 12-lead ECG (Figure 6) and then the Troponin I level was measured at 453.0 ng/L (positive). The patient was treated with amiodarone 150 mg/ 10 minutes, anticoagulants such as heparin, antiplatelet such as aspirin, and a statin, with monitoring of the ECG and Activated Partial Thromboplastin Time (APTT) then all electrolytes imbalance should be corrected such are hypokalemia and hypomagnesemia. On the 4th day, there was an improvement in the ECG and patient was extubated. On the 6th day patient was moved to High Care Unit (HCU).

Discussion

An increase in cardiac troponin levels with or without associated ischemic symptoms, is referred to as Myocardial Injury.^{5,12-14} During the perioperative phase, ischemic symptoms are frequently concealed by sedatives or mistaken for surgical pain.¹⁵ MINS occurred 40% on the day of surgery, 40% on the first post-operative day, and 15% on the second day following surgery, according to the cohort study. However, since over 70% of patients with MINS do not exhibit any symptoms, the majority of these myocardial injuries would probably go unnoticed in the absence of troponin monitoring. Thus, patients who are at a certain level of risk may benefit from routine postoperative troponin measurement.⁵ Troponin should be checked during the perioperative phase, according to current recommendations. At first, the consensus among experts was that patients over 45 should be screened.⁵ The American College of Cardiology/American Heart Association and the European Society of Cardiology/Anesthesiology both recommended routine troponin screening for those with ischemic symptoms or who are at high risk of cardiovascular events. The most recent Canadian Cardiovascular Society guidelines strongly recommended that troponin levels be measured daily for two to three days after surgery in patients with a cardiovascular risk >5%, as the vast majority of clinically significant MINS would otherwise go undetected.^{5,9,14,16}

Troponin elevations following noncardiac surgery can be caused by a variety of factors. Increases in catecholamines, cortisol, and inflammatory cytokines can result from anesthesia and surgical trauma.¹² Myocardial injury can arise from an ischemic imbalance in the supply and demand of oxygen in the heart caused by perioperative hemodynamic fluctuations. In addition to increasing myocardial wall stress and oxygen requirements, tachycardia shortens the diastolic phase. Hypertensive episodes raise myocardial oxygen demand and left ventricular afterload. Elevated coronary artery shear stress can cause plaque disruption (erosion or rupture) and destabilize preexisting coronary atherosclerotic lesions.¹²

The initiation of early anticoagulant therapy on post craniectomy patient should be considered between benefit and risk of re-bleeding postoperative. Anticoagulant therapy between postoperative day (POD) 2 and 29 on the retrospective study of patients after craniotomy concluded that there was no increased incidence of ICH except warfarin. Heparin may be preferable in patients at high risk for postoperative ICH due to its short half-life and ease of reversal. Surveillance brain CT-Scan was performed one day after anticoagulant therapy or was repeated in response to new neurological symptoms.¹⁷

Conclusions

Adverse outcomes are associated with myocardial damage, which is indicated by increases in troponin levels during the perioperative phase of noncardiac surgery. Routine troponin monitoring may be beneficial in the first 48 hours after surgery, when MINS is most likely to occur, as most MINS patients do not exhibit ischemia symptoms. Although MINS is uncommon, it is linked to a higher risk of 30-mortality. Anticoagulant therapy should be considered between benefit and the risk on post craniectomy patient with MINS. To improve the outcomes for patients with this condition, a coordinated team effort and a multidisciplinary treatment approach are crucial.

References

- Ling M, Zhang Q, Zang L, Li X, Liu Q. Decompressive craniectomy can improve the recovery of neurological function, daily living ability and life quality of patients with intracerebral hemorrhage after surgery. *Am J Transl Res*. 2021;13(10):11364–1374.
- Ma Y, Zhang D, Lv Z, Cui Y, Fei Y, Chang T, et al. Optimal intervention time and risk of the activating blood and removing stasis method in acute cerebral hemorrhage patients: A randomized placebo-controlled trial. *Med (United States)*. 2021;100(2):E24214. Doi: 10.1097/MD.00000000000024214
- Beck J, Fung C, Strbian D, Bütikofer L, Z'Graggen WJ, Lang MF, et al. Decompressive craniectomy plus best medical treatment versus best medical treatment alone for spontaneous severe deep supratentorial intracerebral haemorrhage: a randomised controlled clinical trial. *Lancet*. 2024;403(10442):2395–404. Doi: 10.1016/S0140-6736(24)00702-5
- Youssef H, Mhaskar R, Thompson K, Codolosa JN. Treatment and mortality of myocardial injury after noncardiac surgery. *J Am Coll Cardiol [Internet]*. 2023;81(8):1320. Available from: [http://dx.doi.org/10.1016/S0735-1097\(23\)01764-3](http://dx.doi.org/10.1016/S0735-1097(23)01764-3)
- Park J, Lee JH. Myocardial injury in noncardiac surgery. *Korean J Anesthesiol*. 2022;75(1):4–11. Doi: 10.4097/kja.21372
- Álvarez-García J, Popova E, Vives-Borrás M, de Nadal M, Ordonez-Llanos J, Rivas-Lasarte M, et al. Myocardial injury after major non-cardiac surgery evaluated with advanced cardiac imaging: a pilot study. *BMC Cardiovasc Disord*. 2023;23(1):1–10. Doi: 10.1186/s12872-023-03065-6
- Hua A, Pattenden H, Leung M, Davies S, George DA, Raubenheimer H, et al. Early cardiology assessment and intervention reduces mortality following myocardial injury after non-cardiac surgery (MINS). *J Thorac Dis*. 2016;8(5):920–24. Doi: 10.21037/jtd.2016.03.55
- Park J, Kwon JH, Lee SH, Lee JH, Min JJ, Kim J, et al. Prognosis of myocardial injury after non-cardiac surgery in adults aged younger than 45 Years. *Circ J*. 2021;85(11):2081–088. Doi: 10.1253/circj.CJ-21-0106
- Gao L, Chen L, He J, Wang B, Liu C, Wang R, et al. Perioperative myocardial injury/infarction after non-cardiac surgery in elderly Patients. *Front Cardiovasc Med*. 2022;9:1–6. Doi: 10.3389/fcvm.2022.910879
- Gao L, Chen L, Wang B, He J, Liu C, Wang R, et al. Management of postoperative myocardial injury after non-cardiac surgery in patients aged ≥ 80 years: Our 10 years' experience. *Front Cardiovasc Med*. 2022;9. Doi: 10.3389/fcvm.2022.869243
- Kwon JH, Park J, Lee SH, Hyun CW, Kim J, Yang K, et al. Sex differences in myocardial injury after non-cardiac surgery and postoperative mortality. *Perioper Med [Internet]*. 2023;12(1):1–10. Available from: <https://doi.org/10.1186/s13741-023-00294-3>
- Ruetzler K, Smilowitz NR, Berger JS, Devereaux PJ, Maron BA, Newby LK, et al. Diagnosis and management of patients with myocardial injury after noncardiac surgery: A scientific statement from the American Heart Association. *Circulation*. 2021;144(19):E287–305. Doi: 10.1161/CIR.0000000000001024
- Devereaux PJ, Szczeklik W. Myocardial injury after non-cardiac surgery: Diagnosis and management. *Eur Heart J*. 2020;41(32):3083–091. Doi: 10.1093/eurheartj/ehz301
- Kashlan B, Kinno M, Syed M. Perioperative myocardial injury and infarction after noncardiac surgery: a review of pathophysiology, diagnosis, and management.

- Front Cardiovasc Med [Internet]. 2024;11:1–12. Available from: <https://doi.org/10.3389/fcvm.2024.1323425>
15. Rostagno C, Craighero A. Postoperative myocardial infarction after non-cardiac surgery: An update. *J Clin Med*. 2024;13(5). Doi: 10.3390/jcm13051473
 16. Ruetzler K, Khanna AK, Sessler DI. Myocardial injury after noncardiac surgery: Preoperative, intraoperative, and postoperative aspects, implications, and directions. *Anesth Analg*. 2020;131(1):173–86. Doi: 10.1213/ANE.0000000000004567
 17. Wilson JM, Shelvin KB, Lawhon SE, Crabill GA, Hayden EA, Velandar AJ. Safety and timing of early therapeutic anticoagulation therapy after craniotomy. *Surg Neurol Int*. 2024;15:31. Doi: 10.25259/SNI_887_2023.