



## ALL-EPIPHYSEAL ALL-INSIDE TECHNIQUE FOR ANTERIOR CRUCIATE LIGAMENT RECONSTRUCTION IN PREPUBESCENT PATIENT: A CASE REPORT

Imelda Lumban Gaol<sup>1</sup>, Kuku Dwiputra Hernugrahanto<sup>2</sup>, Jeffry Andrianus Muslim<sup>3</sup>, Dwikora Novembri Utomo<sup>4</sup>

<sup>1</sup>Fellow of Indonesia Hip and Knee Society, Orthopaedic Surgery Department, Dr. Soetomo General Hospital, Surabaya, Indonesia

<sup>2,3,4</sup>Consultant of Orthopaedic Surgery Department, Dr. Soetomo General Hospital, Surabaya, Indonesia

### ABSTRACT

Anterior cruciate ligament injuries are common seen in active and young patients. The ACL reconstruction technique in skeletally immature patients tries to minimize the growth disturbance. All physal sparing technique is technically demanding. In this paper, we described physal sparing technique of ACL reconstruction in skeletally immature patient. This is an all-epiphyseal all-inside ACL reconstruction with retrodrill of the femoral and the tibial sockets. Both sockets are within epiphysis. This technique used free loop system. This free loop system allows us to make a socket with length 15 mm, that is safe from the physis. This socket also allows us to tension the graft adequately with minimum sockets length. We present a case of 16 years old male who underwent all-epiphyseal all inside reconstruction with our rehabilitation protocol.

**Keywords:** Periprosthetic joint infection, knee arthroplasty and surgery.



This is an open access article under the [CC-BY-SA](https://creativecommons.org/licenses/by-sa/4.0/) license.

#### Article History:

Submission : September 10th, 2022  
Revision : December 6th, 2022  
Accepted : July 23th, 2023

#### Corresponding Author:

Imelda Lumban Gaol  
Fellow of Indonesia Hip and Knee Society, Orthopaedic Surgery Department, Dr. Soetomo General Hospital, Surabaya, Indonesia  
[pina\\_mail2000@yahoo.com](mailto:pina_mail2000@yahoo.com)

## **INTRODUCTION**

Anterior cruciate ligament injuries are commonly seen in active and young patients (1,2). Nowadays, the incidence of ACL injury in skeletally immature patients is increased (1,3,4,5). This is caused by multifactorial, including increased sports participation, increased competitive sports at younger ages, as well as the improvement of recognition of this injury, and the use of Magnetic resonance imaging MRI (1,2). The incidence was 1/10.000 in 2005-2008 at age 8 to 14 years old, but this gradually increases with age (6). However, surgical techniques are still controversial. The goal is to preserve physeal plate. The traditional surgical technique, which drills the tunnel across the physis, might damage the physis and cause growth disturbance.

There are some options of surgical techniques for ACL reconstruction in prepubescent, including physeal sparing reconstruction, partial transphyseal reconstruction, or transphyseal reconstruction. The physeal sparing using iliotibial band can minimize the risk of iatrogenic physeal injury and is indicated for Tanner stage I or II (7). All ACL reconstruction in prepubescent tried to minimize the risk of iatrogenic injury of physeal plate, but none of those techniques provide the reconstruction at the footprint of the ACL (1,3).

The all-epiphyseal technique by Lawrence is also another option for physeal sparing reconstruction. This technique tries to reconstruct ACL as adult ACL reconstruction principles but also minimizes the risk of iatrogenic physeal

injury. There is still a possibility of injuring the physeal plate in this technique, although it is minimal (3). Another physeal sparing technique is all-inside all-epiphyseal technique. In this technique, no drill at all at the tibial physeal plate.

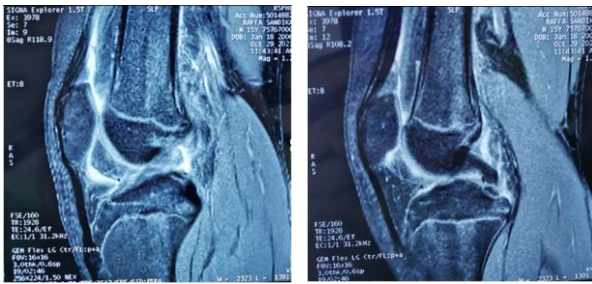
We describe the all-inside all-epiphyseal technique for ACL reconstruction in prepubescent patients. This technique minimizes physeal injury and restores intra-articular anatomy of ACL.

## **PRESENTATION OF CASE**

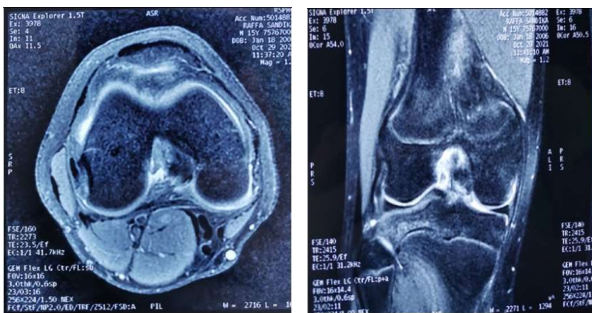
Male, Mr. R, 16 years old, complained of pain and unstable of his right knee during walking. He got an injury while he was playing football. His knee was swollen after the injury and felt pain afterward. From physical examination was found no swollen. He was able to fully flex his right knee with pain and fully extend his right knee without pain. No abnormality was found during walking. From the specific test, we found anterior drawer test +3, Lachman test +3, no pivot shift test, and McMurray was negative.

From the conventional knee radiograph, we found the opening of physeal plate on the distal femoral, proximal tibial, and proximal fibular. The magnetic resonance imaging (MRI) study confirmed the presence of an acute, complete rupture of the ACL. The patient completed preoperative physical therapy and underwent all-inside all-epiphyseal ACL reconstruction with hamstring autograft. Postoperatively, no pivot shift test with negative Lachman test and anterior drawer were found. The postoperative physical therapy was as described earlier.

**ALL-EPIPHYSEAL ALL-INSIDE TECHNIQUE FOR ANTERIOR CRUCIATELIGAMENT RECONSTRUCTION IN PREPUBESCENT PATIENT: A CASE REPORT**

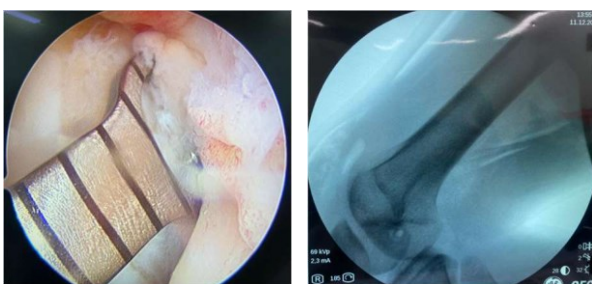

(A) (B)



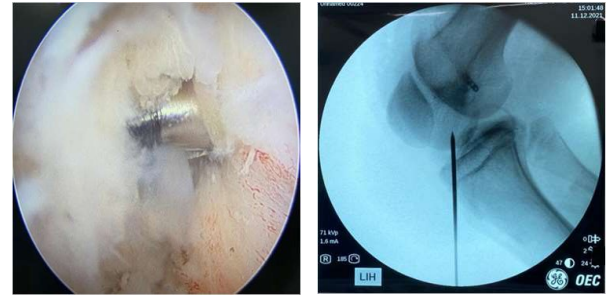
(C) (D)

**Figure 1.** MRI of the right knee (A) Sagittal view of the right knee shows no ACL was seen (B) Sagittal view shows elongation of PCL (C) Axial view shows diminished ACL at femoral insertion (D) Coronal view shows no ACL was seen with hyperintense of the femoral insertion, while PCL was seen at the femoral insertion.



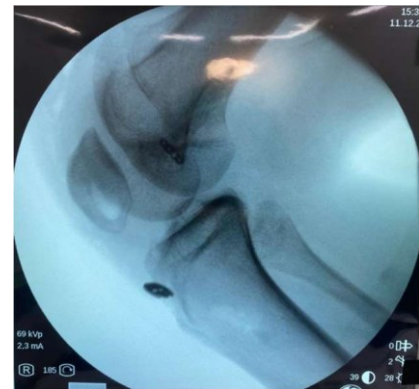
(A) (B)

**Figure 2.** (A) The femoral guide, as viewed through anteromedial portal with a 30° arthroscope, was placed at the ACL footprint that was cleaned previously (B) The femoral tunnel was confirmed under fluoroscopy.

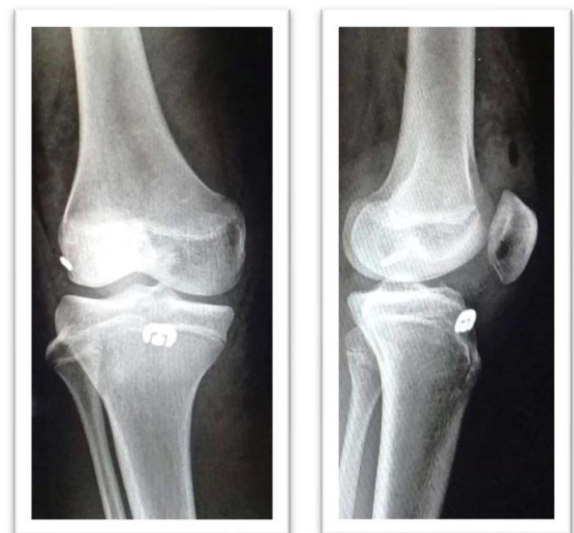

(A) (B)

**Figure 3.** (A) The tibial tunnel, as viewed through anterolateral portal with a 30° arthroscope, was drilled at the ACL footprint (B) The tibial tunnel was confirmed under fluoroscopy.



(A)



(B) (C)

**Figure 4.** (A) Fluoroscopy postoperative (B) Postoperative radiograph AP view of the right knee (C) Postoperative radiograph

lateral view of the right knee of all-epiphyseal all-inside ACL reconstruction and fixation with Infinity knee system (Conmed).

Standard diagnostic knee arthroscopy is performed through standard anteromedial working and anterolateral viewing portals. Check for the chondral and meniscal pathology and address it appropriately. Diagnosis of complete tear of ACL is confirmed (Figure 1). The residual ACL is removed as needed, only to make it easy to identify the tibial and femoral footprints. All soft tissue excess is removed. A 30° arthroscope is routinely used (Figure 2).

The autologous quadrupled hamstring graft is prepared. Using standard technique, semitendinosus is harvested and prepared by whipstitching the ends of the tendon and then looping them over an Etibond suture number 2. The femoral side of the graft is marked 15 mm or 20 mm, depending on the length of the femoral socket. The length of the intraarticular graft is 2 cm, and a minimum 8 mm graft diameter is preferred. If the graft diameter is insufficient, gracilis is harvested as well. The graft length minimum is 6 cm. The looped end also is whipstitched, preventing the graft from rolling intraluminal. The tibial side of the graft is also marked 15 mm or 20 mm, depending on the length of the tibial socket. The graft is prepared using the infinity knee system (Conmed), where the infinity adjustable loop button is on the femoral side and the infinity tibial button is on the tibial side. The graft is sized, pretensioned to 20 lb for 5 minutes, and then wrapped in damp gauze.

The femoral tunnel is prepared first. The outside in femoral ACL guide (Arthrex), set at 95° is placed through the anterolateral portal, onto the center of the femoral footprint, 3 mm from the back of the wall. The placement is checked by the 30° arthroscope through the anteromedial portal (Figure 3). 1.5-2 cm incision is made over the lateral femur, followed by dissection, and put the guide just anterior and distal to the lateral epicondyle. The wire is drilled through the femoral guide from the lateral cortex to the footprint.

It should be parallel to the physis in the epiphysis to the center of the femoral footprint. This position should be checked by fluoroscopy. Once the position is confirmed, the femoral guide is removed, leaving the wire in place. The flipcutter with the appropriate diameter is introduced into the articular. The flipcutter is deployed and is used to drill the femoral socket retrograde approximately 15 to 20 mm. The flipcutter is then advanced to the joint, straightened, and removed through the lateral cortex of femur. A FiberStick is advanced through the guide, delivered out through the anteromedial portal, and tagged for graft passage.

The tibial ACL guide is set at 50°, and advanced through anteromedial portal, placed over the center of the anatomic footprint of ACL. The tibial guide is placed in diving direction to avoid the physeal plate. The position of the tibial guide is checked by fluoroscopy. Once the position is confirmed, the flipcutter is drilled retrograde within tibial epiphysis. The flipcutter is deployed and used to drill the tibial socket approximately 15-20 mm. A

Fiberstick is advanced through the socket and retrieved through the anteromedial portal and tagged for graft passage (Figure 4).

The sockets are evaluated and checked for the placement and the soft tissue in the sockets. Make sure no soft tissue entered the socket. Pass the graft through the anteromedial portal. The graft enters the femoral socket first using the previously passed Fiberstick. The button is engaged to the lateral cortex and flipped. The graft is pulled until the marked just into the edge of the socket. The tibial side of the graft is also advanced into articular through the anteromedial portal. Using the previous Fiberstick, the graft entered the tibial socket and tensioned until the marked side of the tibial graft side entered the socket. While holding and tensioning the graft, the knee is cycled numerous times.

Checked the graft arthroscopically. If the graft position is confirmed, the graft is tensioned in knee flexed 30°, neutral rotation, and posterior drawer at the same time. The tibial button is flipped and tightened. After tensioning, the graft is rechecked again in flexion and extension, to make sure there is no impingement, and the graft is tension. Irrigated and closed the wounds in layers. The knee is dressed in sterile dressings and a knee brace locked in maximum extension. Physical therapy begins on postoperative day 1. The patient is weight-bearing as tolerated. Formal physical therapy with an accelerated ACL protocol is initiated 2 weeks postoperatively and continued until 4 months.

## DISCUSSION

Treating immature patients with ACL total rupture is challenging. Several techniques were found, including physeal sparing reconstruction, partial transphyseal reconstruction, or transphyseal reconstruction. The first physeal sparing technique was introduced by Micheli (8) and Kocher et al (4). They modified the combination of intraarticular and extraarticular ACL reconstruction described by MacIntosh and Darby. This technique used iliotibial band strip as a graft. They cut the proximal part and brought it into the knee in over-the-top position and brought it under the intermeniscal ligament anteriorly.

The graft was sutured to the intermuscular septum on the femoral side and to the periosteum on the tibial side. (4) This technique did not put the graft on the native ACL; therefore, it distorted the native ACL function. Besides, a lot of pitfalls are also seen in this technique, which was a very technically demanding technique (1). This technique gave 13.6% reoperation rate (9), while the revision rate of transphyseal technique in immature patients is 3.1% (10). which is lower than transphyseal technique, 10.4% (11). But the latest research by Patel et al showed no difference in graft failure between all-epiphyseal and transphyseal techniques, with graft failure rates 9.8% and 10.4% respectively (11).

Guzzanti et al described the new all-epiphyseal technique. This technique used hamstring and gracilis as graft sources, detached the proximal, and left the distal

side attached to its insertion. A hole was then drilled from the space between the pphysis and cartilage of the proximal tibia to tibial eminence. Passed the graft through the tibial tunnel into the intra-articular. For the femoral attachment, a staple was inserted into the femoral epiphysis, and the hamstring was looped and entered the tibial tunnel again, and sutured side to side (12). This technique did not make tunnel on the femoral, only a small part of the femoral, which is centrally and vertically placement of the femoral staple. The tibial tunnel is eccentric.

Another physeal sparing technique is by Anderson. He used free hamstring graft. He drilled the femoral tunnel in line with the physeal plate, inside the epiphysis. The tibial tunnel was drilled at the free edge of the lateral meniscus and the posterior footprint of the ACL, in the same fashion as Guzzanti technique on the tibial side and used post-screw on the tibial side (7,13) Either Guzzani or Anderson technique showed good postoperative results (12,13).

The surgical technique we used here is the same as Anderson. The difference is we used all-inside technique with retrodrill and the Infinity knee system, which is a free loop system. Using this technique, we were able to tension the graft adequately with only minimum graft length. By using this system, we only made sockets for the femoral and the tibial side with a minimum of 15 mm. This technique will preserve the tibial pphysis. We also used femoral guide to make sure that the transphyseal reconstruction. The first physeal sparing technique was introduced by Micheli (8) and Kocher et al (4). They modified the combination of

intraarticular and extraarticular ACL reconstruction described by MacIntosh and Darby.

This technique used Iliotibial band strip as a graft. They cut the proximal part and brought it into the knee in over-the-top position and bought it under the inter meniscal ligament anteriorly. The graft was sutured to the intermuscular septum on the femoral side and to the periosteum on the tibial side (4). This technique did not put the graft on the guide wire was parallel to the physeal plate and entered the one-fourth posterior part along the Blumensaat line and one-fourth proximal of the distance from the Blumensaat line down to the edge of the condyle. The placement of the tibial tunnel is crucial. As we know, the obliquity of the tibial drill hole will result in the placement of the tibial tunnel. The more vertical the tibial guide will result in the more anterior position of the tibial tunnel. This will be technically demanding. But in the end, all the fixation methods using this technique are entirely within the epiphyseal area.

Different from the technique described by Lawrence et al. They drilled the tibial tunnel through the pphysis to the ACL footprint and used retrodrill (Arthrex). This technique will result in a more anatomic location of the tibial tunnel, rather than the technique described by Anderson, Guzzanti, or our technique. But Lawrence technique needs at least 20 mm length of the tibial tunnel to be able to enter the retroscrew. 1 Using the retroscrew in a small knee will be difficult and can injure the graft or might cause growth disturbance if the placement is too close to the pphysis or across the pphysis.

This Lawrence technique also needs intraoperative computed tomography scan, as recommended by Lawrence (3)

The rehabilitation protocol for ACL reconstruction in skeletally immature patients is different than the adult patients. Limited early weight-bearing and ROM are advised in ACL reconstruction skeletally immature (14,15). In physeal-sparing technique, the tibial tunnel placement is eccentric and less anatomic if we compare it with transphyseal technique. We should choose the rehabilitation protocol that gives less adverse load with immediate loads. Controversial also seen in deciding return to sport after ACL reconstruction in skeletally immature patients. A study done by Boyle et al showed that adolescent patients do not recover consistently to adequate functional movement patterns after 9 months postoperative to be able to return-to-sport (16).

Greenberg et al showed that even at 1 year after the surgery, some pediatrics have significant strength and functional deficits. Only 38% can achieve satisfactory performance on functional hop test at 12 months postoperative, and 25% were able to achieve satisfactory limb symmetry index. These patients required prolonged rehabilitation programs. 17 The main goal of ACL reconstruction is to return to sport. Restoration of symmetric quadriceps strength should be achieved to be able to return-to-sport in young athletes (18). Controversial is seen regarding rehabilitation protocol due to lack of study focusing on rehabilitation protocol after ACL reconstruction in skeletally immature patients. Therefore, no guidelines have

been established in rehabilitation protocol. Another important postoperative care after ACL reconstruction in pediatric patients is postoperative pain control. Femoral nerve block (FNB) is an option, but some patients might have weaker quadriceps and hamstring muscles. A study done by Luo et al found that patients without FNB can meet the criteria to return-to-sport 4 times higher than patients with FNB 6 months after the ACL reconstruction (19)

## CONCLUSIONS

The number of ACL injuries in prepubescent and young athletes is increasing. Therefore, every effort must be made to minimize physeal injury that might cause growth arrest. The improvement of technology and instrumentation allows us to use the physeal sparing technique with adequate results. But choosing the ideal rehabilitation protocol is also important to meet the criteria return-to-sport 6 months postoperative. This technique gave good results and no injury on the physeal plate was found. We believe this technique can be used as one of the options for physeal sparing techniques for ACL reconstruction in skeletally immature patients.

## REFERENCES

1. McCarthy MM, Graziano J, Green DW, Cordasco FA. All-Epiphyseal, All-Inside Anterior Cruciate Ligament Reconstruction Technique for Skeletally Immature Patients. *Arthrosc Tech*. 2012 Dec;1(2):e231–9.
2. Pennock A, Murphy MM, Wu M. Anterior cruciate ligament reconstruction in skeletally immature

- patients. *Curr Rev Musculoskelet Med.* 2016;9(4):445–53.
3. Lawrence TJR, Bowers AL, Belding J, Cody SR, Ganley TJ. All-epiphyseal Anterior Cruciate Ligament Reconstruction in Skeletally Immature Patients. *Clin Orthop Relat Res [Internet]*. 2010 Jul;468(7):1971–7.
  4. Kocher MS, Garg S, Micheli LJ. Physeal Sparing Reconstruction of the Anterior Cruciate Ligament in Skeletally Immature Prepubescent Children and Adolescents. *J Bone Jt Surg [Internet]*. 2006 Sep;88(1):283–93.
  5. Knapik DM, Voos JE. Anterior Cruciate Ligament Injuries in Skeletally Immature Patients: A Meta-analysis Comparing Repair Versus Reconstruction Techniques. *J Pediatr Orthop [Internet]*. 2020 Oct;40(9):492–502.
  6. Funahashi KM, Moksnes H, Maletis GB, Csintalan RP, Inacio MCS, Funahashi TT. Anterior Cruciate Ligament Injuries in Adolescents With Open Physis. *Am J Sports Med.* 2014 May 14;42(5):1068–73.
  7. Anderson AF, Anderson CN. Transepiphyseal anterior cruciate ligament reconstruction in pediatric patients: Surgical technique. *Sports Health.* 2009;1(1):76–80.
  8. Micheli LJ, Rask B, Gerberg L. Anterior Cruciate Ligament Reconstruction in Patients Who Are Prepubescent. *Clin Orthop Relat Res.* 1999 Jul;364:40–7.
  9. Willimon SC, Jones CR, Herzog MM, May KH, Leake MJ, Busch MT. Micheli Anterior Cruciate Ligament Reconstruction in Skeletally Immature Youths. *Am J Sports Med.* 2015 Dec 23;43(12):2974–81.
  10. Kumar S, Ahearne D, Hunt DM. Transphyseal Anterior Cruciate Ligament Reconstruction in the Skeletally Immature. *J Bone Jt Surg.* 2013 Jan 2;95(1):e1.
  11. Patel NM, DeFrancesco CJ, Talathi NS, Bram JT, Ganley TJ. All-epiphyseal Anterior Cruciate Ligament Reconstruction Does Not Increase the Risk of Complications Compared With Pediatric Transphyseal Reconstruction. *J Am Acad Orthop Surg.* 2019 Aug;27(16):e752–7.
  12. Guzzanti V, Falciglia F, Stanitski CL. Physeal Sparing Intraarticular Anterior Cruciate Ligament Reconstruction in Preadolescents. *Am J Sports Med.* 2003 Nov 7;31(6):949–53.
  13. Anderson AF. Transepiphyseal replacement of the anterior cruciate ligament using quadruple hamstring grafts in skeletally immature patients. *J Bone Joint Surg Am.* 2004;86 A Suppl (Pt 2):201–9.
  14. Streich NA, Barié A, Gotterbarm T, Keil M, Schmitt H. Transphyseal reconstruction of the anterior cruciate ligament in prepubescent athletes. *Knee Surgery, Sport Traumatol Arthrosc.* 2010 Nov 4;18(11):1481–6.
  15. Liddle AD, Imbuldeniya AM, Hunt DM. Transphyseal reconstruction of the anterior cruciate ligament in prepubescent children. *J Bone Joint Surg Br.* 2008 Oct;90B(10):1317–22.
  16. Boyle MJ, Butler RJ, Queen RM. Functional Movement Competency and Dynamic Balance After Anterior Cruciate Ligament Reconstruction in

- Adolescent Patients. *J Pediatr Orthop.* 2016 Jan;36(1):36–41.
17. Greenberg EM, Greenberg ET, Ganley TJ, Lawrence JTR. Strength and Functional Performance Recovery After Anterior Cruciate Ligament Reconstruction in Preadolescent Athletes. *Sport Heal A Multidiscip Approach.* 2014 Jul 27;6(4):309–12.
  18. Ithurburn MP, Paterno M V., Ford KR, Hewett TE, Schmitt LC. Young Athletes With Quadriceps Femoris Strength Asymmetry at Return to Sport After Anterior Cruciate Ligament Reconstruction Demonstrate Asymmetric Single-Leg Drop-Landing Mechanics. *Am J Sports Med.* 2015 Nov 10;43(11):2727–37.
  19. Luo TD, Ashraf A, Dahm DL, Stuart MJ, McIntosh AL. Femoral Nerve Block Is Associated With Persistent Strength Deficits at 6 Months After Anterior Cruciate Ligament Reconstruction in Pediatric and Adolescent Patients. *Am J Sports Med.* 2015 Feb 2;43(2):331–6.