




CASE REPORT

Quincke's disease, a rare clinical disorder: a case report

Zikry Mohammad Gifari*  

* RSUD Majalaya, Bandung Regency, Indonesia

* Correspondence Author:

 zikry.gifari73@gmail.com

Date of first submission, September 8, 2024

Date of final revised submission, February 27, 2025

Date of acceptance, March 5, 2025

Cite this article as: Gifari ZM. Quincke's disease, a rare clinical disorder: a case report. Univ Med 2025;44:84-89

ABSTRACT

BACKGROUND

Quincke's disease, or isolated uvular angioedema, is a rare clinical condition and reports on its etiology and management remain limited. Most cases are linked to idiopathic conditions, food allergies, airborne allergens, medications (ACE inhibitors, NSAIDs), hereditary angioneurotic edema, oropharyngeal trauma, and infections. The disease may be encountered in any emergency setup and must be dealt with rapidly and with utmost vigilance to prevent progression and complications.

CASE DESCRIPTION

A 24-year-old man visited the primary care clinic complaining of sudden throat discomfort upon waking. He described it as the sensation of a round object touching "the sides of his throat". The sensation persisted despite swallowing. The patient denied having a sore throat, hoarseness, fever, or cough, and said that he had never experienced similar symptoms. The patient did not consume anything before he went to sleep and woke up with the sensation that something was 'stuck' in the back of his throat. Examination revealed an edematous and hyperemic uvula. Initial management ensured that there was no airway obstruction, with antihistamines and corticosteroids administered to relieve the uvular edema and discomfort. The patient said that the symptoms subsided within 72 hours and that there was no recurrence.

CONCLUSION

Awareness about this rare but acute condition, even in the background of unknown etiology, in all medical personnel is essential. Early diagnosis with appropriate management can prevent life-threatening airway obstruction and hypoxemia. Treatment depends on airway symptom severity. Thorough examination of each case is crucial, focusing on etiology and definitive management.

Keywords: Quincke's disease, etiology, uvular edema, angioedema, airway

INTRODUCTION

Isolated uvular angioedema, also known as Quincke's disease, is a rare form of upper airway angioedema. Most cases arise from conditions such as idiopathic disease, food allergies, airborne allergens, medications (ACE inhibitors, NSAIDs), hereditary angioneurotic edema, oropharyngeal

trauma, and pharyngotonsillar infections. To prevent airway obstruction and respiratory disturbances, careful monitoring and management are essential.⁽¹⁾

In 1882, Heinrich Irenäus Quincke first described acute edema, distinguishing it from urticaria. The term "angioneurotic edema," initially used by Quincke to describe edema

without urticaria or pruritus, was later changed to "Quincke's edema," a synonym for non-allergic angioedema.⁽²⁾ According to the 2014 Berlin consensus paper by the International Working Group on Hereditary Angioedema, non-allergic angioedema includes hereditary angioedema and acquired angioedema.⁽²⁾

The epidemiology of Quincke's disease remains poorly documented. Over the past two decades, several causes have been studied. Type I hypersensitivity reactions, triggered by trauma, thermal injury, infection, or drug use (e.g., marijuana, cocaine), are among the most reported causes.⁽³⁾

Angioedema manifests as localized, asymmetric swelling of skin or mucosa, typically non-pruritic, mainly in areas with loose connective tissue. Mast cell-mediated angioedema often presents with other mast cell mediator symptoms such as flushing, urticaria, pruritus, rhinorrhea, nasal congestion, bronchospasm, dysphagia, abdominal pain, and cardiovascular symptoms.⁽⁴⁾ Conversely, bradykinin-induced angioedema lacks urticaria and other signs of a hypersensitivity reaction.⁽⁴⁾ While antihistamines are effective for mast cell-mediated angioedema (histaminergic), bradykinin-mediated angioedema is refractory to antihistamine therapy.⁽⁴⁾

Quincke's disease is not related to hypersensitivity reactions such as skin rashes, hypotension, or tachycardia. It presents as rapid-onset, localized, non-pruritic subcutaneous or submucous swelling. Kinin and complement pathways mediating type I hypersensitivity are considered possible mechanisms, though idiopathic cases remain unexplained.⁽³⁾

Airway management is the primary strategy for Quincke's edema. Treatment includes monitoring, oxygen therapy, epinephrine when indicated, H1 and H2 antagonists, and dexamethasone.⁽³⁾ Most cases described in the literature are acute episodes managed in emergency departments or outpatient settings with minimal follow-up.⁽⁵⁾ Many cases were successfully managed with medical therapy and had no prior episodes.⁽⁵⁾

Although rare, Quincke's disease can be life-threatening if the airway is compromised by an enlarged uvula.⁽⁶⁾ Healthcare professionals must remain vigilant and prepared for emergencies in affected patients.⁽⁷⁾

The case is important because of the acute and spontaneous nature of the symptoms and the potential to cause life-threatening airway compromises.⁽³⁾ This case report aims to enhance knowledge about the diagnosis and proper treatment of Quincke's disease, particularly in addressing its rare idiopathic background and life-threatening implications.

CASE REPORT

Mr. S, a 24-year-old man, came to a primary healthcare facility complaining of discomfort in his throat upon waking up from sleep. The patient also reported an unpleasant sensation in the throat area when breathing, which caused him to wake up from sleep. He described the sensation as if a round object was creeping and touching the sides of his throat. The patient attempted to swallow, but the discomfort did not disappear.

The patient denied having a sore throat, hoarseness, fever, or cough, and said that he had never experienced similar symptoms. The patient did not consume anything before he went to sleep and woke up with the sensation that something was 'stuck' in the back of his throat. The patient mentioned a history of allergy to cold temperatures. The patient has a history of smoking.

On physical examination: Glasgow Coma Scale E4M6V5 compos mentis, blood pressure 118/78 mmHg, pulse rate 80 beats per minute, respiratory rate 20 breaths per minute, and temperature 36.7°C. Examination of the oral cavity revealed hyperemia of the uvula and soft palate of the oropharynx (Figure 1), with edema of the uvula, the uvula appearing elongated, differing from its standard size (Figure 2). There were no complaints of stridor, hoarseness (dysphonia), or swallowing difficulties.

No laboratory tests or radiological examinations were performed. To address the throat pain and uvular edema, the patient was given initial treatment with the following oral medications: paracetamol 3x500 mg, dexamethasone 2x0.5 mg, and cetirizine 2x10 mg. The patient was referred to an ENT specialist. According to the patient, the symptoms subsided within 72 hours and no recurrence occurred. Consent was obtained from the patient for the publication of this article and any accompanying images.

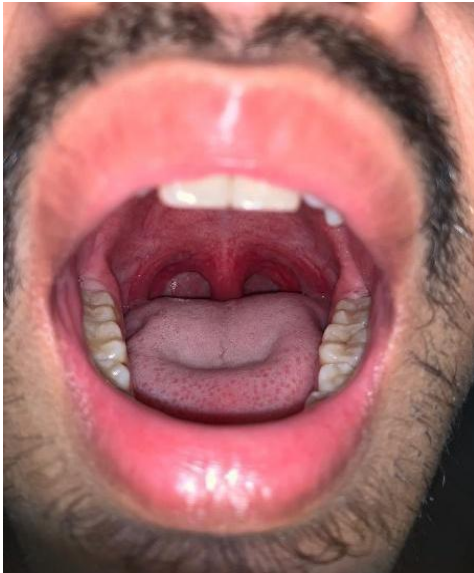

Figure 1. Hyperemia of the uvula and soft palate of the oropharynx

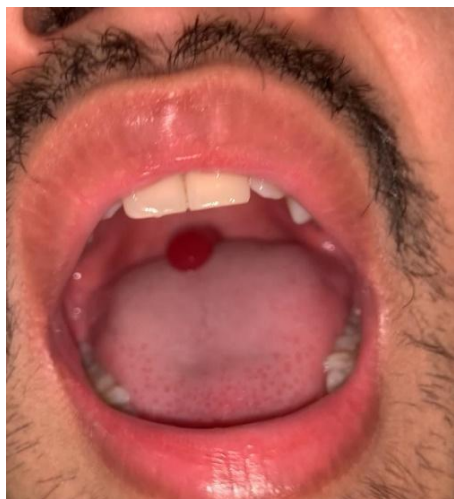
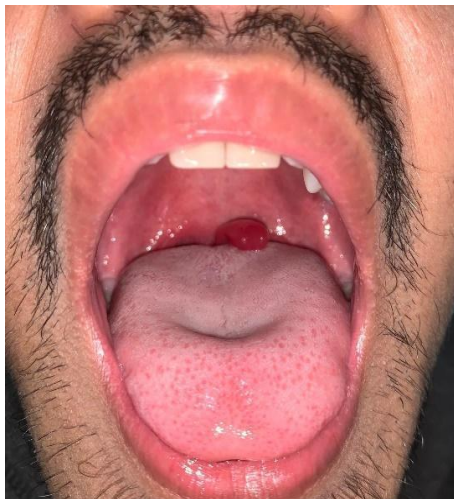
Figure 2. Edema of the uvula, and the uvula appears elongated

DISCUSSION

The uniqueness of Quincke's disease in this case was that it was not caused by medications, trauma, or infection. This differs from most other case reports where Quincke's disease is caused by drug exposure or trauma during general anesthesia. This case report will discuss the management of each previously reported case as a reference for management and treatment.

Type 1 hypersensitivity reactions typically cause isolated angioedema, but this condition can also be caused by trauma, thermal injury, infections, medications (ACE inhibitors,^(8,9) Alprazolam,⁽¹⁰⁾ herbal substances (cannabis), and idiopathic conditions.^(7,11) There are two reports on the use of narcotic drugs such as cocaine being associated with Quincke's disease.^(12,13)

A study conducted in Spain by Barbarroja et al.⁽¹⁴⁾ revealed the characteristics of predisposing factors and the etiology of patients diagnosed with uvular edema at the University Hospital of Alcalá de Henares. A total of 66.1% or 113 out of 171 patients had isolated uvular edema without other clinical manifestations, with most causative factors being food allergies in 37 patients, medications in 20 patients, certain medical conditions (infection, cancer, gastroesophageal reflux, tonsillectomy) in 28 patients, and idiopathic causes in 28 patients.

Angioedema is divided into two main clinical types: mast cell-mediated angioedema and bradykinin-mediated angioedema. Mast cell-mediated angioedema is usually accompanied by symptoms of the release of mast cell mediators, such as urticaria; the symptoms appear within minutes to hours after exposure to an allergen, then resolve within 24 to 48 hours, and typically respond satisfactorily to antihistamine treatment.⁽⁴⁾

Bradykinin-mediated angioedema encompasses a spectrum of rare disorders in which the angioedema is isolated, not associated with urticaria or other signs of allergic reactions. Additionally, this type of angioedema does not respond to antihistamine therapy, regardless of the dosage. It also does not respond to corticosteroids, while epinephrine provides mild and temporary clinical benefit.⁽²⁾

Hereditary angioedema (HAE) or congenital C1 inhibitor (C1INH) deficiency is a rare genetic disorder caused by a deficiency (type I) or dysfunction (type II) of C1INH. Hereditary angioedema caused by C1 deficiency is an

autosomal dominant disorder with nearly complete penetrance in 50% of male and female children of parents diagnosed with HAE.⁽⁴⁾ In the general population, the prevalence ranges from 1:30,000 to 1:80,000, making this condition quite rare.^(4,9) The hereditary form of Quincke's disease probably follows this pathway due to deficient C1 esterase inhibitor which is the main regulator for both kinin and complement pathways.⁽³⁾

In our reported case, no signs or symptoms of throat infection, such as fever, exudate, cough, or

lymphadenopathy (Centor score parameters), were found. No cause pointing to trauma, thermal injury, or medication use was identified in this patient. The patient denied any history of food allergies, but further examination regarding the patient's allergic history is needed.

From the literature reports on Quincke's disease published over the last decade, the author presents the case report findings in Table 1 below.

Table 1. Comparison of case reports with the present case

Report by	Age (years)	Sex	Underlying etiologies	Clinical Manifestation	Therapy
Tripathy N, Gupta N ⁽¹⁾	35	Male	Food allergens	An object touching the walls of his throat, difficulty swallowing	dexamethasone, and antihistamine
Kamath R, Rai SJ ⁽³⁾	3	Male	idiopathic	Something touching the back of the tongue	dexamethasone, pheniramine hydrogen maleate
Sullivan GW, et al. ⁽⁵⁾	29	Male	idiopathic (non-histaminergic)	discomfort in the throat, episodic symptoms.	uvulectomy
Sanchez G, et al. ⁽⁷⁾	50	Male	idiopathic	difficulty speaking, pain, recurring symptoms.	corticosteroid, partial uvulectomy
Elfessi Z, et al. ⁽⁸⁾	59	Male	ACE-I, acquired angioedema	painful swallowing, dry cough.	dexamethasone
Gomes P, et al. ⁽¹⁰⁾	56	Male	Alprazolam	foreign body sensation in throat	antihistamine, corticosteroid
Goncalves F, et al. ⁽¹³⁾	27	Male	Cocaine	foreign body sensation in throat	antihistamine, corticosteroid, adrenaline
Chandran A, et al. ⁽¹⁶⁾	32	Male	Consumed seafood (prawns)	'stuck' in the back of his throat	dexamethasone. chlorpheniramine maleate and epinephrine
Belfeki, et al. ⁽¹⁸⁾	47	Male	GERD, trauma	difficulty breathing	antihistamine
Gandhi R ⁽¹⁹⁾	32	Male	trauma	discomfort in throat	antihistamine, corticosteroid, antibiotic, NSAID.
Present report	24	Male	Idiopathic	discomfort in his throat upon waking up from sleep	antihistamine, corticosteroid, NSAID. Referred to ENT

The symptoms vary in each case, but the most commonly reported symptoms in case reports are discomfort, a foreign body sensation in the throat, difficulty swallowing, and throat pain. In some literature reports the patient's symptoms include hoarseness, choking, snoring, difficulty breathing, and even obstructive sleep apnea.^(13,15)

Supplementary examinations should be conducted on patients with clinical suspicion of Quincke's disease. Recommended examinations to identify the cause include determination of C1 esterase and mast cell tryptase levels, skin prick tests, complete blood count, erythrocyte sedimentation rate, radioallergosorbent tests (RAST), throat and uvula swab cultures, blood cultures, and latex agglutination studies to identify *Haemophilus influenzae* type B (HIB) and *Streptococcus pneumoniae* antigens in blood and urine.⁽³⁾

The primary focus in treating patients with Quincke's disease is the threat to the airway. Initial therapy is centered on airway clearance if the patient has airway problems. In some cases, patients with Quincke's disease complain of difficulty swallowing and shortness of breath.^(11,17) The physicians must consider intubation and intravenous (parenteral) access. Medications such as epinephrine, H1 and H2 receptor blockers (such as diphenhydramine HCl and cimetidine) and corticosteroids (such as methylprednisolone and dexamethasone) are necessary in severe cases. The plasminogen inhibitor ϵ -aminocaproic acid may be given to patients with possibly non-infectious causes who do not respond to the above treatments. In additional cases, inhaled corticosteroids or nebulized beta-2 agonists, such as salbutamol or albuterol, may be administered. Due to its potent anti-inflammatory properties and long half-life, dexamethasone is one of the most commonly used corticosteroids.⁽¹⁷⁾ Antibiotics are required if the cause is an infection.⁽⁶⁾ Surgical treatment, due to its high morbidity, plays a minimal to nonexistent role in the treatment protocol for Quincke's disease.⁽⁷⁾ In some cases of recurrent episodic Quincke's disease that fail to respond to conservative treatment, uvulectomy may be a safe and effective procedure.⁽⁵⁾ In the present case report, the most probable etiology is an allergy that causes a type 1 hypersensitivity reaction; however, this has not been confirmed, and further supplementary examinations are needed.

CONCLUSION

Isolated angioedema of the uvula is a sign of Quincke's disease, which is considered a rare case. The etiology of this disease remains unknown; however, several reports on this condition have included food allergies such as to peanut or shrimp, infections, mechanical pressure or trauma from regional or general anesthesia, herbal medications, drugs such as ACE inhibitors or angiotensin receptor blockers (ARBs), and idiopathic causes. It is recommended to conduct more in-depth supplementary examinations to determine the definitive cause, such as skin prick tests, complete blood counts, erythrocyte sedimentation rates, radioallergosorbent tests (RAST), throat and uvula swab cultures, blood cultures, and latex agglutination tests to identify *Haemophilus influenzae* type B (HIB) and *Streptococcus pneumoniae* antigens in blood and urine, as well as toxicological tests and cervical X-rays. Management of Quincke's disease depends on the severity of airway symptoms. Intravenous H1 and H2 blockers, corticosteroids, and even epinephrine may be required in emergency situations. If there is refractory C1 esterase deficiency, fresh frozen plasma (FFP) or epsilon-aminocaproic acid can be used. Due to its high morbidity, surgical procedures play a minimal role in the management protocol of Quincke's disease but may be considered in recurrent and difficult cases. It is crucial to conduct a thorough examination in each case as knowledge about this rare disease is still evolving, especially regarding its etiology.

Conflict of Interest

None declared.

Acknowledgments

We would like to thank everyone, especially the patients for his participation in this case report.

Funding

None.

Data Availability Statement

Available from the author.

Declaration of Use of AI in Scientific Writing

Nothing to declare.

REFERENCES

1. Tripathy N, Gupta N. Isolated angioedema of uvula (Quincke's disease): a rare presentation. *J Otorhinolaryngol Allied Sci* 2018;1:37-38.
2. Hahn J, Greve J, Bas M, Kojda G. Bradykinin-mediated angioedema induced by commonly used cardiovascular drugs. *Drugs Drug Candidates* 2023;2:708–27. <https://doi.org/10.3390/ddc2030036>.
3. Kamath R, Rai SJ. Quincke's disease: a case repost. *Egypt J Otolaryngol* 2020;36:44. <https://doi.org/10.1186/s43163-020-00048-8>.
4. Nedelea I, Deleanu D. Isolated angioedema: an overview of clinical features and etiology. *Exp Ther Med* 2019;17:1068-72. DOI: 10.3892/etm.2018.6982.
5. Sullivan GW, Mendelsohn LT, Shah RR. Treatment of recurrent and refractory Quincke's disease with topical antihistamines and uvulectomy. *Otolaryngol Case Reports* 2023;29: 100557. <https://doi.org/10.1016/j.xocr.2023.100557>.
6. Bakshi SS. Life-threatening upper airway compression: Quincke's disease. *Eurasian J Emerg Med* 2018;17:205–6. DOI: 10.5152/eajem.2018.92485.
7. Sanchez G, Boot M, Lathif A. Quincke's disease: an unusual pathology. *J Surg Case Rep* 2023;3: rjad085. doi: 10.1093/jscr/rjad085.
8. Elfessi Z, Lee JA, Anvery SA, Acosta A. Angiotensin converting enzyme inhibitor induced Quincke's disease: a case report. *Visual J Emerg Med* 2022; 29: 101552 <https://doi.org/10.1016/j.visj.2022.101552>.
9. Pall AH, Lomholt AF, Buchwald CV, Bygum A, Rasmussen ER. Clinical features and disease course of primary angioedema patients in a tertiary care hospital. *J Asthma Allergy* 2020;13 225–36 DOI: 10.2147/JAA.S245161.
10. Gomes PM, Carcao A, Costa JB, Duarte D, Azevedo P. Quincke's disease by alprazolam: a case report. *Otolaryngol Online J* 2022;12:291 DOI: 10.35841/2250-0359.12.9.291.
11. Mohammadi L, Miller A, Ashurst JV. Quincke's disease. *J Family Med Prim Care* 2016;5:677-9. DOI: 10.4103/2249-4863.197308.
12. Olayode A. Case of cocaine-induced Quincke's disease. *Chest* 2023;164:A92. <https://doi.org/10.1016/j.chest.2023.07.113>.
13. Goncalves FMF, Costa M, Campos AL, Cotter J. Quincke's disease presenting after cocaine exposure. *Cureus* 2022;14:e30536. DOI: 10.7759/cureus.30536.
14. Escudero B, Barco DA, Gonzales SMJ, et al. Heterogeneous predisposing factors and etiology of edema of the uvula in a Spanish population. *J Investig Allergol Clin Immunol* 2019;29:280-6 doi: 10.18176/jiaci.0324.
15. Chang ET, Baik G, Torre C, Brietzke SE, Camacho M. The relationship of the uvula with snoring and obstructive sleep apnea: a systematic review. *Sleep Breath* 2018; 22:955–61. doi: 10.1007/s11325-018-1651-5.
16. Chandran A, Sakthivel P, Chirom A S. Quincke's disease. *BMJ Case Rep* 2019; 12:e231967. doi: 10.1136/bcr-2019-231967.
17. Forrest A, Milne N, Soon A. Hereditary angioedema: death after a dental extraction. *Aust Dent J* 2017. 62: 107–10. doi: 10.1111/adj.12447.
18. Belfeki N, Zayet S, Sy O, et al. Consecutive severe orofacial complications in intensive care unit patients: Quincke's disease and macroglossia due to prolonged prone positioning for management of acute respiratory distress syndrome. *Eur J Case Rep Intern Med* 2022;9:003421. doi: 10.12890/2022_003421.
19. Gandhi R. Postoperative uvular edema after general anesthesia in an adult patient. *J Anesthesiol* 2018;10:6 <https://doi.org/10.1186/s42077-018-0007-5>.



This work is licensed under a Creative Commons Attribution-NonCommercial-ShareAlike 4.0 International License