

THE LEVELS OF IL-6, CRP, AND LDH IN THE VITREOUS HUMOUR OF DIABETIC RETINOPATHY PATIENTS.

Kalyan Singh¹, Perwez Khan¹, Lubna Khan², Shalini Mohan¹, Parul Singh¹, Surbhi Agarawal¹
Namrata Patel¹, Disha Datta¹

¹Department of ophthalmology, GSVM medical college, Kanpur, Uttar Pradesh, India

²Department of Pathology, GSVM medical college, Kanpur, Uttar Pradesh, India

Abstract

Introduction: Diabetic retinopathy (DR) is a significant complication of diabetes mellitus (DM) and remains a leading cause of vision loss among working-age individuals. Level of inflammatory biomarkers rise in DR. Main focus on Interleukin-6(IL-6), C-Reactive Protein (CRP) and Lactate Dehydrogenase (LDH) as IL-6 induces excess production of VEGF, CRP has both pro-inflammatory and anti-inflammatory properties whereas, LDH acts through oxidation process on pyruvate to be converted into lactate. Altered lactate levels reflect changes in glucose metabolism rates or pyruvate levels.

Methods: Prospective hospital-based cross-sectional study was carried out on diagnosed cases of Diabetic Retinopathy at a tertiary care centre. Selection of 50 patients was done as per inclusion criteria and exclusion criteria.

Results: Among NPDR patients, Mean of IL-6 levels was 23.59 ± 19.02 , LDH was 99.46 ± 51.17 CRP was 0.49 ± 0.30 whereas in PDR patients, Mean of IL-6 was 58.91 ± 26.50 , LDH was 202.5 ± 63.93 and CRP was 0.93 ± 0.33 showing 2-fold raised in PDR patients.

Conclusion: Our study emphasizes the crucial role of inflammatory biomarkers in the pathogenesis of diabetic retinopathy. The elevated levels of IL-6, LDH, and CRP in vitreous humor samples from PDR patients compared to NPDR patients indicate the activation of an inflammatory pathway during the disease's progression. This research paves the way for further investigations into targeted therapies that can modulate these inflammatory mediators, potentially improving the prognosis of diabetic retinopathy.

Keywords: IL-6, LDH, CRP, Diabetic retinopathy and Vitreous humor.

Cite This Article: SINGH, Kalyan et al. THE LEVELS OF IL-6, CRP, and LDH IN THE VITREOUS HUMOUR OF DIABETIC RETINOPATHY PATIENTS.. International Journal of Retina, [S.l.], v. 7, n. 1, p. 16, feb. 2024. ISSN 2614-8536. Available at: <<https://www.ijretina.com/index.php/ijretina/article/view/244>>. Date accessed: 27 feb. 2024. doi: <https://doi.org/10.35479/ijretina.2024.vol007.iss001.244>.

Correspondence to:

Kalyan Singh,
Department of Ophthalmology,
GSVM medical college, Kanpur,
Uttar Pradesh, India,
singhkalyan1994@gmail.com

INTRODUCTION

Diabetes Mellitus (DM) is a metabolic disease characterized by persistently high levels of blood glucose. Is the leading cause of morbidity in the Indian subcontinent.^[1] DM encompasses several categories such as type 1 and type 2 diabetes, maturity-onset diabetes of the young (MODY), gestational diabetes, neonatal diabetes, and secondary causes resulting from endocrinopathies or steroid use, among others. The two primary subtypes of DM are Type 1 Diabetes Mellitus (T1DM) and Type 2 Diabetes Mellitus (T2DM), which arise from defects in insulin secretion (T1DM) and/or insulin resistance (T2DM). While T1DM typically affects children and adolescents, T2DM is commonly observed in middle-aged and older adults who experience prolonged hyperglycemia due to unhealthy lifestyles and dietary choices.

Type 2 Diabetes Mellitus (T2DM) has a gradual onset that stems from an imbalance between insulin levels and insulin sensitivity, leading to a functional deficiency of insulin. Multiple factors contribute to insulin resistance, with obesity and aging being the most common triggers.^[2]

Diabetic retinopathy (DR) is a significant complication of diabetes mellitus (DM) and remains a leading cause of vision loss among working-age individuals. The diagnosis of DR is based on clinical manifestations of vascular abnormalities in the retina. Clinically, DR is divided into two stages: non-proliferative diabetic retinopathy (NPDR) and proliferative diabetic retinopathy (PDR). NPDR denotes the early stage of DR, characterized by increased vascular permeability and the occlusion of retinal capillaries. This stage may not exhibit any symptoms, despite the detection of retinal

pathologies like microaneurysms, hemorrhages, and hard exudates through fundus photography. PDR represents a more advanced stage of DR and is characterized by the development of abnormal blood vessels. At this stage, patients may experience severe vision impairment due to vitreous hemorrhage (bleeding of abnormal vessels into the vitreous) or tractional retinal detachment. Diabetic macular edema (DME) is the most common cause of vision loss in individuals with DR. DME is characterized by the accumulation of fluid in the macula, resulting in its swelling or thickening. The breakdown of the blood-retinal barrier triggers this fluid accumulation.^[3]

The vitreous humor (VH) is a transparent, highly-hydrated gel located in the posterior segment of the eye, between the lens and the retina.^[4] Composed primarily of water (99%), it also contains collagen fibers, hyaluronic acid, hyalocytes, inorganic salts, and lipids.^[5] The average protein concentration in healthy VH is approximately 0.5 mg/mL, mainly comprising albumin (60-70%), globulins, coagulation proteins, complement factors, and low-molecular-weight proteins.^[6] The ciliary body and posterior segment are in a state of constant fluid exchange by diffusion, ultrafiltration, and active transport of aqueous fluid into the posterior segment.^[7] Proteins may accumulate in the vitreous by local secretion (e.g., glycoprotein), filtration from blood (e.g., albumin), or diffusion from the surrounding tissues.^[8] Given the close proximity of vitreous fluid to the inner retina, various vitreoretinal diseases lead to changes in specific vitreous proteins, particularly when the blood-retinal barrier is compromised.^[9] Consequently, surgical vitrectomy and vitreous biopsies are commonly performed to obtain valuable human VH samples for analysis. Such samples allow indirect exploration of the events occurring in the retina for clinical research since direct access to the retina for histopathological examination is not feasible.

This research paper highlights the role of vitreous fluid as a tool for investigating the mediators of diabetic retinopathy, with a primary focus on molecules associated with inflammatory changes in the retina and vitreous. Specifically, we examine Interleukin-6 (IL-6), C-Reactive Protein (CRP), and Lactate Dehydrogenase (LDH). Elevated levels of IL-6 contribute to excessive production of Vascular Endothelial Growth Factor (VEGF), thereby promoting enhanced angiogenesis and increased vascular permeability, both of which are pathological characteristics of inflammatory reactions.^[10] CRP possesses both pro-inflammatory and anti-inflammatory properties, influencing tissue damage and inflammation depending on the context. Persistent elevation of CRP levels is observed in chronic inflammatory conditions.^[11,12] whereas, LDH plays a crucial role in the process of converting pyruvate into lactate through oxidation. Altered lactate levels reflect changes in glucose metabolism rates or pyruvate levels.^[17]

METHODS

A prospective hospital based cross-sectional study was carried out in the Department of Ophthalmology, G.S.V.M Medical College and LLR Hospital, Kanpur, Uttar Pradesh. A total of 50 patients diagnosed of diabetic retinopathy were selected fulfilling the inclusion criteria (patients diagnosed of Type-2 diabetes mellitus with diabetic retinopathy, patients willing to participate for above study) and exclusion criteria (patients not willing to participate or ready for follow-up, with uncontrolled diabetes, not willing for vitreous tap, any other ocular disease, diagnosed of any other retinal or vitreous pathologies except Diabetic Retinopathy). Patients were selected after taking written and informed consent. Detailed history taking with regards to chief complaints, duration of disease,

ongoing and previous treatment taken, associated ocular morbidities.

After the patients are selected BCVA of selected patients was done using ETDRS chart, slit lamp examination, amsler grid test (using amsler chart), Intra ocular pressure (using applanation tonometer), Indirect Ophthalmoscopic examination (using Indirect Ophthalmoscope and 20D lens) and OCT was done.

Finally, the vitreous tap was performed in the operation theatre under all aseptic precautions. The subject eye was anaesthetised by eye drop Proparacaine 0.5%. Betadine 10% solution and eye drop moxifloxacin 0.5% is used to ensure asepsis. Next with the help of castroviejo calliper the desired spot 3.00 mm in aphakic, 3.50 mm in pseudophakic and 4.00 mm in phakic patients from the limbus, was marked. Then the tap was taken from the precise spot, directing the needle toward the center of the vitreous cavity. If liquid vitreous was not easily obtained, the procedure was aborted because forced aspiration of formed vitreous may induced vitreoretinal traction and predispose to retinal tear formation, rational detachment, or vitreous haemorrhage, all of which may seriously complicate the management of an eye with diabetic retinopathy. After vitreous tapping, intravitreal Anti-VEGF was given through same needle, just by exchanging tuberculin syringe loaded with Anti-VEGF. Eye drop moxifloxacin 0.5% was put to prevent infection and eye was patched. The patch was removed after 4-6 hours and patients were advised to put eye drop moxifloxacin 0.5% qid for 1 week to prevent infection. Patient was called for follow up on next day, 3rd day and at 1 month.

INFORMED CONSENT

Informed consent was obtained from all individuals participants in the study.

ETHICAL APPROVAL

All procedures performed in the study were in accordance with the ethical standards of the institution (Ref no.EC/384/Dec2022,dated-10-12-2022)

CTRI REG. NO – CTRI/2023/03/050341

RESULTS

The mean age of the patients enrolled in our study was 58.52 years. Among the participants, the majority (44%) belonged to the 6th decade of life, followed by 36% in the age group of 61-70 years. The 40-50 years category accounted for 18% of the patients, while the age group of 81-90 years comprised only 2% of the total. Furthermore, rural

areas had a higher prevalence of diabetic retinopathy, with 56% of patients originating from these regions, compared to 44% from urban areas.

It is worth noting that a significant proportion of patients (40%) had a history of diabetes mellitus for a duration of 11-15 years. Additionally, 28% of the participants had diabetes for 16-20 years, 20% for 6-10 years, 10% for 0-5 years, and 2% for 26-30 years.

Among 50 patients under study, 26 patients were of NPDR and 24 of PDR. 13 patients of NPDR and 5 patients of PDR were having HbA1c Level between 5.0-6.0, 11 patients of NPDR and 9 patients of PDR were having HbA1c Level between 6.0-7.0, 2 patients of NPDR and 5 patients of PDR were having HbA1c

TABLE - 1: LEVEL OF IL-6 IN VITREOUS TAP OF NPDR AND PDR PATIENTS:

RANGE (pg/dl)	NUMBER OF PATIENTS	
	NPDR	PDR
0-10	7	0
11-20	5	3
21-30	5	1
31-40	2	3
41-50	4	2
>50	3	15
TOTAL	26	24

Mean of IL-6 in NPDR patients was 23.59 ± 19.02 whereas in PDR patients was 58.91 ± 26.50 (Table 1, Chart 1). On applying t- test, T=5.44 P value = 0.000001738(exact value)

P value <0.00001 Result is highly significant.

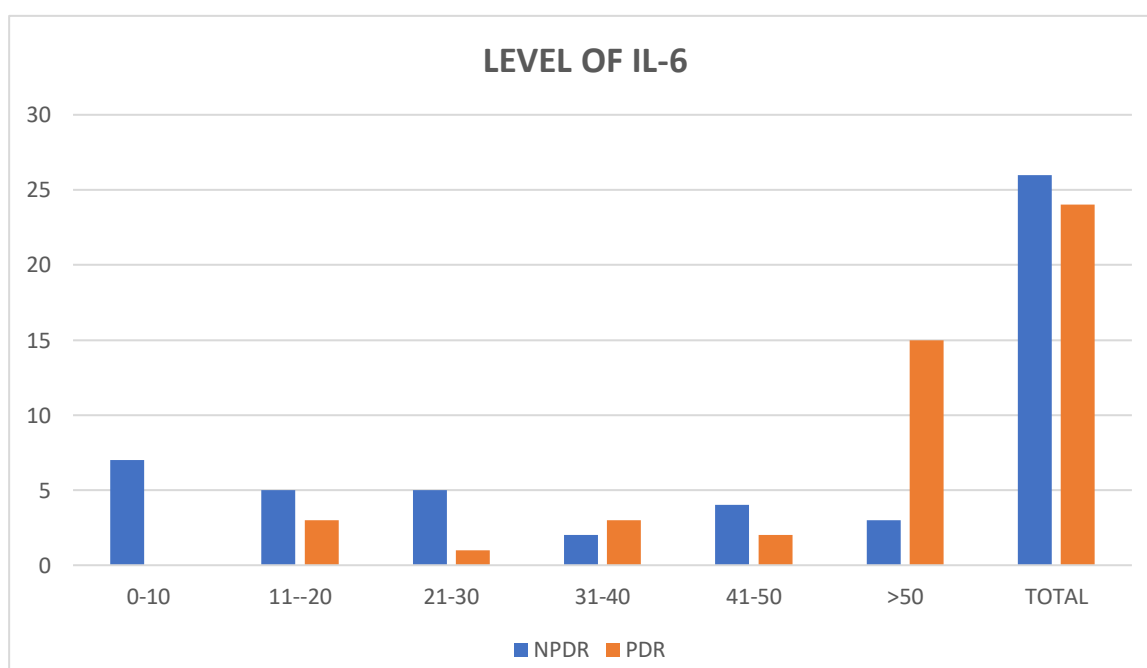
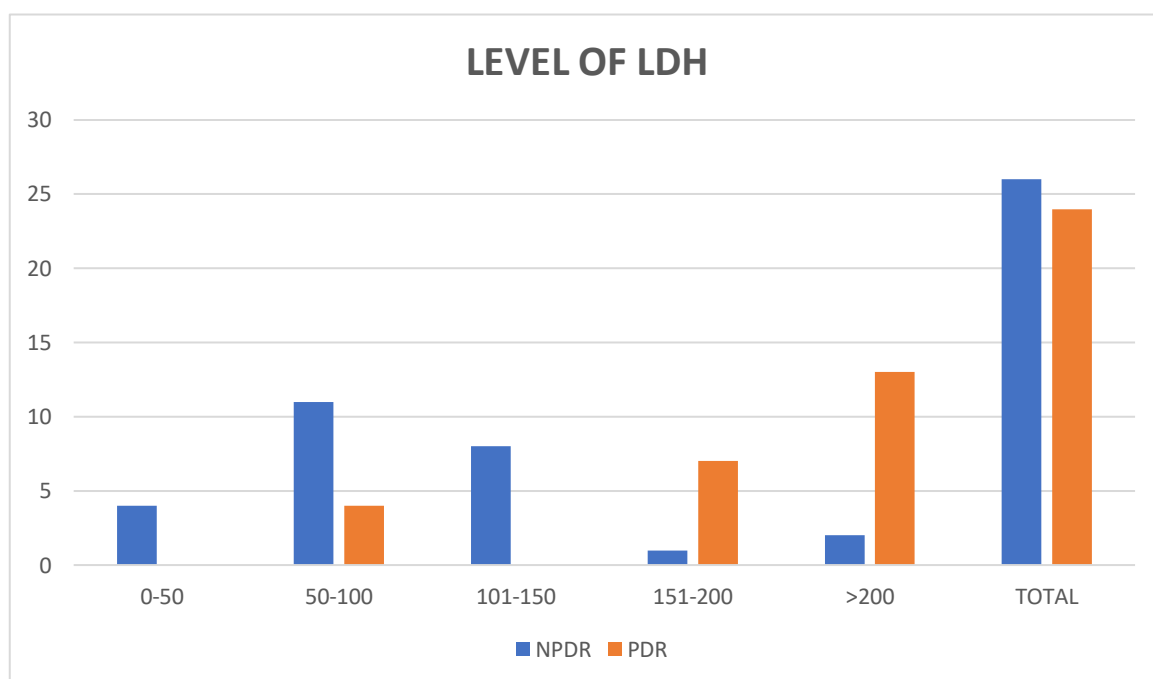


TABLE – 2: LEVEL OF LDH IN VITREOUS TAP OF NPDR AND PDR PATIENTS:

RANGE (U/L)	NUMBER OF PATIENTS	
	NPDR	PDR
0-50	4	0
50-100	11	4
101-150	8	0
151-200	1	7
>200	2	13
TOTAL	26	24

Mean of LDH in NPDR patients was 99.46 ± 51.17 whereas in PDR patients was 202.5 ± 63.93 (Table-2, Chart-2). On applying t- test, $T = 6.3154$ P value = 0.0000001 P value <0.0001 Result is highly significant.



Level between 7.0-8.0 whereas zero patients of NPDR and 5 patients of PDR were having HbA1c Level between 8.0-9.0.

As part of adverse events, only 6% were having conjunctival chemosis and 4% patients presented with subconjunctival haemorrhage after vitreous tap during intravitreal Anti-VEGF injection.

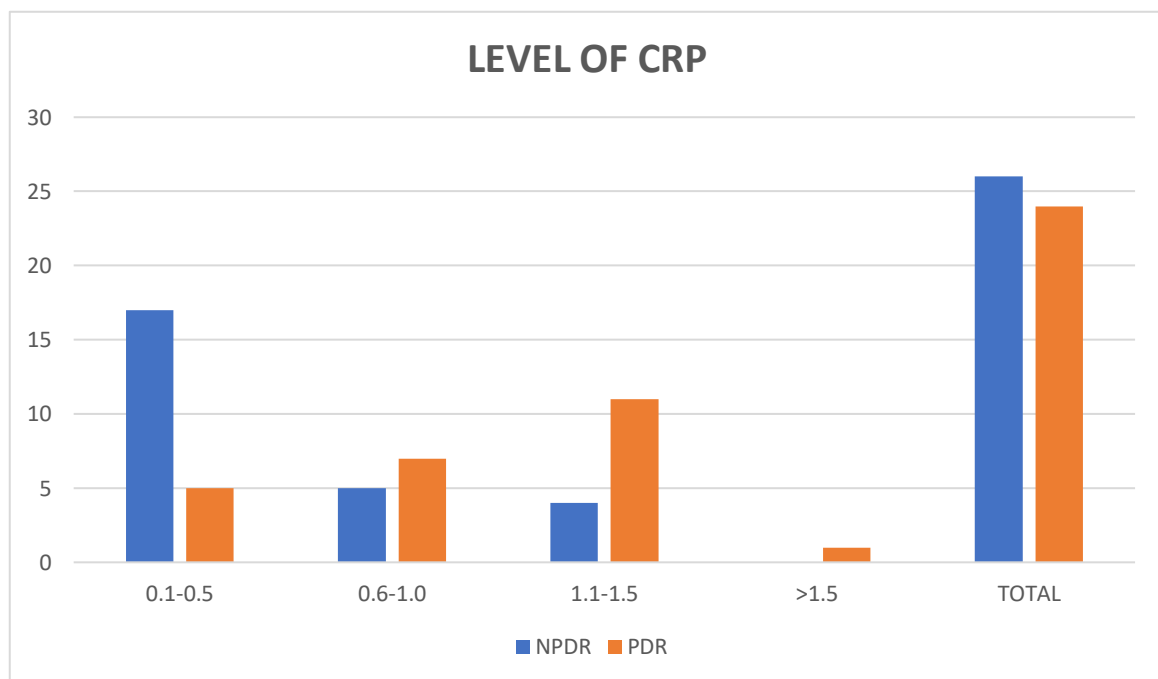
Level of inflammatory biomarkers found to be raised in both NPDR and PDR with Mean of IL-6 in

NPDR patients was 23.59 ± 19.02 whereas in PDR patients was 58.91 ± 26.50 (p-value <0.0001) (Table-1, Graph-1). Mean of LDH in NPDR patients was 99.46 ± 51.17 whereas in PDR patients was 202.5 ± 63.93 (p-value < 0.0000001) (Table-2, Graph-2). Mean of CRP in NPDR patients was 0.49 ± 0.30 whereas in PDR patients was 0.93 ± 0.33 (p-value < 0.000001) (Table-3, Graph-3).

TABLE – 3: LEVEL OF CRP IN VITREOUS TAP OF NPDR AND PDR PATIENTS:

RANGE (mg/dl)	NUMBER OF PATIENTS	
	NPDR	PDR
0.1-0.5	17	5
0.6-1.0	5	7
1.1-1.5	4	11
>1.5	0	1
TOTAL	26	24

Mean of CRP in NPDR patients was 0.49 ± 0.30 whereas in PDR patients was 0.93 ± 0.33 (Table-3, Chart-3). On applying t- test, T= 4.93 P value = 0.0000009928 (exact value) P value <0.0001 Result is highly significant.



DISCUSSION

In the present study, we included 50 patients diagnosed of Diabetic Retinopathy, out of 50 patients, 58% were male and 42% were female. Similar to the study conducted by Glen Y et al 2015^[18] which also suggesting a higher prevalence of diabetic retinopathy among males.

The mean age of the patients enrolled in our study was 58.52 years, which was in line with other study conducted by Svenja Deuchler et al 2021^[19] in which mean age of treated patients was 60.92 (range, 43–78) years.

Among 50 patients under study, 26 patients were of NPDR and 24 of PDR. Majority (40%) of the patients of NPDR and PDR group were in the range 6.0-7.0, followed by 36% patients had HbA1c level <6, 14% were in 7.0-8.0 and only 10 % had HbA1c level between 8.0-9.0. Similar results were found by M Mjwara et al 2021^[20] in their study and concluded that high HbA1c level was correlated to high number of NPDR and PDR eyes.

In our study, mean of IL-6 in NPDR patients was 23.59 ± 19.02 whereas in PDR patients was 58.91 ± 26.50 (p-value <0.0001) (Table-1, Graph-1) showing highly significant results with around 2-fold raised

levels in PDR patients. Similar results were found in a study conducted by Svenja Deuchler et al 2021^[19] which compares the mean IL-6 levels in PDR and NPDR groups and show the levels of IL-6 (133.3 vs. 15.8 pg/ml; $p = 0.085$) were numerically higher in DME patients with PDR than those with NPDR. V V Chernykh et al (2015)^[21] also found that levels of IL-6 along with IL-4, IL-8, VEGF, PEDF were significantly higher in PDR patients.

Joseph D Boss et al (2017)^[22] also found similar results in 50 vitreous samples that vitreous neurotrophins levels of all DR patients were significantly higher than those of non diabetic controls. Similarly, the levels of inflammatory mediators IL-1 β ($P < 0.0001$), IL-6 ($P = 0.0005$), IL-8 ($P < 0.0001$), and TNF- α ($P < 0.0001$) were also higher in eyes with DR.

Mojca Urbancic et al (2020)^[23] also found similar results in their study of 37 patients with PDR (37 eyes) that required vitrectomy. And found that levels of MCP-1, VEGF, IL-6, IL-8 were significantly higher in the vitreous of patients with PDR in comparison with vitreous levels in the control group.

In our study Mean of LDH in NPDR patients was 99.46 ± 51.17 whereas in PDR patients was 202.5 ± 63.93 (p -value < 0.0000001) (Table-2, Graph-2) which is statistically highly significant similar to study conducted by Chiara Bianca Maria Platania et al 2017^[24] in which in-vitro model of early diabetic retinopathy, human retinal pericytes were exposed to high glucose (25mM, 48h) that caused a significant ($p < 0.05$) release of LDH.

In our study Mean of CRP in NPDR patients was 0.49 ± 0.30 whereas in PDR patients was 0.93 ± 0.33 (p -value < 0.0000001) (Table-3, Graph-3) showing highly significant results. Increased CRP levels were noted by M Nalini et al 2017^[25] in their study in patients with diabetic retinopathy.

Dean F. Loporchio et al (2021)^[26] also found similar results related to CRP levels in patients with proliferative diabetic retinopathy (PDR) to that of patients without PDR. Levels of interleukin-8 (IL-8), IL-15, IL-16, vascular endothelial growth factor (VEGF), VEGFD, c-reactive protein (CRP), serum amyloid-A (SAA), and intracellular adhesion molecule-1 (ICAM1) were significantly increased in the vitreous of PDR patients compared to non-PDR patients ($p < 0.05$).

Our study highlights the safety of vitreous tap during intravitreal Anti-VEGF injection, with minimal adverse events as supported by a similar study conducted by Aires Lobo et al 2003^[27] on 53 patients revealed that vitreous aspiration needle tap would seem to be a safe clinical procedure.

Hamzah Khalaf et al (2017)^[28] also showed the safety of vitreous needle aspiration sampling in their study of 40 patients with a total number of 118 vitreous aspirations.

CONCLUSION

In our study, we conclude that levels of inflammatory biomarkers (IL-6, CRP, LDH) are significantly raised in PDR patients than NPDR patients. PDR being a severe form of diabetic retinopathy, statistically significant raised levels of inflammatory markers (IL-6, CRP, LDH) showing a direct correlation of inflammatory markers with disease progression. Targeting the specific inflammatory markers medically at NPDR level may slow or decelerate the progression of NPDR to PDR and prevent vision threatening complications of PDR. In PDR patients combined intravitreal anti VEGF and steroids/immune-modulators may halt the progression of PDR, by decreasing the ongoing inflammatory process and may hasten the recovery process.

REFERENCES

1. Mohan V, Shah SN, Joshi SR, Seshiah V, Sahay BK, Banerjee S, et al. Current status of management, control, complications and psychosocial aspects of patients with diabetes in India: Results from the DiabCare India 2011 Study. *Indian J Endocrinol Metab.* 2014 May ; 18 (3) : 370–8.
2. Rajaci E, Jalali MT, Shahrabi S, Asnafi AA, Pezeshki SMS. HLAS in Autoimmune Diseases: Dependable Diagnostic Biomarkers? *Curr Rheumatol Rev.* 2019; 15 (4): 269-276.
3. Romero-Aroca P, Baget-Bernaldiz M, Pareja-Rios A, Lopez-Galvez M, Navarro-Gil R, Verges R. Diabetic Macular Edema Pathophysiology : Vasogenic versus Inflammatory. *J Diabetes Res.* 2016; 2016: 2156273. Doi: 10.1155/2016/2156273. Epub 2016 Sep 28. PMID: 27761468; PMCID: PMC5059543.
4. P. N. Bishop, "Structural macromolecules and supram-olecular organisation of the vitreous gel," *Progress in Retinal and Eye Research*, vol. 19, no. 3, pp. 323-344, 2000.
5. J. Sebag, "The vitreous," in *Adlers Physiology of the Eye*, W. Hart, Ed., pp. 268-347, Mosby St. Louis, 1992.
6. J. N. Ulrich, M. Spannagl, A. Kampik, and A. Gandorfer, Components of the fibrinolytic system in the vitreous body in patients with vitreoretinal disorders," *Clinical and Experimental Ophthalmology*, vol. 36, no. 5, pp. 431-436, 2008.
7. P. N. Bishop, M. Takanosu, M. Le Goff, and R. Mayne, The role of the posterior ciliary body in the biosynthesis of vitreous humour," *Eye*, vol. 16, no. 4, pp. 454-460, 2002.
8. C. W. Wu, J. L. Sauter, P. K. Johnson, C. D. Chen, and T. W. Olsen, "Identification and localization of major (00592-015 soluble vitreous proteins in human ocular 1832 tissue," *American Journal of Ophthalmology*, vol. 137, no. 4, pp. 655-661, 2004.
9. T. Shitama, H. Hayashi, S. Noge et al., "Proteome profiling of vitreoretinal diseases by cluster analysis," *Proteomics-Clinical Applications*, vol. 2, no. 9, pp. 1265-1280, 2008.
10. Tanaka T, Narazaki M, Kishimoto T. IL-6 in inflammation, immunity, and disease. *Cold Spring Harb Perspect Biol.* 2014 Sep 4 ; 6 (10) : a016295. doi: 10.1101/cshperspect.a016295. PMID: 25190079; PMCID: PMC4176007.
11. Jungen MJ, Ter Meulen BC, van Osch T, Weinstein HC, Ostelo RWJG. Inflammatory biomarkers in patients with sciatica: a systematic review. *BMC Musculoskelet Disord.* 2019 Apr 09;20(1):156. [PMC free article] [PubMed].
12. Kramer NE, Cosgrove VE, Dunlap K, Subramaniapillai M, McIntyre RS, Suppes T. A clinical model for identifying an inflammatory phenotype in mood disorders. *J Psychiatr Res.* 2019 Jun;113:148-158. [PubMed].
13. Joshi SP, et al. Comparison between salivary and serum lactatedehydrogenase levels in patients with oral leukoplakia, and oral squamous cell carcinoma - A pilot study. *International Journal of Oral and Maxillofacial Pathology.* 2012;3(4):7–12. [Google Scholar]
14. Acharya S, Kale J, Hallikeri K, Desai A. Prognostic Significance of Preoperative Salivary and Serum Lactate Dehydrogenase in Oral Squamous Cell Carcinoma Patients. *Acta Scientific Cancer Biology.* 2018;2(8):2–10. [Google Scholar]

15. Sivaramkrishnan M, et al. Evaluation of lactate dehydrogenase enzyme activity in saliva and serum of oral submucous fibrosis patients. *Journal of Oral Pathology Medicine*. 2015;44(6):449–452. [PubMed] [Google Scholar]
16. Alkhatib AJ, Alrakaf NASM. Lactate Dehydrogenase: Physiological Roles and Clinical Implications. *Am J Biomed Sci and Res*. 2019;3(5) doi: 10.34297/AJBSR.2019.03.000705. [Cross Ref] [Google Scholar]
17. Garcia Alvarez M, Marik P, Bellomo R (2014) Sepsis-associated hyperlactatemia. *Crit Care* 18(5): 503.
18. Ozawa GY, Bearnse MA Jr, Adams AJ. Male-female differences in diabetic retinopathy? *Curr Eye Res*. 2015 Feb;40(2):234–46. Doi: 10.3109/02713683.2014.958500. Epub 2014 Dec 29. PMID: 25545999.
19. Deuchler S, Schubert R, Singh P, Chedid A, Brui N, Kenikstul N, Kohnen T, Ackermann H, Koch F. Vitreous expression of cytokines and growth factors in patients with diabetic retinopathy-An investigation of their expression based on clinical diabetic retinopathy grade. *PLoS One*. 2021 May 19;16(5):e0248439. Doi: 10.1371/journal.pone.0248439. PMID: 34010297; PMCID: PMC8133486.
20. Mjwara M, Khan M, Kruse CH, Sibanda W, Connolly C. Significance of HbA1c levels in diabetic retinopathy extremes in South Africa. *S Afr Med J*. 2021 Sep 2;111(9):886–890. PMID: 34949254.
21. Chernykh VV, Varvarinsky EV, Smirnov EV, Chernykh DV, Trunov AN. Proliferative and inflammatory factors in the vitreous of patients with proliferative diabetic retinopathy. *Indian J Ophthalmol*. 2015 Jan ; 63 (1) : 33–6. Doi: 10.4103/0301-4738.151464. PMID: 25686060; PMCID: PMC4363955.
22. Boss JD, Singh PK, Pandya HK, Tosi J, Kim C, Tewari A, Juzych MS, Abrams GW, Kumar A. Assessment of Neurotrophins and Inflammatory Mediators in Vitreous of Patients With Diabetic Retinopathy. *Invest Ophthalmol Vis Sci*. 2017 Oct 1;58(12):5594–5603. Doi: 10.1167/iovs.17-21973. PMID: 29084332; PMCID: PMC5667399.
23. Urbancic M, Korosec P, Flezar M, Globocnik Petrovič M. Diabetic retinopathy as a subclinical inflammation: Vitreous and serum cytokine analysis. *Zdrav Vestn*. 2020;89(5–6):243–54.
24. Platania CBM, Giurdanella G, Di Paola L, Leggio GM, Drago F, Salomone S, Bucolo C. P2X7 receptor antagonism: Implications in diabetic retinopathy. *Biochem Pharmacol*. 2017 Aug 15;138:130–139. Doi: 10.1016/j.bcp.2017.05.001. Epub 2017 May 4. PMID: 28479300.
25. Nalini M, Raghavulu BV, Annapurna A, Avinash P, Chandi V, Swathi N, Wasim. Correlation of various serum biomarkers with the severity of diabetic retinopathy. *Diabetes Metab Syndr*. 2017 Nov;11 Suppl 1:S451–S454. Doi: 10.1016/j.dsx.2017.03.034. Epub 2017 Apr 8. PMID: 28420575.
26. Loporchio, D.F.; Tam, E.K.; Cho, J.; Chung, J.; Jun, G.R.; Xia, W.; Fiorello, M.G.; Siegel, N.H.; Ness, S.; Stein, T.D.; et al. Cytokine Levels in Human Vitreous in Proliferative Diabetic Retinopathy. *Cells* 2021, 10, 1069. <https://doi.org/10.3390/cells10051069>.
27. Lobo A, Lightman S. Vitreous aspiration needle tap in the diagnosis of intraocular inflammation. *Ophthalmology*. 2003 Mar;110(3):595–9. Doi: 10.1016/S0161-6420(02)01895-X. PMID: 12623828.

28. Hamzah Khalaf; Victor H Gonzalez : Case Series Report of Safety of Serial Vitreous Needle Taps in Patients with Proliferative Diabetic Retinopathy (PDR) and Central Retinal Vein Occlusion (CRVO). June 2017 ; Volume 58, Issue 8.



This work licensed under Creative Commons Attribution